



REVISTA DE GASTROENTEROLOGÍA DE MÉXICO

www.elsevier.es/rgmx



CLINICAL IMAGE IN GASTROENTEROLOGY

Unusual hemostatic endoclip retention over a period of 5 years

Retención inusual de un endoclip hemostático por un periodo de 5 años

V. Arantes^{a,*}, J. Aliaga Ramos^b

^a Unidad de Endoscopia, Instituto de Gastroenterología Alfa, Escuela de Medicina, Universidad Federal de Minas Gerais, Hospital Mater Dei Contorno, Belo Horizonte, Brazil

^b Facultad de Medicina, Universidad Peruana Cayetano Heredia, Unidad de Endoscopia Digestiva de la Clínica de San Pablo, Surco, Lima, Departamento de Gastroenterología, Hospital "Jose Agurto Tello", Lima, Peru

A 76-year-old man underwent esophagogastroduodenoscopy (EGD) in 2017, as surveillance after gastric endoscopic submucosal dissection (ESD). Examination revealed a post-ESD scar and a 4 mm sessile polyp in the gastric fundus, removed through cold forceps biopsy (Fig. 1). Persistent bleeding at the polypectomy site was successfully controlled by the placement of 2 endoclips (Resolution Clip, Boston Scientific Co., Marlborough, Massachusetts, USA) (Fig. 2). Histology study of the resected polyp identified hyperplasia. The following year a gastric metachronous lesion was detected and a second ESD was successfully performed. Endoscopic control in 2019 showed post-ESD scars and the continued presence of the 2 hemostatic endoclips at the polypectomy site (Fig. 3). Another surveillance EGD was recently carried out and revealed one hemostatic endoclip still in place, with no significant alterations of the surrounding mucosa (Fig. 4). Only one previous report has described a 2-year retention of a hemostatic clip in the duodenum, secondary to gastrointestinal bleeding.¹ Most authors agree that the type

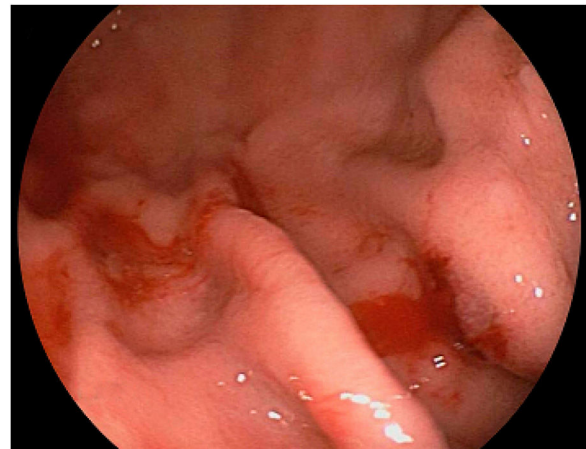


Figure 1 Persistent bleeding after polypectomy.

of endoclip used is a determining factor for its prolonged retention at the application site.^{2,3} The incidental detection of retained endoclips does not modify their original indication.^{3,4}

☆ Please cite this article as: Arantes V, Aliaga Ramos J. Retención inusual de un endoclip hemostático por un periodo de 5 años. Rev Gastroenterol Méx. 2023;88:175–176.

* Corresponding author. Unidad de Endoscopia, Instituto de Gastroenterología Alfa, Escuela de Medicina, Universidad Federal de Minas Gerais, Hospital Mater Dei Contorno, Belo Horizonte, 30310690, Brazil. Phone: +55 31 3339-9000 (line 8).

E-mail address: arantesvitor@ufmg.br (V. Arantes).

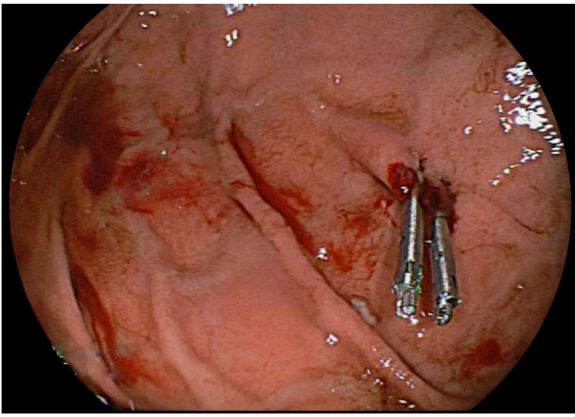


Figure 2 Mechanical hemostasis of the bleeding, with the placement of 2 endoclips.

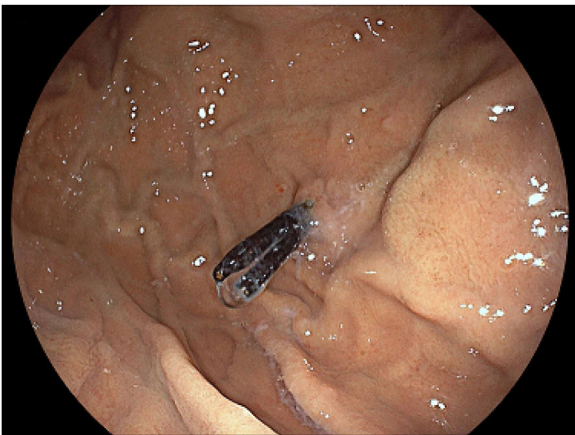


Figure 3 Endoscopic follow-up 2 years after endoclip placement.

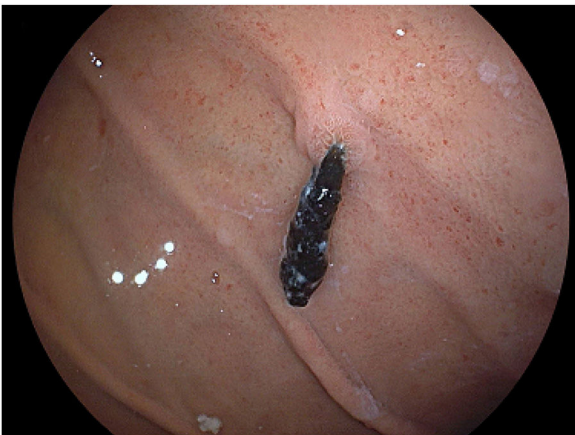

Figure 4 Endoscopic follow-up 5 years after endoclip placement.

Financial disclosure

The authors declare that no funding was received from any public or private institution for the preparation of this study.

Conflict of interest

The authors declare that they have no conflict of interest related to this publication.

References

1. Ooi BP, Hassan MR, Kiew KK, et al. Case report of a hemostatic clip being retained for 2 years after deployment. *Gastrointest Endosc.* 2010;72:1315–6, <http://dx.doi.org/10.1016/j.gie.2010.03.1053>.
2. Shin EJ, Ko CW, Magno P, et al. Comparative study of endoscopic clips: duration of attachment at the site of clip application. *Gastrointest Endosc.* 2007;66:757–61, <http://dx.doi.org/10.1016/j.gie.2007.03.1049>.
3. Swellengrebel HAM, Marijnen CAM, Vincent A, et al. Evaluating long-term attachment of two different endoclips in the human gastrointestinal tract. *World J Gastrointest Endosc.* 2010;2:344–8, <http://dx.doi.org/10.4253/wjge.v2.i10.344>.
4. Ponugoti PL, Rex DK. Clip retention rates and rates of residual polyp at the base of retained clips on colorectal EMR sites. *Gastrointest Endosc.* 2017;85:530–4, <http://dx.doi.org/10.1016/j.gie.2016.07.037>.

Ethical considerations

The authors declare that this article contains no personal information that can identify the patient described, making the patient's informed consent unnecessary for the publication of this article.