



REVISTA DE GASTROENTEROLOGÍA DE MÉXICO

www.elsevier.es/rgmx



SCIENTIFIC LETTER

Cholecystocutaneous fistula, an uncommon pathology today



Fístula colecistocutánea, una patología poco común en la actualidad

First described by Thilesus in 1670¹, cholecystocutaneous fistula (CCF) is the connection of the gallbladder to the external environment, through a rupture in the layers of the abdominal wall, forming a fistulous tract². In the nineteenth century (1890), Courvoisier reported 169 cases from a case series of 499 perforations of the gallbladder. The last case series was published in 1949; the authors were Henry and Orr and they reported 37 cases³.

We present herein the case of a 73-year-old woman that had no past medical history of chronic-degenerative diseases or surgical interventions. Two weeks prior to hospital admission, she presented with an increase in volume in the left flank, and one week before, local hyperemia and hyperthermia. A fetid green exudate then began to seep out of the umbilicus, accompanied by moderate abdominal pain, for which the patient sought medical attention. Her vital signs at admission were blood pressure, 110/60 mmHg; heart rate, 105 beats per minute; respiratory rate, 16 breaths per minute; and temperature, 37.8 °C. Physical examination revealed no hernial defect, only the presence of a fetid, apparently intestinal exudate, draining from the umbilicus. An approximately 8 × 10 cm region of the wall of the left flank was hyperthermal and hyperemic, indurated, and severely painful when palpated. Rebound tenderness was present and peristalsis was reduced (Fig. 1). Laboratory work-up reported hemoglobin, 10 g/dl; leukocytes, 3.8 cells/mm³; neutrophils, 98%, with toxic granulations; platelets, 150,000; sodium, 129 mmol/l; potassium, 2.9 mmol/l; chloride, 115 mmol/l; glucose, 76 mg/dl; and creatinine, 2.1 mg/dl. Due to the signs of peritoneal irritation, associated with a systemic inflammatory response (tachycardia, leukopenia, and neutrophilia), together with the lack of an imaging study, emergency surgery was decided upon, with the suspicion of abdominal sepsis and a probable enterocutaneous fistula. An exploratory laparotomy was performed that produced the following findings: a 300 ml abscess in the abdominal wall, connected to the abdominal cavity; destruction of the aponeurosis, with a 12 × 15

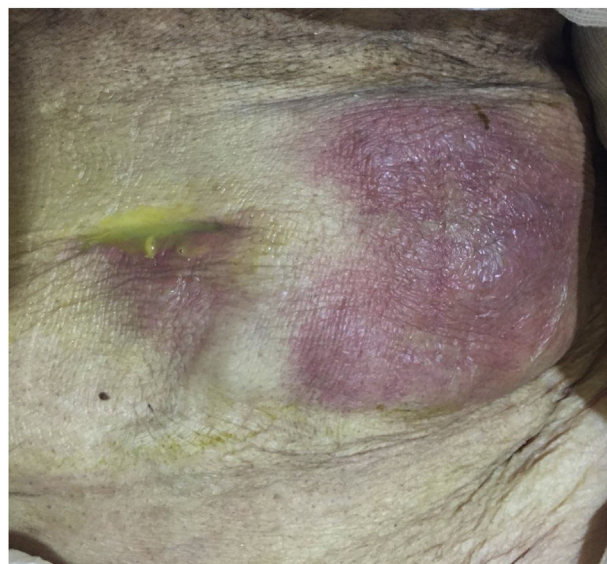

Figure 1 Anterior wall of the abdomen, with the presence of exudate.

cm defect; and the presence of a cholecystocutaneous fistula at the level of the umbilicus (Fig. 2). Fistulectomy was performed and no stones were observed (Fig. 3). The aponeurosis was closed, employing tension, and the use of prosthetic material was ruled out due to the type of intervention. A carbapenem was administered during the postoperative period, and given the patient's favorable progression, she was released.

CCFs account for 8 to 26.5% of cholecystoenteric fistulas and are the second most common fistulas, after cholecystoduodenal fistula. According to Costi et al., the female/male ratio is 2.47:1. The mean age of patients at diagnosis is 68.9 years (range 37–90), and more specifically, 70.8 years in Western articles and 62.1 years in Asian reports⁴.

Gallbladder neoplasia, anatomic anomalies, and injuries related to surgical procedures stand out among the causes of CCF, albeit the majority are associated with gallstones⁵. Polyarteritis nodosa, corticosteroid therapy, typhoid fever, and trauma have been described as predisposing factors^{3,6}.

The pathophysiology begins with the increase in the intraluminal pressure of the gallbladder, secondary to obstruction caused by stones, impeding the blood flow and lymphatic drainage, resulting in wall necrosis and perforation. It can be an acute event that leads to peritonitis and abscesses surrounding the gallbladder, or to a chronic process that conditions the formation of internal and external fistulas, mainly from the fundus of the gallbladder¹. Perforation of the gallbladder generally occurs at the level of the fundus⁶.

* Please cite this article as: Ballesteros-Suárez E, Navarro-Tovar F, Díaz-Barrientos CZ, Marín-Pardo EI, Hernández-Pérez E. Fístula colecistocutánea, una patología poco común en la actualidad. *Rev Gastroenterol Méx.* 2023;88:177–179.

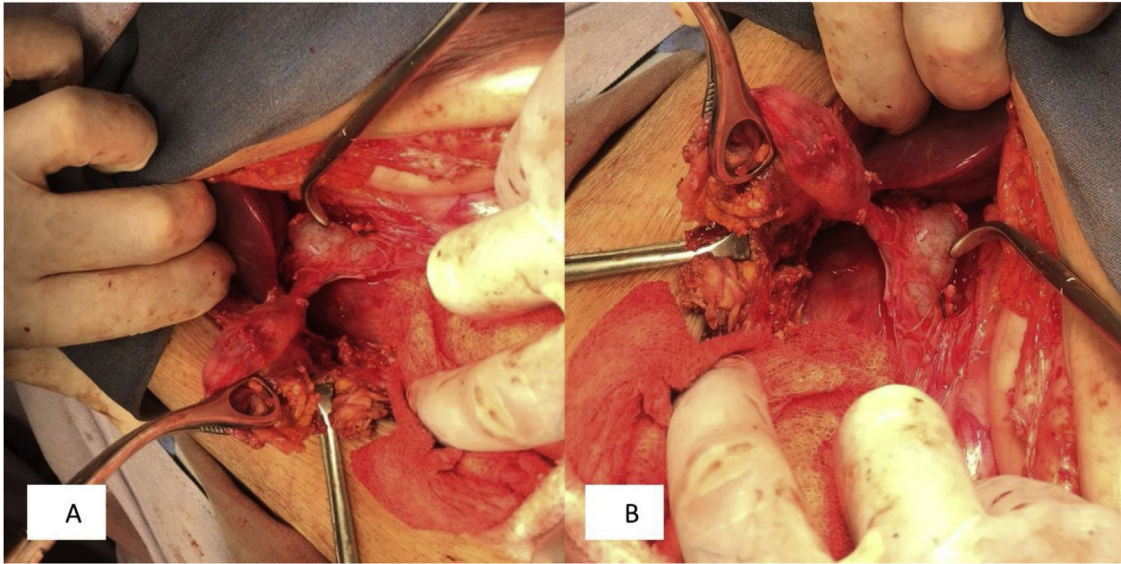


Figure 2 A, B) Gallbladder-abdominal wall fistulous tract.

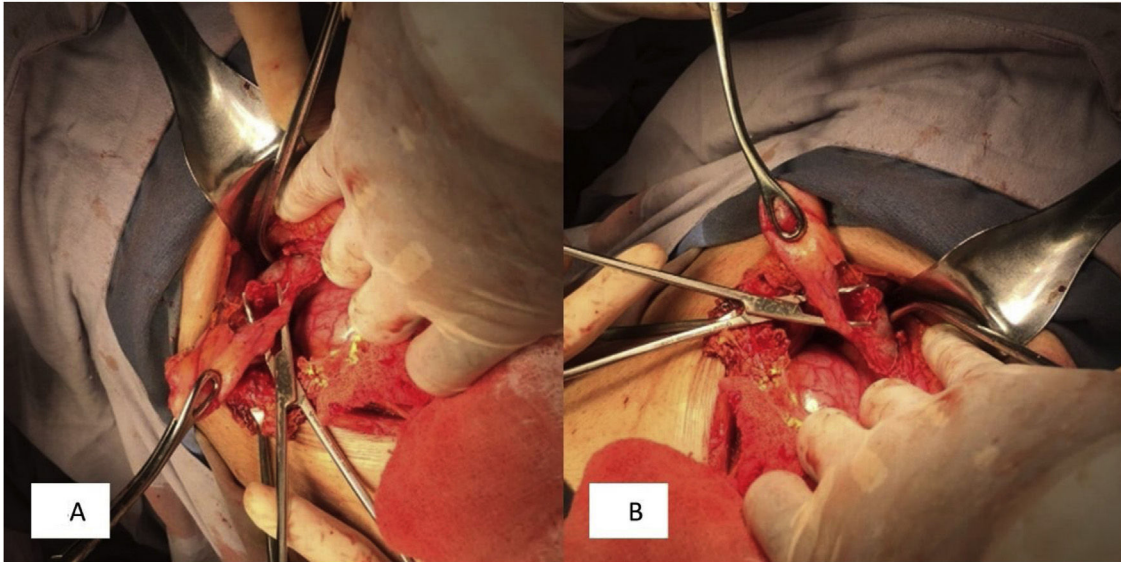


Figure 3 A, B) Images showing the cystic duct (approximately 5 mm), bile duct dilation, and the absence of bile duct stones.

Biliary fistulas are classified into two groups: internal and external. The latter connect to any part of the anterior surface of the trunk. Seventy-five percent of internal fistulas connect to the duodenum, 15% to the colon, and 10% to the jejunum, stomach, or bronchi².

A fistula tends to become evident upon the discharge of bile or stones through the abdominal wall. The most common site of the opening is the upper abdominal quadrant and the right flank or the umbilical orifice. Sites can also include the left lateral costal margin, the right iliac fossa, the right groin, or the right gluteus. Its presentation can also be more insidious and its diagnosis more difficult, when only pus is drained or subcutaneous abscesses are formed^{6,7}. Abscesses are recurrent, usually with no other accompanying symptomatology, and even cases of acalculous fistula

have been described. When an abscess persists after having been drained multiple times, the diagnosis of fistula should be suggested, and in cases of unexplained suppuration or wall cellulitis, a routine imaging study should be performed³.

Abdominal ultrasound or tomography are useful for making the diagnosis, but fistulography is the confirmatory imaging study, enabling visualization of the tract³. Cholecystocutaneous fistula can be treated with two different strategies. The first entails a two-step approach: percutaneous drainage and antibiotic therapy, followed by cholecystectomy. The second directly involves the performance of cholecystectomy, through laparotomy, with *en bloc* excision of the aponeurotic sheath, skin, and fistula orifice. The two-step approach is reserved for patients with sep-

sis and poor general condition⁸, such as the patient in our report.

Ethical considerations

The authors declare that all ethical responsibilities in relation to data protection, the right to privacy, and informed consent were met.

Authorization by the institutional ethics committee was not required, given that no patient anonymity norms were unmet or violated and no experimental procedures putting the patient's integrity at risk were performed.

The authors declare that this article contains no personal data that could identify the patient.

Financial disclosure

No specific grants were received from public sector agencies, the business sector, or non-profit organizations in relation to this study.

Conflict of interest

The authors declare that there is no conflict of interest.

References

- Hernández-Avendaño V, Jiménez-López M. Fístula colecistocutánea: reporte de un caso y revisión de la literatura. *Rev Mex Cir Endoscop.* 2014;15:39–42.
- Guardado-Bermúdez F, Aguilar-Jaimes A, Ardisson-Zamora FJ, et al. Fístula colecistocutánea espontánea. *Cir Cir.* 2015;83:61–4, <http://dx.doi.org/10.1016/j.circir.2015.04.026>.

- Tallón-Aguilar L, López-Porras M, Molina-García D, et al. Cholecystocutaneous fistula: a rare complication of gallstones. *Gastroenterol Hepatol.* 2010;33:553–4, <http://dx.doi.org/10.1016/j.gastrohep.2010.02.012>.
- Costi R, Randone B, Violi V, et al. Cholecystocolonic fistula: facts and myths. A review of the 231 published cases. *J Hepatobiliary Pancreat Surg.* 2009;16:8–18, <http://dx.doi.org/10.1007/s00534-008-0014-1>.
- Santos-Seoane SM, Díaz-Fernández V, Arenas-García V. Fístula colecistocutánea. *Rev Esp Enferm Dig.* 2019;111:407–8, <http://dx.doi.org/10.17235/reed.2019.5882/2018>.
- Moreno BA, De la Fuente BM, Rodríguez CE, et al. Fístula colecistocutánea espontánea. *Rev Chil Cir.* 2014;67:413–5, <http://dx.doi.org/10.4067/S0718-40262015000400011>.
- Pezzilli R, Barakat B, Corinaldesi R, et al. Spontaneous cholecystocutaneous fistula. *Case Rep Gastroenterol.* 2010;4:356–60, <http://dx.doi.org/10.1159/000320687>.
- Rinzivillo NMA, Danna R, Leanza V, et al. Case Report: Spontaneous cholecystocutaneous fistula, a rare cholethiasis complication. *F1000Research.* 2017;6:1768, <http://dx.doi.org/10.12688/f1000research.12235.1>.

E. Ballesteros-Suárez^{a,*}, F. Navarro-Tovar^a,
C.Z. Díaz-Barrientos^b, E.I. Marín-Pardo^a,
E. Hernández-Pérez^a

^a *Servicio de Cirugía General, Hospital Universitario de Puebla, Puebla, Puebla, Mexico*

^b *Servicio de Coloproctología, Hospital Universitario de Puebla, Puebla, Puebla, Mexico*

*Corresponding author at: Avenida Cue Merlo 425 Interior 3, Colonia San Baltazar Campeche, C.P. 72550, Tel.: 2223539033.

E-mail address: ebs02@outlook.com (E. Ballesteros-Suárez).

Pancreatocopy-guided electrohydraulic lithotripsy for the management of main pancreatic duct obstruction due to a stone



Litotripsia electrohidráulica guiada por pancreatoscopia para el manejo de obstrucción del conducto pancreático principal por lito

Chronic pancreatitis is a progressive fibroinflammatory disease that, in addition to causing exocrine pancreatic insufficiency and endocrine alterations, is painful in the majority of cases.

Current symptomatic chronic pancreatitis management is scaled. It begins with lifestyle changes and analgesics and can end in the need for surgery. Endoscopic treat-

ment is a less invasive option than surgery and is considered first-line therapy, together with extracorporeal shock wave lithotripsy (ESWL), when there is main pancreatic duct obstruction at the level of the head or body of the pancreas due to a stone.^{1,2}

A 58-year-old man presented with chronic pancreatitis, experiencing persistent abdominal pain and recurring symptoms of acute pancreatitis for several years. He had a surgical history of laparoscopic cholecystectomy and no personal history of significant alcohol consumption. In his most recent episode of acute pancreatitis, a stone that appeared to be located in the intrapancreatic common bile duct was reported on an abdominal computed tomography scan. The patient was referred to our hospital to undergo endoscopic retrograde cholangiopancreatography (ERCP). The approach was complemented with magnetic resonance cholangiography, revealing that the stone was actually located in the main pancreatic duct at the level of the head of the pancreas, with pancreatic duct dilation (Fig. 1A and B). The decision was made to extract the pancreatic stone through conventional ERCP. After cannulating the pancreatic duct, a 0.035'' guidewire was advanced until coming up against a 7mm radio-opaque stone that did not allow further advancement, preventing the completion of the procedure as it had been planned (Fig. 1C). Sphincterotomy was carried out and a temporary 5 Fr pan-

☆ Please cite this article as: Valdez-Hernández P, Romero-Vallejo F, Molina-López JF, Olavide-Aguilar R, Fonseca-Rodríguez I. Litotripsia electrohidráulica guiada por pancreatoscopia para el manejo de obstrucción del conducto pancreático principal por lito. *Rev Gastroenterol Méx.* 2023;88:179–181.