

Financial disclosure

No financial support was received in relation to this article.

Conflict of interest

The authors declare that there is no conflict of interest.

References

1. Kentley J, Ooi JL, Potter J, et al. Intestinal tuberculosis: a diagnostic challenge. *Trop Med Int Health*. 2017;22:994–9, <http://dx.doi.org/10.1111/tmi.12908>.
2. Ruiz Cuesta P, Iglesias Flores E, García Sánchez V, et al. Tuberculosis intestinal y diagnóstico diferencial con enfermedad de Crohn. *RAPD Online*. 2012;35:269–72.
3. Ma JY, Tong JL, Ran ZH. Intestinal tuberculosis and Crohn's disease: challenging differential diagnosis. *J Dig Dis*. 2016;17:155–61, <http://dx.doi.org/10.1111/1751-2980.12324>.
4. Limsrivilai J, Shreiner A, Pongpaibul A, et al. Meta-analytic Bayesian model for differentiating intestinal tuberculosis from Crohn's disease. *Am J Gastroenterol*. 2017;112:415–27, <http://dx.doi.org/10.1038/ajg.2016.529>.
5. Giouleme O, Paschos P, Katsarons M, et al. Intestinal tuberculosis: a diagnostic challenge – case report and review of the literature. *Eur J Gastroenterol Hepatol*. 2012;23:1074–7, <http://dx.doi.org/10.1097/MEG.0b013e32834a9470>.
6. Merino Gallego E, Gallardo Sánchez F, Gallego Rojo F. Tuberculosis intestinal: importancia y dificultad del diagnóstico diferencial con enfermedad de Crohn. *Rev Esp Enferm Dig*. 2018;110:650–7, <http://dx.doi.org/10.17235/reed.2018.5184/2017>.
7. Mosquera Klineger GA, Ucroz Benavides A. Enfermedad de Crohn vs tuberculosis intestinal: un diagnóstico diferencial desafiante.

Revisión de tema. *Rev Colomb Gastroenterol*. 2018;33:423–30, <http://dx.doi.org/10.22516/25007440.172>.

8. Kedia S, Das P, Madhusudhan KS, et al. Differentiating Crohn's disease from intestinal tuberculosis. *World J Gastroenterol*. 2019;25:418–32, <http://dx.doi.org/10.3748/wjg.v25.i4.418>.
9. Mosli MH, Zou G, Garg SK, et al. C-reactive protein, fecal calprotectin, and stool lactoferrin for detection of endoscopic activity in symptomatic inflammatory bowel disease patients: a systematic review and meta-analysis. *Am J Gastroenterol*. 2015;110:802–19, <http://dx.doi.org/10.1038/ajg.2015.120>.
10. Ricciuto A, Griffiths AM. Clinical value of fecal calprotectin. *Crit Rev Clin Lab Sci*. 2019;56:307–20, <http://dx.doi.org/10.1080/10408363.2019.1619159>.
11. Ayling RM, Kok K. Chapter six - fecal calprotectin. *Adv Clin Chem*. 2018;87:161–90, <http://dx.doi.org/10.1016/bs.acc.2018.07.005>.

L.M. Aguirre-Padilla*, B.E. Madrid-Villanueva, M.E. Ugarte-Olvera, J. Alonso-Soto

Servicio de Gastroenterología y Endoscopia Digestiva, Hospital Clínico Quirúrgico Hermanos Ameijeiras, Universidad de Ciencias Médicas de La Habana, La Habana, Cuba

*Corresponding author at: Hospital Hermanos Clínico Quirúrgico Hermanos Ameijeiras. Departamento de Gastroenterología y Endoscopia Digestiva. Centro Habana, La Habana, Cuba, 10200. Tel.: + 5356080535

E-mail address: luismarcelo931028@gmail.com (L.M. Aguirre-Padilla).

2255-534X/ © 2021 Asociación Mexicana de Gastroenterología. Published by Masson Doyma México S.A. This is an open access article under the CC BY-NC-ND license (<http://creativecommons.org/licenses/by-nc-nd/4.0/>).

Ampullary adenocarcinoma in a patient with portal annular pancreas: Relevance of the surgical approach in the Whipple procedure[☆]



Adenocarcinoma ampular en un paciente con páncreas anular portal: relevancia del abordaje quirúrgico en el procedimiento de Whipple

A 41-year-old woman with an unremarkable medical history presented with abdominal pain, associated with jaundice and weight loss of 10 kg in one month, as well as elevated transaminase levels.

In the initial approach, endoscopic retrograde cholangiopancreatography was performed, with transpapillary biliary drainage via a stent. An ampullary lesion was identified

and the histopathologic report stated moderately differentiated adenocarcinoma. The patient was referred to our hospital. A computed tomography scan revealed a dilated common bile duct secondary to an ampullary lesion. The main pancreatic duct (MPD) was situated in a retroportal position and pancreatic tissue encircled the portal vein and the splenoportal confluence (Fig. 1).

The patient underwent a pylorus-preserving Whipple procedure (pancreaticoduodenectomy), with a 2-step resection of the pancreas. First, the anteportal portion was divided, revealing an accessory pancreatic duct, with a 5 mm diameter. The retroportal portion was then divided, revealing the MPD, with a 1.5 mm diameter. Gross pathologic examination identified a tumor measuring 1.6 × 1.6 cm, located on the ampulla of Vater, 1/10 positive lymph nodes (peripancreatic), and tumor-free surgical margins. Microscopic examination showed a moderately differentiated intestinal-type adenocarcinoma. The patient's postoperative course was uneventful, and she received 8 cycles of capecitabine/gemcitabine adjuvant chemotherapy. The patient is currently in active follow-up with the oncology service and the latest control imaging study revealed local recurrence of the disease, 27 months from the initial diagnosis.

Annular pancreas is a rare condition characterized by circumferential involvement of another anatomical struc-

[☆] Please cite this article as: Castro E, Sánchez-Morales GE, Hernández-Acevedo JD, Sánchez García-Ramos E, Chan C. Adenocarcinoma ampular en un paciente con páncreas anular portal: relevancia del abordaje quirúrgico en el procedimiento de Whipple. *Revista de Gastroenterología de México*. 2022;87:116–118.

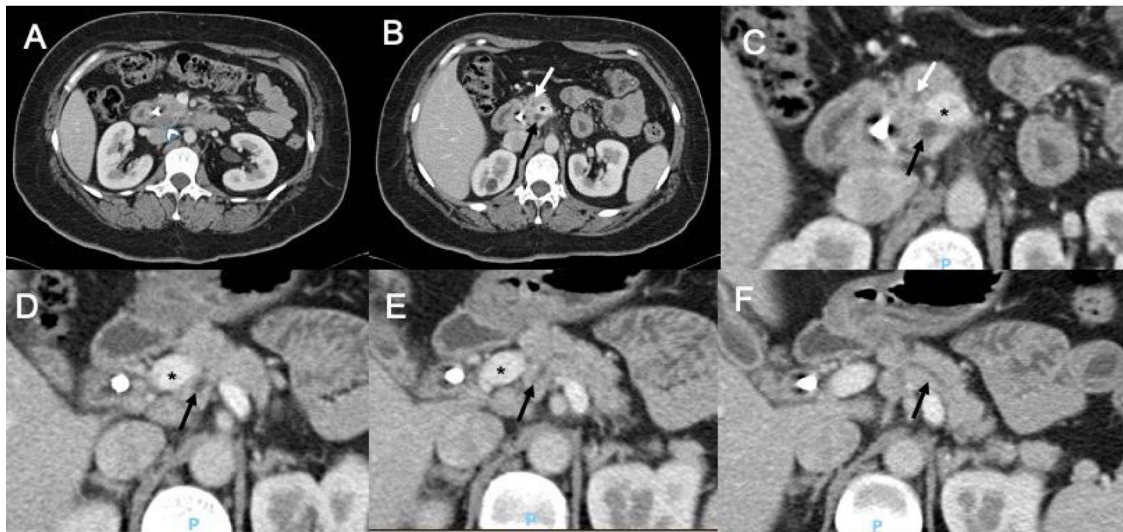


Figure 1 Abdominal computed tomography scan showing: A) a hypodense lesion on the head of the pancreas (arrowhead) and B-F) pancreas divisum with a retroportal main pancreatic duct (black arrow) and an anteportal accessory pancreatic duct (white arrow). Portal vein (*).

ture. Portal annular pancreas (PAP) is the rarest congenital anomaly of the pancreas, with an incidence around 1.14%.^{1,2} This anatomic variant is the result of an aberrant fusion of the uncinete process of the pancreas, with complete portal encasement and/or splenoportal confluence.^{3,4} PAP is classified depending on the running patterns of the MPD: type 1 (retroportal MPD), type 2 (type 1 associated with pancreas divisum), and type 3 (anteportal MPD); or in accordance with its relation to the portal confluence: suprasplenic, infraplenic, and mixed types, respectively.¹⁻⁵

In Mexico, there are no publications related to PAP. Ours is the first report in Latin America on pancreaticoduodenectomy in a patient with the anomaly. PAP is usually asymptomatic and tends to be an incidental finding. However, its preoperative diagnosis is crucial for identifying the precise topography of the MPD and planning the surgical strategy well, thus reducing the risk of the main complication: postoperative pancreatic fistula.

Care must be taken in the parenchymal resection, so that there is a lower risk of postoperative pancreatic fistula, as well as better short-term and long-term results.⁶ In cases of PAP, preoperative and intraoperative confirmation of pancreatic ductal system integrity is of the utmost importance, to avoid technical problems at the time of pancreaticoduodenectomy.

Ethical considerations

Informed consent for receiving treatment was requested from the patient. The authors obtained informed consent from the patient for the publication of data/images and the present scientific letter was approved by the institutional ethics committee.

Financial disclosure

No financial support was received in relation to this article.

Conflict of interest

The authors declare that there is no conflict of interest.

References

1. Karasaki H, Mizukami Y, Ishizaki A, et al. Portal annular pancreas, a notable pancreatic malformation: frequency, morphology, and implications for pancreatic surgery. *Surgery*. 2009;146:515–8, <http://dx.doi.org/10.1016/j.surg.2009.03.018>.
2. Matsumoto I, Shinzeki M, Fukumoto T, et al. An extremely rare portal annular pancreas for pancreaticoduodenectomy with a special note on the pancreatic duct management in the dorsal pancreas. *Surgery*. 2013;153:434–6, <http://dx.doi.org/10.1016/j.surg.2011.08.017>.
3. Marjanovic G, Obermaier R, Benz S, et al. Complete pancreatic encasement of the portal vein—surgical implications of an extremely rare anomaly. *Langenbecks Arch Surg*. 2007;392:489–91, <http://dx.doi.org/10.1007/s00423-006-0123-8>.
4. Foo FJ, Gill U, Guthrie JA, et al. Ampullary carcinoma associated with an annular pancreas. *JOP*. 2007;8:50–4.
5. Joseph P, Raju RS, Vyas FL, et al. Portal annular pancreas. A rare variant and a new classification. *JOP*. 2010;11:453–5.
6. Yamaguchi H, Kimura Y, Nagayama M, et al. Central pancreatectomy in portal annular pancreas for metastatic renal cell carcinoma: a case report. *World J Surg Oncol*. 2019;30:76, <http://dx.doi.org/10.1186/s12957-019-1622-8>.

E. Castro^a, G.E. Sánchez-Morales^a, J.D. Hernández-Acevedo^a, E. Sánchez García-Ramos^a, C. Chan^{b,*}

^a *Departamento de Cirugía General, Instituto Nacional de Ciencias Médicas y Nutrición Salvador Zubirán, Mexico City, Mexico*

^b *Departamento de Cirugía Hepatopancreatobiliar, Instituto Nacional de Ciencias Médicas y Nutrición Salvador Zubirán, Mexico City, Mexico*

*Corresponding author at: Departamento de Cirugía General, Servicio de Cirugía Hepatopancreatobiliar, Instituto Nacional de Ciencias Médicas y Nutrición Salvador Zubirán, Av. Vasco de Quiroga, 15 col. sección XVI. Del. C.P. 14080, Mexico City, Mexico. Tel.: 01 (52) 54 87 09 00 ext. 2133. E-mail address: chancarlos@me.com (C. Chan).

2255-534X/ © 2021 Asociación Mexicana de Gastroenterología. Published by Masson Doyma México S.A. This is an open access article under the CC BY-NC-ND license (<http://creativecommons.org/licenses/by-nc-nd/4.0/>).

Acute diverticulitis in the terminal ileum: A rare case to have in mind[☆]



Diverticulitis aguda en íleon terminal: un caso raro a tener en cuenta

A 62-year-old woman, with an unremarkable past history, arrived at the emergency department, presenting with abdominal pain at the level of the right hemiabdomen, fever of 39.5°C, likely due to a bacterial infection, together with nausea and unaltered bowel habit. Laboratory tests reported a C-reactive protein value of 91 mg/l (reference value 0–5), procalcitonin level of 6.3 ng/mL (reference value 0.02–0.5), and a leukocyte count of 16,500 IU/l, with 94% neutrophils. Given the clinical and laboratory data, abdominal computed tomography (CT) scanning was ordered that identified a diverticular formation in the terminal ileum, with inflammatory changes, suggestive of diverti-

With the exception of Meckel's diverticulum, the presence of diverticula in the ileum is a rare entity. Its incidence in the general population varies from 0.3 to 2.3%, according to the most recent case series¹. Its pathogenesis is attributed to herniation of the mucosa and submucosa, through the intestinal muscle layer, due to local increases in intraluminal pressure and smooth muscle anomalies. The majority of cases (60%) tend to be asymptomatic. When symptoms are present (40%), only a small portion of those cases (10%) develop severe complications. The main complication is diverticulitis, but bleeding and intestinal obstruction can also manifest². The delayed diagnosis of diverticulitis can result in intestinal perforation. Endoscopic access to the ileum and its visualization through conventional imaging techniques are difficult, making the diagnosis of diverticula at that site challenging, and they are often detected intraoperatively^{2,3}. There is no clear consensus on their therapeutic management. Even though intestinal resection with primary anastomosis appears to be the

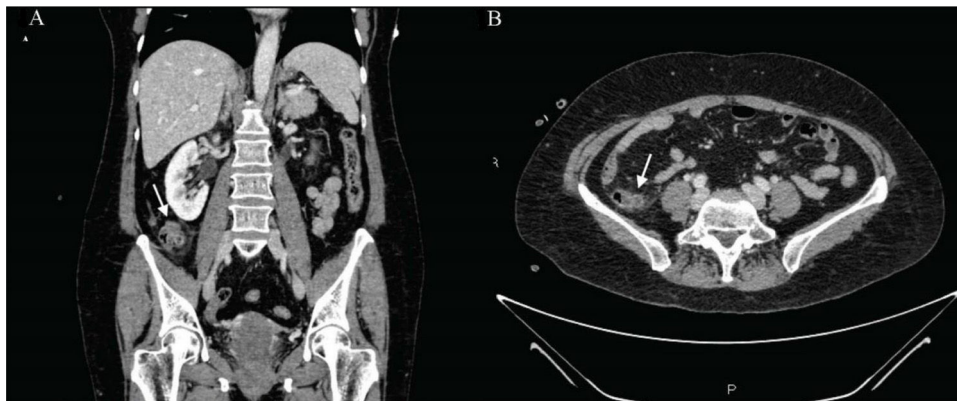

Figure 1 (A) and (B) Coronal and axial views of abdominal CT scans with intravenous contrast medium, showing a diverticular formation of approximately 11 mm in the terminal ileum, with inflammatory changes in the adjacent fat and adjacent layers of free fluid, suggestive of diverticulitis.

culitis (Fig. 1A and B). Blood cultures obtained upon the patient's arrival revealed the growth of *Eggerthella lenta*. She was hospitalized and intravenous antibiotic therapy was started with amoxicillin/clavulanic acid, resulting in good progression. The patient was discharged, with outpatient follow-up. Once the acute episode was resolved, colonoscopy with ileoscopy was ordered, confirming the presence of said diverticula at the level of the terminal ileum (Fig. 2).

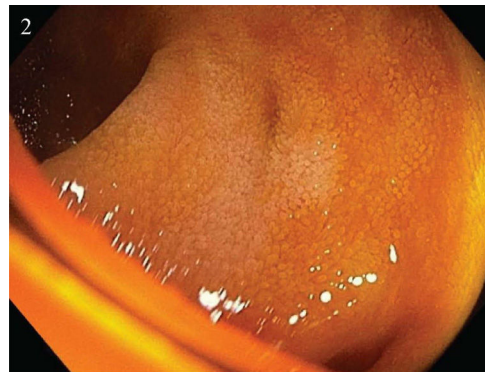


Figure 2 The terminal ileum with 2 small diverticula, with no signs of complications.

[☆] Please cite this article as: García-Márquez J, García-Verdejo FJ, Caballero-Mateos AM. Diverticulitis aguda en íleon terminal: un caso raro a tener en cuenta. Rev Gastroenterol Méx. 2022;87:118–119.