



REVISTA DE GASTROENTEROLOGÍA DE MÉXICO

www.elsevier.es/rgmx



CLINICAL IMAGE IN GASTROENTEROLOGY

Filiform polyposis. A rare complication in a patient with inflammatory bowel disease[☆]

Poliposis filiforme. Complicación infrecuente en un paciente con enfermedad inflamatoria intestinal

A. Ruiz de la Hermosa^{a,*}, A. Burdaspal-Moratilla^b, G. Paseiro-Crespo^a

^a Cirugía General y del Aparato Digestivo, Hospital Universitario Infanta Leonor, Madrid, Spain

^b Anatomía Patológica, Hospital Universitario Infanta Leonor, Madrid, Spain

Filiform polyposis (FP) is a rare entity that is associated with inflammatory bowel disease. It is present in 10-20% of cases, especially in patients with ulcerative colitis, and is characterized by the presence of soft and elongated “worm-

like” or “finger-like” polyps that can measure up to 9 cm in length and form mucosal bridges. A 44-year-old man with ulcerative colitis had abdominal pain of 15-day progression and leukocytosis. The computed tomography (CT) scan

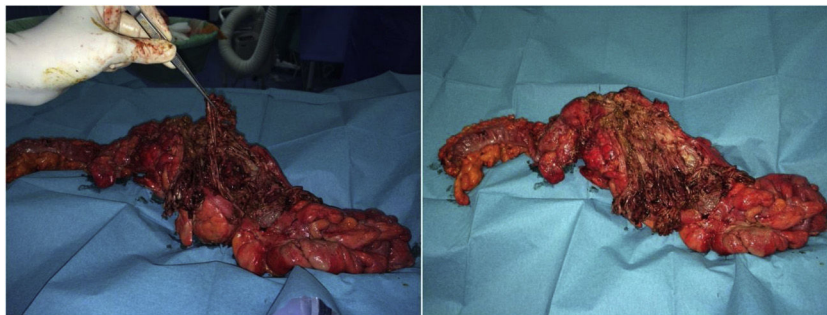


Figure 1 Surgical specimen, after the sigmoidectomy and Hartmann procedure, with multiple worm-like polyps.

[☆] Please cite this article as: Ruiz de la Hermosa A, Burdaspal-Moratilla A, Paseiro-Crespo G. Poliposis filiforme. Complicación infrecuente en un paciente con enfermedad inflamatoria intestinal. Rev Gastroenterol Méx. 2022;87:103–105.

* Corresponding author. Servicio de Cirugía General y del Aparato Digestivo, Hospital Universitario Infanta Leonor, Calle Gran Vía del Este 80, 28031 Madrid, Spain. Tel.: +34 91 191 80 00.

E-mail address: aliciaruiz9@hotmail.com
(A. Ruiz de la Hermosa).

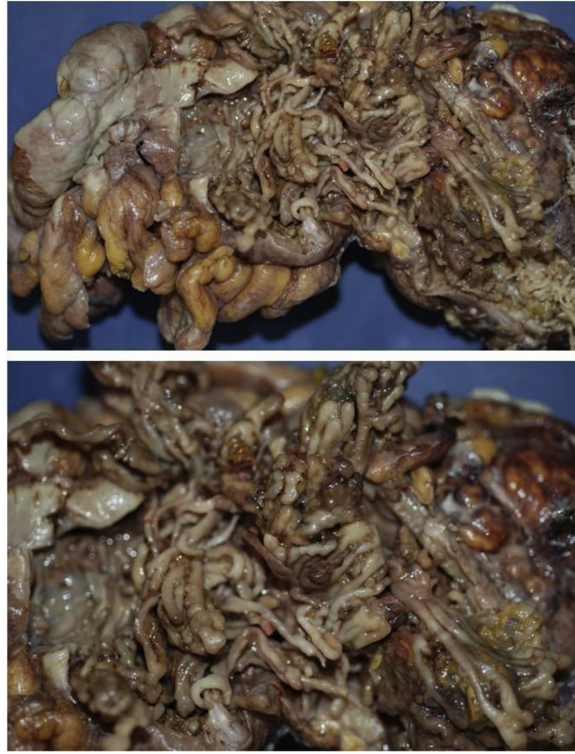

Figure 2 Surgical specimen fixed in formol.

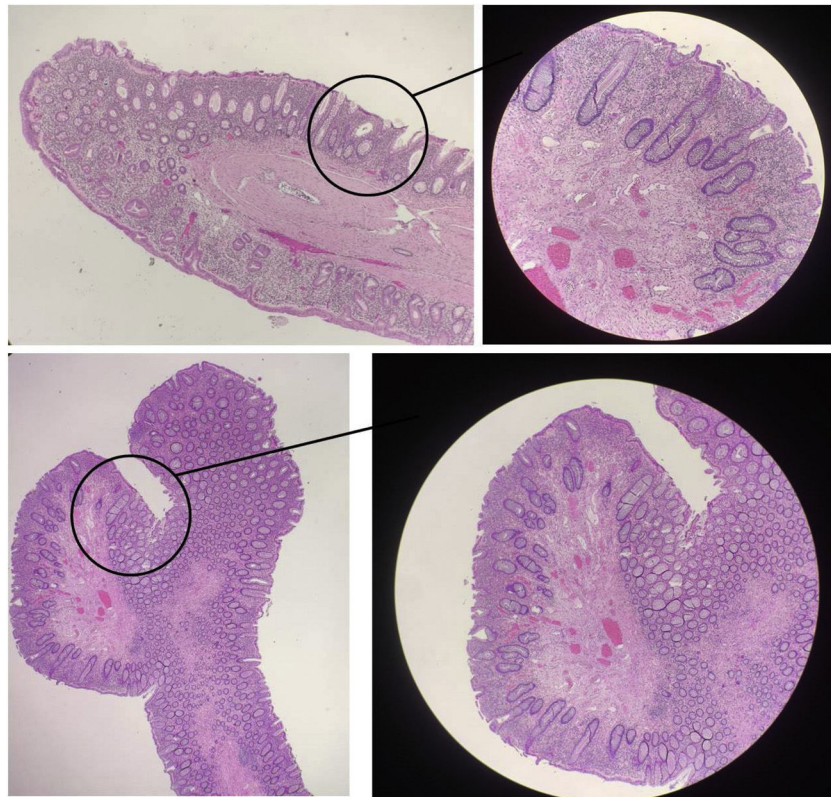


Figure 3 Pathologic image showing digitiform, polypoid formations, no dysplasia, and the presence of acute and chronic inflammation, with focal abscesses, consistent with perforation.

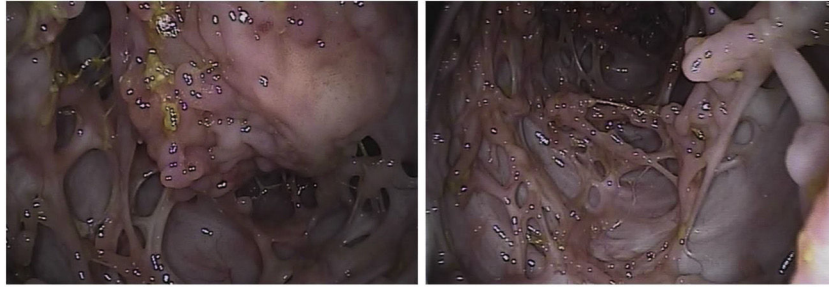


Figure 4 Endoscopic image, showing polyps forming mucosal bridges.

identified thickening of the descending colon, with atypical morphology, and intraluminal content associated with pneumoperitoneum. Emergency sigmoidectomy and Hartmann procedure were performed, revealing purulent peritonitis secondary to the perforation of a large mass with an inflammatory aspect in the left colon (Fig. 1). The pathology study showed countless digitiform polypoid formations that fused together, constituting bridges (Fig. 2). Histologic study reported acute and chronic inflammation with abscesses, consistent with perforation, and no dysplasia (Fig. 3). A later endoscopic examination showed the presence of filiform polyposis in the remaining colon (Fig. 4). Filiform polyposis should be suspected in patients with ulcerative colitis that present with clinical obstruction. Perforation is a rare complication.

Ethical disclosures

The authors declare that no experiments were conducted on humans or animals for the present article, that they have

followed the protocols of their work center on the publication of patient data, and that they have preserved patient confidentiality and anonymity at all times. Informed consent was requested from the patient for the surgical intervention and it included a section stating the possibility of utilizing images or clinical data for scientific purposes.

Financial disclosure

No financial support was received in relation to this article.

Conflict of interest

The authors declare that there is no conflict of interest.