

*Corresponding author at: Departamento de Cirugía General, Servicio de Cirugía Hepatopancreatobiliar, Instituto Nacional de Ciencias Médicas y Nutrición Salvador Zubirán, Av. Vasco de Quiroga, 15 col. sección XVI. Del. C.P. 14080, Mexico City, Mexico. Tel.: 01 (52) 54 87 09 00 ext. 2133. E-mail address: chancarlos@me.com (C. Chan).

2255-534X/ © 2021 Asociación Mexicana de Gastroenterología. Published by Masson Doyma México S.A. This is an open access article under the CC BY-NC-ND license (<http://creativecommons.org/licenses/by-nc-nd/4.0/>).

Acute diverticulitis in the terminal ileum: A rare case to have in mind[☆]



Diverticulitis aguda en íleon terminal: un caso raro a tener en cuenta

A 62-year-old woman, with an unremarkable past history, arrived at the emergency department, presenting with abdominal pain at the level of the right hemiabdomen, fever of 39.5°C, likely due to a bacterial infection, together with nausea and unaltered bowel habit. Laboratory tests reported a C-reactive protein value of 91 mg/l (reference value 0–5), procalcitonin level of 6.3 ng/mL (reference value 0.02–0.5), and a leukocyte count of 16,500 IU/l, with 94% neutrophils. Given the clinical and laboratory data, abdominal computed tomography (CT) scanning was ordered that identified a diverticular formation in the terminal ileum, with inflammatory changes, suggestive of diverti-

With the exception of Meckel's diverticulum, the presence of diverticula in the ileum is a rare entity. Its incidence in the general population varies from 0.3 to 2.3%, according to the most recent case series¹. Its pathogenesis is attributed to herniation of the mucosa and submucosa, through the intestinal muscle layer, due to local increases in intraluminal pressure and smooth muscle anomalies. The majority of cases (60%) tend to be asymptomatic. When symptoms are present (40%), only a small portion of those cases (10%) develop severe complications. The main complication is diverticulitis, but bleeding and intestinal obstruction can also manifest². The delayed diagnosis of diverticulitis can result in intestinal perforation. Endoscopic access to the ileum and its visualization through conventional imaging techniques are difficult, making the diagnosis of diverticula at that site challenging, and they are often detected intraoperatively^{2,3}. There is no clear consensus on their therapeutic management. Even though intestinal resection with primary anastomosis appears to be the

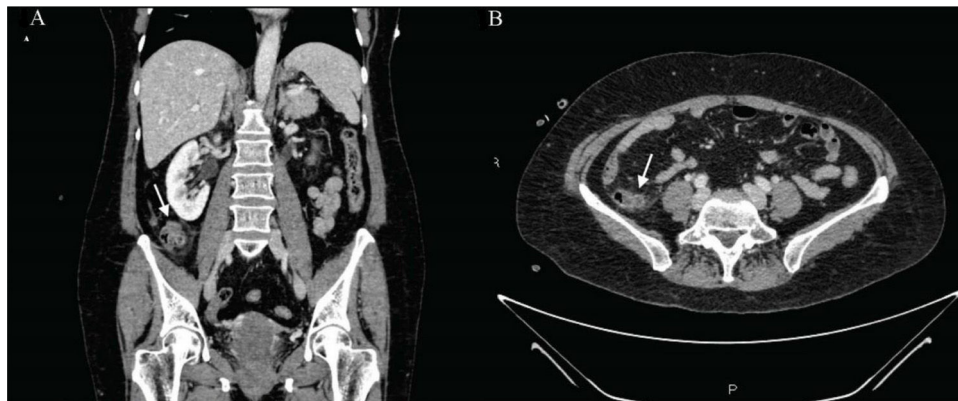


Figure 1 (A) and (B) Coronal and axial views of abdominal CT scans with intravenous contrast medium, showing a diverticular formation of approximately 11 mm in the terminal ileum, with inflammatory changes in the adjacent fat and adjacent layers of free fluid, suggestive of diverticulitis.

culitis (Fig. 1A and B). Blood cultures obtained upon the patient's arrival revealed the growth of *Eggerthella lenta*. She was hospitalized and intravenous antibiotic therapy was started with amoxicillin/clavulanic acid, resulting in good progression. The patient was discharged, with outpatient follow-up. Once the acute episode was resolved, colonoscopy with ileoscopy was ordered, confirming the presence of said diverticula at the level of the terminal ileum (Fig. 2).

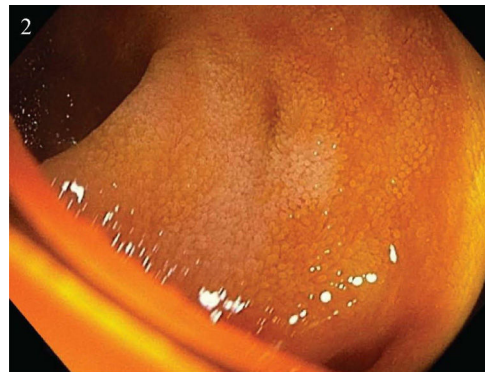


Figure 2 The terminal ileum with 2 small diverticula, with no signs of complications.

[☆] Please cite this article as: García-Márquez J, García-Verdejo FJ, Caballero-Mateos AM. Diverticulitis aguda en íleon terminal: un caso raro a tener en cuenta. Rev Gastroenterol Méx. 2022;87:118–119.

treatment of choice, conservative medical management with antibiotic therapy should be considered in mild cases^{3,4}.

Ethical considerations

The authors declare that the manuscript contains no personal information that can identify the patient, who signed a statement of informed consent for the performance of the studies. The corresponding author is in possession of said document. No experiments were conducted on animals or humans. The correct protocol was followed at all times, with the agreement of the patient and her family.

Financial disclosure

No financial support was received in relation to this article.

Conflict of interest

The authors declare that they have no conflict of interest.

References

- Saijo F, Sawada K, Nomura R, et al. Penetration and perforation of terminal ileum diverticulitis. *Case Rep Surg.* 2020, <http://dx.doi.org/10.1155/2020/7361389>.
 - Liu CY, Chang WH, Lin SC, et al. Analysis of clinical manifestations of symptomatic acquired jejunoileal diverticular disease. *World J Gastroenterol.* 2005;11:5557–60, <http://dx.doi.org/10.3748/wjg.v11.i35.5557>.
 - Kassir R, Boueil-bourlier A, Baccot S, et al. Jejuno-ileal diverticulitis: Etiopathogenicity, diagnosis and management. *Int J Surg Case Rep.* 2015;10:151–3, <http://dx.doi.org/10.1016/j.ijscr.2015.03.044>.
 - Ramistella AM, Brenna M, Fasolini F, et al. Jejuno-ileal diverticulitis: a disorder not to underestimate. *Int J Surg Case Rep.* 2019;58:81–4, <http://dx.doi.org/10.1016/j.ijscr.2019.04.015>.
- J. García-Márquez*, F.J. García-Verdejo,
A.M. Caballero-Mateos
- Unidad de Aparato Digestivo, Hospital Universitario San Cecilio, Granada, Spain*
- * Corresponding author at: Hospital Universitario San Cecilio, Avenida de la Investigación s/n, 18016, Granada, Spain. Tel.: 618242443.
E-mail address: joagarmar@hotmail.com
(J. García-Márquez).
- 2255-534X/ © 2021 Asociación Mexicana de Gastroenterología. Published by Masson Doyma México S.A. This is an open access article under the CC BY-NC-ND license (<http://creativecommons.org/licenses/by-nc-nd/4.0/>).

Arterial embolization for the control of lower gastrointestinal bleeding. Treatment or complication?☆



Embolización arterial para control de sangrado gastrointestinal bajo. ¿Tratamiento o complicación?

Ischemic colitis (IC) is the most common cause of intestinal ischemia (60-70%). Fulminant presentation occurs in less than 5% of all cases, but it is a life-threatening situation with a high mortality rate^{1,2}. The causes of IC have been classified as systemic or local, occlusive or non-occlusive, and iatrogenic or non-iatrogenic, with post-embolization IC standing out in the latter group³. We report herein a case of arterial post-embolization fulminant IC.

A middle-aged female patient, with a personal history of high blood pressure, type 2 diabetes mellitus, and dyslipidemia, was admitted for abdominal pain and vomiting of 2-month progression. Two days later, she developed rectal bleeding, with hemodynamic instability (Hb 6 g/dl), and acute renal failure (Cr 6 mg/dl). Abdominal CT-angiography showed active intraluminal bleeding, arising from the splenic flexure (Fig. 1). Superselective arterial embolization of the distal branch of the left colic artery was performed, utilizing microspheres, with no immediate adverse events. At 24-48 h post-embolization, after new episodes of massive rectal bleeding, urgent colonoscopy was performed, leading to a diagnosis of fulminant ischemic pancolitis (Fig. 2).

Due to persistent hemodynamic instability and massive rectal bleeding, with no response to conservative treatment, urgent surgical intervention was decided upon and total colectomy with ileostomy was carried out.

The histopathologic evaluation of the surgical specimen confirmed the diagnosis of gangrenous IC.

Fulminant forms of IC, resulting in gangrenous necrosis with perforation, peritonitis, and death, do not exceed 5%. Only clinical suspicion confirmed by endoscopic findings enables early diagnosis and salvage therapy (colectomy in most cases)^{2,4}.

Multiple factors predispose to the development of IC. The most common causes are non-occlusive (atherosclerosis, hypoperfusion states, etc.), whereas the occlusive forms are more atypical. Those secondary to embolization are now exceptional¹.

Adverse events of arterial embolization are infrequent because most procedures are currently performed utilizing superselective catheterization^{5,6}. In a large study on 134 patients, intestinal ischemia was below 6%⁷.

The risk of symptomatic intestinal ischemia depends on the clinical-anatomic setting of the patient and the tech-

☆ Please cite this article as: Valdés-Delgado T, Jiménez-García VA, Galván-Fernández MD. Embolización arterial para control de sangrado gastrointestinal bajo. ¿Tratamiento o complicación? *Revista de Gastroenterología de México.* 2022;87:119–122.