



# REVISTA DE GASTROENTEROLOGÍA DE MÉXICO

[www.elsevier.es/rgmx](http://www.elsevier.es/rgmx)



## SCIENTIFIC LETTER

### Acute heart failure following transjugular intrahepatic portal-systemic shunting corrected through transient balloon occlusion<sup>☆</sup>



### Insuficiencia cardíaca aguda posterior a derivación portosistémica transyugular intrahepática corregida por medio de oclusión transitoria con globo

A transjugular intrahepatic portosystemic shunt (TIPS) relieves the portal hypertension (PHT) that can lead to the formation of ascites. Therefore, it should be able to reduce PHT recurrence and the incidence of complications, as well as improve survival in those patients.<sup>1,2</sup> However, data on extrahepatic factors that could specifically predict cardiovascular complications after TIPS placement are scarce.

A 59-year-old woman with cryptogenic cirrhosis (Child-Pugh B: 7 points, slightly modified Child-Pugh B: 7 points + MELD 15 points + MELD-Na: 16 points) was admitted to a tertiary care hospital for TIPS assessment due to refractory and recurrent ascites. Besides a history of active smoking, she had no functional limitations and no cardiac history. The patient stated that she did not drink alcohol. Before hospital admission, she had been prescribed a low-sodium diet and adequate diuretic doses, but she presented with clinically significant complications (creatinine >2.0 mg/dl) that were managed conservatively. The patient then manifested tense ascites and was treated with serial large-volume paracentesis and albumin administration (8 g/l of fluid removed) on more than 3 occasions within 12 months, with rapid recurrence. Spontaneous bacterial peritonitis was ruled out each time. The hepatologist and interventional radiologist began a pre-procedural evaluation. Upon admission, the laboratory work-up showed volume-responsive acute kidney injury (RIFLE 1, AKIN II) with a basal creatinine level of 1.85 mg/dl and a control of 1.2 mg/dl. The rest of the laboratory test results were hemoglobin 11.4 g/dl, hematocrit 34.3%, platelet count 137,000/mm<sup>3</sup>, prothrombin time 11.5 s, INR 1.04, total bilirubin 1.64 mg/dl, and albumin 3.9 g/dl. A chest x-ray

**Table 1** Pre-TIPS and post-TIPS hemodynamic measurements.

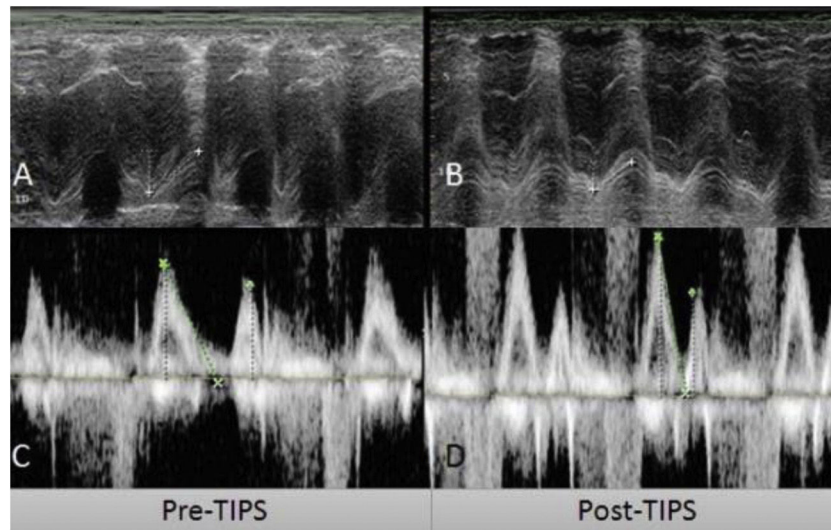
	Pre-TIPS	Post-TIPS
Right atrial pressure (mmHg)	12	20
Portal vein pressure (mmHg)	22	16
Portoatrial gradient (mmHg)	10	-4

revealed no alterations. A transthoracic echocardiogram showed normal ventricular function, a left ventricular ejection fraction of 70%, an E/A wave ratio of 1.2, minimal tricuspid regurgitation, and a pulmonary arterial systolic pressure of 28 mmHg (Fig. 1A). A duplex ultrasound showed normal portal vein patency and no liver masses. Twenty-four hours later, with the patient under general anesthesia, the interventional radiologist inserted a TIPS, using an 8 mm internal diameter × 10 cm long Gore® Viatorr® stent-graft (W.L. Gore, Flagstaff, AZ, USA), per standard protocol, between the right portal vein and the right hepatic vein. After the procedure, there was a decrease to -4 mmHg in the portoatrial gradient (portal vein pressure 16 mmHg - right atrial pressure 20 mmHg). Table 1 shows the hemodynamic parameters.

Twenty-four hours after TIPS placement, the patient presented with dyspnea at rest and the jugular venous pressure was markedly elevated. The abdomen was distended, with tense ascites, and no peripheral edema was present. A chest x-ray identified pleural effusion. A follow-up echocardiogram revealed a left ventricular ejection fraction of 75%, right cavity dilatation, paradoxical septal movement, severe tricuspid regurgitation, reduced tricuspid annular plane systolic excursion (TAPSE), increased filling pressures, and a pulmonary arterial systolic pressure of 40 mmHg (Fig. 1B). No response to diuretic and vasopressor treatment was observed. Due to clinical deterioration 72 h after the original TIPS placement, a balloon occlusion was performed. The patient's condition gradually improved, and she was discharged from the hospital. She was also considered a candidate for liver transplantation. During follow-up, there were no signs or symptoms of heart failure and a normal echocardiogram was documented.

After the re-direction of the mesenteric flow into the systemic circulation resulting from TIPS placement, an increase in central venous pressure, right atrial pressure, mean pulmonary pressure, pulmonary artery wedge pressure, cardiac index, and stroke volume<sup>3,4</sup> have been observed. A study of 158 patients undergoing TIPS insertion showed an increased left atrial diameter and left ventricular end-diastolic diameter, after 1 to 5 years of follow-up.<sup>5</sup> Diastolic dysfunction

<sup>☆</sup> Please cite this article as: Valdivia-Correa B, Reynier-Garza V, Chávez-Tapia N, Alanis-Estrada G, Araiza-Garayordobil D. Insuficiencia cardíaca aguda posterior a derivación portosistémica transyugular intrahepática corregida por medio de oclusión transitoria con globo. *Revista de Gastroenterología de México*. 2021;86:195–197.



**Figure 1** Pre-transjugular intrahepatic portosystemic shunt (TIPS) (A, C) and post-TIPS (B, D) echocardiogram measurements. A) Pre-TIPS TAPSE of 18.8 mm. B) Post-TIPS TAPSE of 14.4 mm. C) Pre-TIPS E/A wave ratio of 1.2. D) Post-TIPS E/A wave ratio of 1.54. TAPSE: tricuspid annular plane systolic excursion.

is often found in cirrhotic cardiomyopathy<sup>6</sup> and significant change in pulmonary artery systolic pressure has also been noted at short-term and long-term follow-up.<sup>7</sup> Even when hemodynamic changes after TIPS placement have been properly described, there are few studies that identify potential predictors of cardiovascular dysfunction.

A prospective study of 934 TIPS procedures recently identified factors that may predispose patients to the development of symptomatic heart failure (SHF) after TIPS placement. Patients with SHF had higher pre-TIPS right atrial (RA) pressure ( $p=0.03$ ) and portal vein pressure ( $p=0.01$ ), higher albumin ( $p=0.02$ ), and higher prothrombin time ( $p=0.02$ ). In the case of our patient, pre-TIPS RA pressure was also elevated. RA pressure is used as the reference after shunt creation, because the diverted portal flow artifactually raises the pressure within the outflow hepatic vein that drains the TIPS.<sup>8</sup>

In the case presented herein, acute heart failure, with impaired diastolic function and tricuspid valve regurgitation,<sup>9</sup> was sufficiently severe to preclude the benefits of portal systemic shunting. Despite inotropic and diuretic therapy, the patient persisted with systemic congestion and acute kidney injury. Much remains to be clarified regarding cardiac evaluation before placing a TIPS, including which patients will tolerate hemodynamic changes after said placement.

In conclusion, cardiac complications after TIPS insertion may preclude the positive effects of that therapy in patients with complications of portal hypertension. Pre-procedure evaluation that includes a cardiology consultation and routine transthoracic echocardiography is recommended in all cases. Extending the assessment to include advanced echocardiographic techniques, the dynamic evaluation of ventricular diastolic and systolic function, and the degree of tricuspid insufficiency may be appropriate in particular cases. Further studies on clinical factors, biomarkers, and cardiovascular imaging findings that may predict cardiac complications after TIPS placement are needed.

## Ethical considerations

Informed consent was not requested for the publication of the present case because no personal data that could identify the patient was published. The present case report was not submitted to an ethics committee.

## Financial disclosure

No specific grants were received from public sector agencies, the business sector, or non-profit organizations in relation to this article.

## Conflict of interest

The authors declare that there is no conflict of interest.

## References

1. Salerno F, Cammà C, Enea M, et al. Transjugular intrahepatic portosystemic shunt for refractory ascites: a meta-analysis of individual patient data. *Gastroenterology*. 2007;133:825–34, <http://dx.doi.org/10.1053/j.gastro.2007.06.020>.
2. Heinzow HS, Lenz P, Köhler M, et al. Clinical outcome and predictors of survival after TIPS insertion in patients with liver cirrhosis. *World J Gastroenterol*. 2012;18:5211–8, <http://dx.doi.org/10.3748/wjg.v18.i37.5211>.
3. Huonker M, Schumacher YO, Ochs A, et al. Cardiac function and haemodynamics in alcoholic cirrhosis and effects of the transjugular intrahepatic portosystemic stent shunt. *Gut*. 1999;44:743–8, <http://dx.doi.org/10.1136/gut.44.5.743>.
4. Kovács A, Schepke M, Heller J, et al. Short-term effects of transjugular intrahepatic shunt on cardiac function assessed by cardiac MRI: preliminary results. *Cardiovasc Intervention Radiol*. 2010;33:290–6, <http://dx.doi.org/10.1007/s00270-009-9696-2>.
5. Wannhoff A, Hippchen T, Weiss CS, et al. Cardiac volume overload and pulmonary hypertension in long-term follow-up of patients with a transjugular intrahepatic por-

- tosystemic shunt. *Aliment Pharmacol Ther.* 2016;43:955–65, <http://dx.doi.org/10.1111/apt.13569>.
6. Cazzaniga M, Salerno F, Pagnozzi G, et al. Diastolic dysfunction is associated with poor survival in patients with cirrhosis with transjugular intrahepatic portosystemic shunt. *Gut.* 2007;56:869–75, <http://dx.doi.org/10.1136/gut.2006.102467>.
  7. Pudil R, Praus R, Hulek P, et al. Transjugular intrahepatic portosystemic shunt is associated with significant changes in mitral inflow parameters. *Ann Hepatol.* 2013;12:464–70.
  8. Modha K, Kapoor B, Lopez R, et al. Symptomatic Heart Failure after Transjugular intrahepatic Portosystemic Shunt Placement: Incidence, Outcomes and Predictors. *Cardiovascular Intervention Radiol.* 2018;41:564–71, <http://dx.doi.org/10.1007/s00270-017-1848-1>.
  9. Badano LP, Muraru D, Enriquez-Sarano M, et al. Assessment of functional tricuspid regurgitation. *Eur Heart J.* 2013;34:1875–85, <http://dx.doi.org/10.1093/eurheartj/ehs474>.

B. Valdivia-Correa<sup>a</sup>, V. Reynier-Garza<sup>b</sup>, N. Chávez-Tapia<sup>a</sup>, G. Alanis-Estrada<sup>b</sup>, D. Araiza-Garaygordobil<sup>b,\*</sup>

<sup>a</sup> *Departamento de Gastroenterología, Clínica y Fundación Médica Sur, Mexico City, Mexico*

<sup>b</sup> *Unidad Coronaria, Instituto Nacional de Cardiología Ignacio Chávez, Mexico City, Mexico*

\* Corresponding author at: Juan Badiano 1, Sección XVI Tlalpan, Mexico City, Mexico. Tel.: 55 2895 6977. E-mail address: [dargaray@gmail.com](mailto:dargaray@gmail.com) (D. Araiza-Garaygordobil).

2255-534X/ © 2020 Asociación Mexicana de Gastroenterología. Published by Masson Doyma México S.A. This is an open access article under the CC BY-NC-ND license (<http://creativecommons.org/licenses/by-nc-nd/4.0/>).

## Hepatocellular carcinoma associated with direct-acting antiviral therapy for hepatitis C virus: A report of two cases<sup>☆</sup>



### Carcinoma hepatocelular asociado con el uso de la terapia antiviral de acción directa para virus de hepatitis C: reporte de dos casos

Hepatocellular carcinoma (HCC) is the fifth most common neoplasm worldwide and hepatitis C virus (HCV) is the leading cause, conditioning a 3 to 7% risk per year in patients with liver cirrhosis (LC).<sup>1</sup> In the era of pegylated interferon (PEG-IFN), the sustained virologic response (SVR) was about 50%, and in cirrhotic patients that achieved SVR, the incidence of HCC decreased to 0.5-1% annually.<sup>2</sup>

The introduction of direct-acting antiviral (DAA) therapy resulted in a reported SVR above 90%, with a positive impact on the course of HCC, reducing the adverse effects in patients with a more advanced disease stage.<sup>3</sup> Despite the promising results of DAA therapy, some reports suggest it may increase the risk for HCC occurrence and recurrence,<sup>4</sup> hence our decision to present the following 2 cases (Table 1).

#### Case 1

A 66-year-old man was diagnosed with LC secondary to HCV in 2014. A magnetic resonance imaging (MRI) study performed that same year revealed a 7.3 cm lesion in segment VII, displaying typical HCC behavior, for which he underwent transarterial embolization (TAE). In 2015, he again required TAE, after which he had complete radiologic response (CRR)

(Fig. 1a-c) and remained under surveillance. In March 2017, the patient achieved SVR with DAA therapy. A control imaging study performed after SVR showed that the lesion had progressed, with vascular invasion (Fig. 1d-f).

#### Case 2

A 74-year-old woman was diagnosed with LC secondary to HCV in 2016. An ultrasound study performed before she started DAA therapy showed no focal lesions. After achieving SVR, she presented with acute cholecystitis. A tomography scan revealed 2 lesions, one measuring 7 mm that displayed typical HCC behavior, and the other measuring 1.7 cm that had contrast medium enhancement (Fig. 1g). A biopsy was performed on the larger lesion, and HCC was reported. The patient underwent radiofrequency ablation (RFA), and 2 months later, the lesion had increased in size from 7 mm to 2.5 cm (Fig. 1h).

Despite the fact that the development and recurrence of HCC observed in our case reports appear to be associated with DAA therapy, evidence from recent studies has shown no such association. In a cohort study on 33,137 patients, Mun et al. evaluated the risk of *de novo* HCC developing after antiviral treatment and concluded that there were no significant differences in HCC risk after DAA treatment.<sup>5</sup> Those results were consistent for *de novo* cases and recurrence in a systematic review and meta-analysis by Rutledge et al. that included 138 studies (n = 177,512).<sup>6</sup>

The impact of DAA on liver transplantation has been evaluated in cohorts at European and Latin American centers, and in both of those studies, no evidence of higher waitlist progression or post-transplantation recurrence was reported.<sup>7,8</sup> The controversy derived from previous analyses appears to be related to study methodology.

Today, the benefit of treating patients with DAAs is clear and has been associated with a decrease in all-cause mortality.<sup>9</sup> Predictive scoring systems have been developed with the aim of stratifying the risk for HCC in patients that have undergone DAA therapy.<sup>10</sup>

<sup>☆</sup> Please cite this article as: Tapia-Sosa R, Hernández-Cabral F, Gabutti A, Páez-Zayas VM, García-Juárez I. Carcinoma hepatocelular asociado con el uso de la terapia antiviral de acción directa para virus de hepatitis C: reporte de dos casos. *Revista de Gastroenterología de México.* 2021;86:197–199.