

CLINICAL IMAGE IN GASTROENTEROLOGY

Laparoscopic hepatectomy of a hydatid cyst<sup>☆</sup>

Hepatectomía laparoscópica de quiste hidatídico

J. Cisneros-Correa<sup>\*</sup>, K.A. González-Espinoza, I. Domínguez-Rosado

Departamento de Cirugía Hepatopancreatobiliar, Instituto Nacional de Ciencias Médicas y Nutrición "Salvador Zubirán", Tlalpan, Mexico City, Mexico

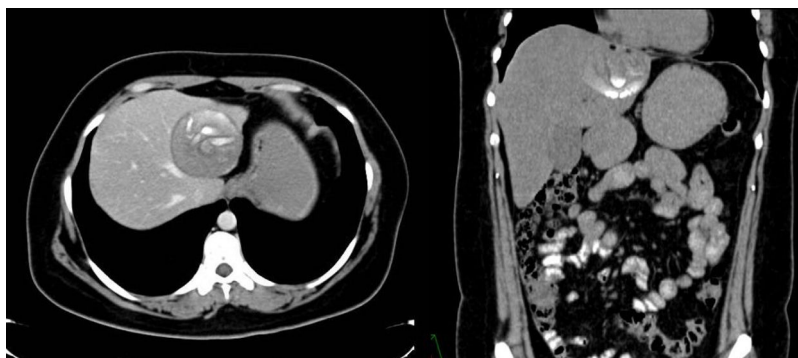

Figure 1 As the imaging study approach, a liver CAT scan was performed.

A 37-year-old woman with no comorbidities stated she had regular contact with pigs, dogs, and cows. Her current illness began one year earlier, with abdominal pain in the epigastrium. An abdominal ultrasound study identified a tumor in the left hepatic lobe, for which she was

referred to our hospital. As the imaging study approach, a CAT scan of the liver was carried out (Fig. 1) that revealed a 6.7 × 6.1 cm complex cystic lesion that involved liver segments II, III, and was touching segment IVa, as well as involving the inferior vena cava and the middle hepatic vein. It was associated with calcified zones and scant fat. Complementary liver ultrasound (Fig. 2) and contrast-enhanced MRI (Fig. 3) showed a lesion consistent with a stage CE4 hydatid cyst, according to the WHO classification. Serologic testing for hydatidosis was negative. The patient underwent laparoscopic left lateral hepatectomy. During the surgery, we found that the cyst was firmly attached to the inferior vena cava (Fig. 4) and was also very close to the middle hepatic vein (Fig. 5), but it did not communicate with the biliary tree. The pathology study confirmed the diagnosis of hydatid

<sup>☆</sup> Please cite this article as: Cisneros-Correa J, González-Espinoza KA, Domínguez-Rosado I. Hepatectomía laparoscópica de quiste hidatídico. Revista de Gastroenterología de México. 2021;86:188–190.

<sup>\*</sup> Corresponding author. Vasco de Quiroga 15 Col. Sección XVI Belisario Domínguez, Tlalpan, CP 14080 Mexico City, Mexico. Tel.: +01 (52) 54870900, Ext. 2140.

E-mail address: [julioccc7@gmail.com](mailto:julioccc7@gmail.com) (J. Cisneros-Correa).

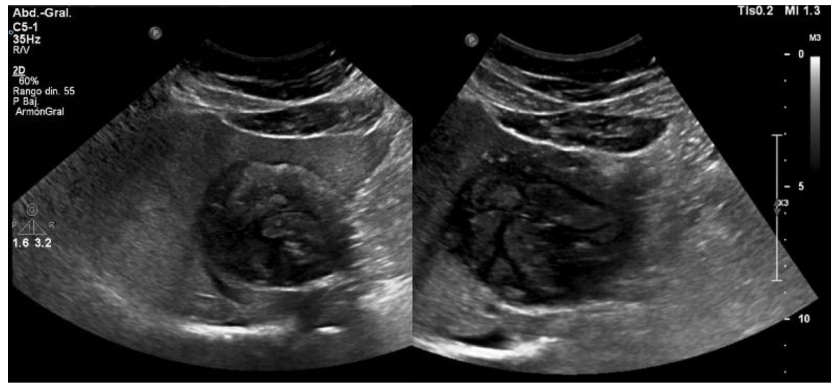


Figure 2 Complementary liver ultrasound study was performed.

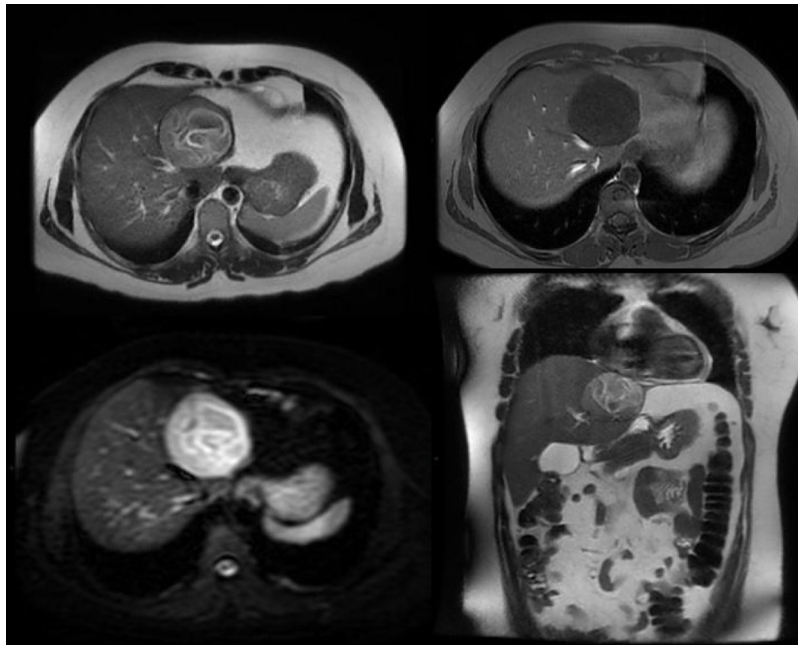


Figure 3 A contrast-enhanced MRI was performed.

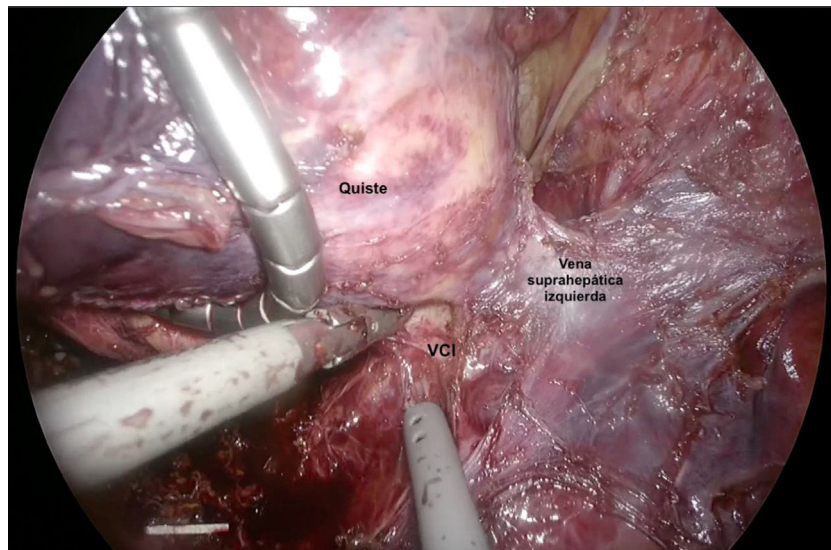
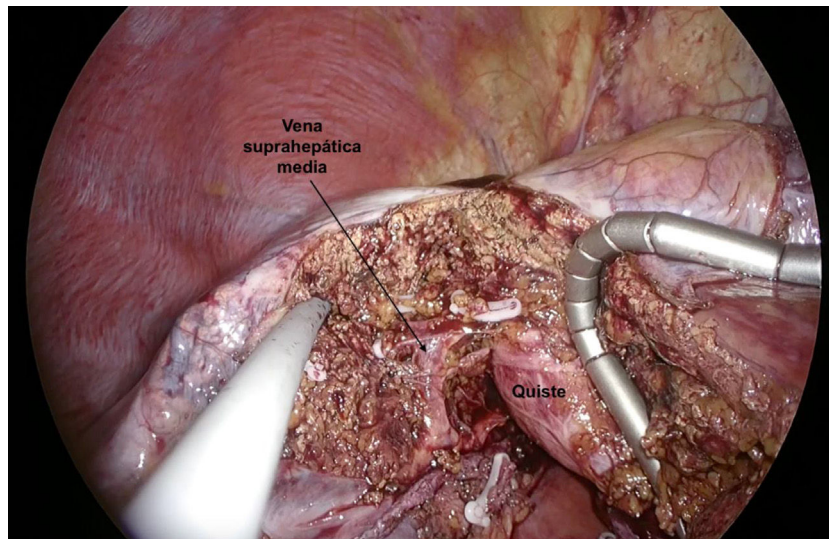


Figure 4 A cyst firmly attached to the inferior vena cava was found during the surgery.



**Figure 5** The cyst was very close to the middle hepatic vein.

cyst. The patient had good postoperative progression and was discharged 3 days after the surgery. She completed 6 weeks of postoperative treatment with albendazole and the 6-month follow-up period.

### **Ethical considerations**

The authors declare that the patient signed a statement of informed consent for the publication of the present text, conforming with the policies and norms of our institutional ethics committee. The present article contains no personal information that can identify the patient. No experiments were performed on animals or humans.

### **Financial disclosure**

No financial support was received in relation to the present article.

### **Conflict of interest**

The authors declare that there is no conflict of interest.  
IVC: inferior vena cava.