

## Gallstone lithotripsy with SpyGlass™ system through a cholecystoduodenal fistula in a patient with type IIIa Mirizzi syndrome<sup>☆</sup>



### Litotripsia de lito vesicular con SpyGlass™ a través de fistula colecistoduodenal en paciente con síndrome de Mirizzi tipo IIIa

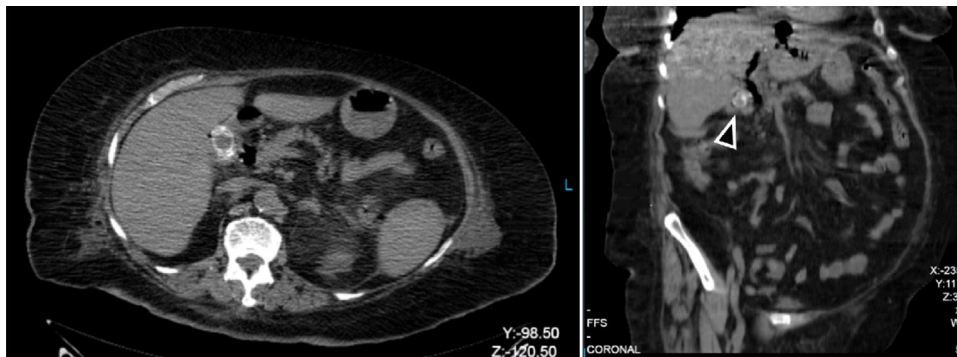
A 79-year-old woman was admitted to the hospital for community-acquired pneumonia, with a history of long-standing hypertension and ischemic heart disease managed through catheterization and a dual-chamber pacemaker. During her hospital stay, the patient presented with fever and intense abdominal pain in the right upper quadrant, with no other associated symptoms. Laboratory test results showed leukocytosis (17.6 cell/mm<sup>3</sup>, PMN: 15.3 cell/mm<sup>3</sup>), and the liver profile was within normal limits. A non-contrast abdominal computed tomography (CT) scan identified pneumobilia and a 3 cm stone in the gallbladder (Fig. 1). Endoscopic retrograde cholangiopancreatography (ERCP) was performed, revealing a filling defect of the common bile duct (CBD) and a stone in the gallbladder infundibulum, as well as a cholecystoduodenal fistula. Cholangioscopy was carried out with the SpyGlass™ single operator system (Boston Scientific Corp. Natick, USA), introducing it through the cholecystoduodenal fistula. Laser lithotripsy was performed, and the fragments were advanced into the duodenum and extracted with a basket (Fig. 2A). A double pig-tail catheter was then placed in the fistula (Fig. 2B). There were no complications during the procedure and post-operative progression was optimum, enabling the patient to be released 3 days later. Outpatient follow-up was indicated to evaluate fistula progression. A second ERCP was performed twenty weeks later that showed complete migration

of the catheter into the duodenum (Fig. 2C, D), complete closure of the cholecystoenteric fistula (CEF), and unaltered bile ducts.

Mirizzi syndrome (MS) is a late and rare complication of choledocholithiasis. It consists of an impacted stone in the gallbladder infundibulum, leading to chronic cholecystitis and CBD obstruction due to extrinsic compression. Both factors predispose to the development of fistulas between the gallbladder and other adjacent structures, especially if their treatment is delayed.<sup>1</sup> Fistulas occur in approximately 2 to 5% of the patients with cholelithiasis. There is important geographic variability in relation to MS, and Mexico is one of the regions with a higher incidence (4.7%).<sup>2</sup> Its classification has undergone changes in recent years due to its low incidence and the appearance of new cases with different comorbidities. The latest modification classifies MS into three types: 1) extrinsic compression of the CBD; 2) the presence of cholecystocholedochal fistula; and 3) the presence of CEF. CEF is subclassified, according to the presence or absence of gallstone ileus.<sup>3</sup> Because it is a chronic inflammatory process of the gallbladder, and due to its proximity to several abdominal organs, the development of CEF has been described as an advanced stage of MS, presenting in 1.8% of patients in a case series of 327 cases of said syndrome.<sup>1</sup>

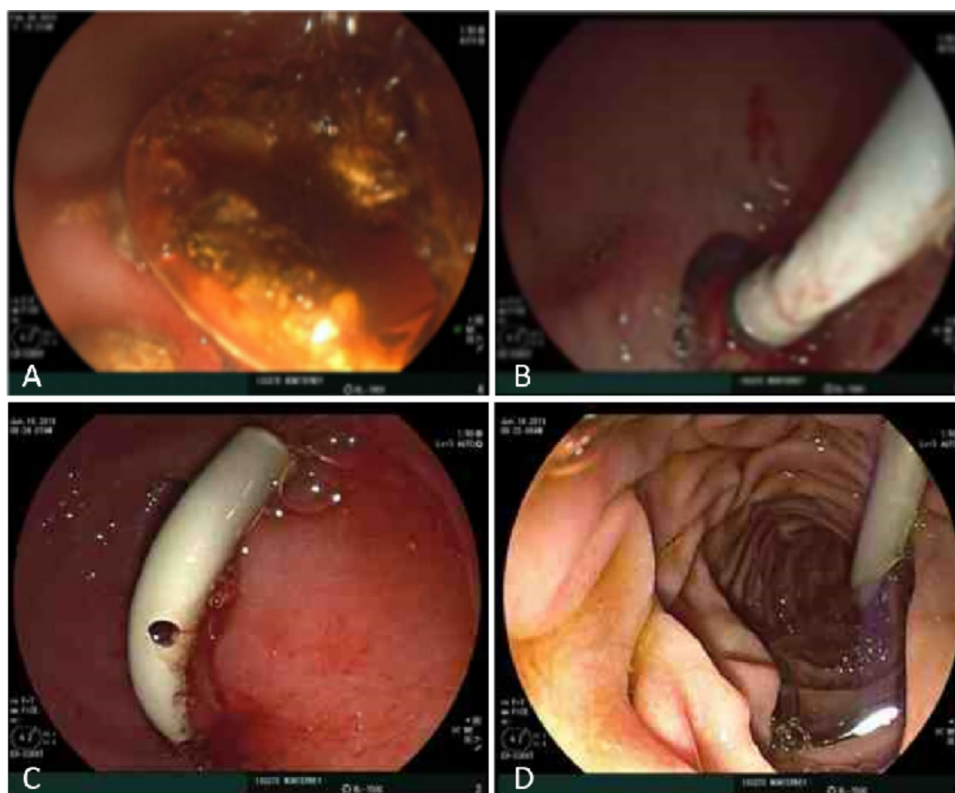
Given the variability of its initial presentation, MS diagnosis should be supported by its clinical characteristics, high surgical suspicion, and complementary imaging studies. Nevertheless, 50% of cases are diagnosed during surgery, which can create difficulties for the surgeon.<sup>4</sup> In the present case, given the clinical circumstances of the patient, CT was the initial diagnostic method employed. In spite of its low diagnostic yield in MS, that method has been shown to be useful in ruling out neoplasias.<sup>5</sup> Given the findings of the CT scan, we performed ERCP, which despite being a more invasive method, is considered the gold standard for the diagnosis of MS, with 76.2% sensitivity.<sup>5</sup>

The endoscopic management of a patient with biliary lithiasis through a CEF has been described. The reported



**Figure 1** Axial and coronal views of non-contrast abdominal computed tomography scan showing the stone within the gallbladder.

<sup>☆</sup> Please cite this article as: Baca-Arzaga AA, Navarro-Chávez A, Galindo-Jiménez A, Garza-Vega J, Flores-Villalba E. Litotripsia de lito vesicular con SpyGlass a través de fistula colecistoduodenal en paciente con síndrome de Mirizzi tipo IIIa. Revista de Gastroenterología de México. 2021;86:99–101.



**Figure 2** A) SpyGlass™-guided laser lithotripsy. B) Double pigtail catheter in the fistula. C and D) Catheter migration into the duodenum.

stones measured <1 cm, and thus their extraction from the duodenum through ERCP did not create the risk for gallstone ileus.<sup>6</sup> In our case, because the stone measured 3 cm, we opted for performing SpyGlass™-guided lithotripsy, which has a reported effectiveness of 92-100% in MS.<sup>7</sup> In addition to its effectiveness, it enabled us to evaluate the status of the gallbladder wall at the time the stone was removed, and finding it to be whole, we made the decision to preserve the gallbladder. The surgical risk involved in an open or laparoscopic cholecystectomy was taken into account, given our patient's comorbidities and the status of the biliary tree exposed to the chronic inflammatory process. The CEF was managed conservatively, under the premise that spontaneous closure would be facilitated by the restoration of the physiologic bile flow.<sup>8</sup>

In conclusion, the present case was an unusual situation, both regarding the presentation of MS (type IIIa) and the management chosen. MS is a pathology secondary to a chronic process, and we have observed that it is mainly reported in developing countries, such as Mexico, in which the necessary tools for noninvasive management are often not available. We had the good fortune of having the SpyGlass™ system, as well as the presentation of a CEF that enabled access to the gallbladder. It is our hope that the present case will contribute to the development of new guidelines for the diagnosis and noninvasive management of type IIIa MS.

### Ethical responsibilities

The authors declare that no experiments were performed on humans or animals for this study. Likewise, they declare that they have treated all patient data with confidentiality and anonymity, following the protocols of their work center. Finally, the data presented in this case have been authorized by the patient, with informed consent.

### Financial disclosure

No funding of any type was received in relation to this article.

### Conflict of interest

The authors declare that there is no conflict of interest.

### References

1. Beltran MA, Csendes A, Cruces KS. The relationship of Mirizzi syndrome and cholecystoenteric fistula: validation of a modified classification. *World J Surg.* 2008;32:2237-43, <http://dx.doi.org/10.1007/s00268-008-9660-3>.
2. Cortes Ruiz M, Vazquez García A. Frecuencia del síndrome de Mirizzi en un hospital de enseñanza. *Cir Gen.* 2003;25:334-7.

3. Beltrán MA. Mirizzi syndrome: History, current knowledge and proposal of a simplified classification. *World J Gastroenterol.* 2012;18:4639–50, <http://dx.doi.org/10.3748/wjg.v18.i34.4639>.
4. Valderrama-Treviño AI, Granados-Romero JJ, Espejel-Deloiza M, et al. Updates in Mirizzi syndrome. *Hepatobiliary Surg Nutr.* 2017;6:170–8, <http://dx.doi.org/10.21037/hbsn.2016.11.01>.
5. Chen H, Siwo EA, Khu M, et al. Current trends in the management of Mirizzi syndrome: A review of literature. *Medicine (Baltimore).* 2018;97:e9691, <http://dx.doi.org/10.1097/MD.0000000000009691>.
6. Ödemiş B, Arhan M, Parlak E, et al. Endoscopic removal of gallstones through a cholecystoduodenal fistula. *Gastrointest Endosc.* 2009;69:339–40, <http://dx.doi.org/10.1016/j.gie.2008.09.006>.
7. Bhandari S, Bathini R, Sharma A, et al. Usefulness of single-operator cholangioscopy-guided laser lithotripsy in patients with Mirizzi syndrome and cystic duct stones: Experience at a tertiary care center. *Gastrointest Endosc.* 2016;84:56–61, <http://dx.doi.org/10.1016/j.gie.2015.12.025>.
8. Nuño-Guzmán CM, Marin-Contreras ME, Figueroa-Sanchez M, et al. Gallstone ileus, clinical presentation, diagnostic and treatment approach. *World J Gastrointest Surg.* 2016;8:65, <http://dx.doi.org/10.4240/wjgs.v8.i1.65>.

A.A. Baca-Arzaga<sup>a</sup>, A. Navarro-Chávez<sup>b</sup>, A. Galindo-Jiménez<sup>b</sup>, J. Garza-Vega<sup>b</sup>, E. Flores-Villalba<sup>a,b,c,\*</sup>

<sup>a</sup> *Escuela de Medicina Tecnológico de Monterrey, Monterrey, Mexico*

<sup>b</sup> *Departamento de Cirugía General, Hospital Regional ISSSTE, Monterrey, Mexico*

<sup>c</sup> *Escuela Nacional de Ingeniería, Tecnológico de Monterrey, Monterrey, Mexico*

\* Corresponding author at: Av. Batallón de San Patricio 112, Real San Agustín, 66278 San Pedro Garza García, N.L. 81 8888 0310.

E-mail address: [eduardofloresvillalba@tec.mx](mailto:eduardofloresvillalba@tec.mx) (E. Flores-Villalba).

2255-534X/ © 2020 Asociación Mexicana de Gastroenterología. Published by Masson Doyma México S.A. This is an open access article under the CC BY-NC-ND license (<http://creativecommons.org/licenses/by-nc-nd/4.0/>).

## Endoscopic ultrasound-guided gastroenterostomy in gastric outlet obstruction (with video)<sup>☆</sup>



### Gastroenterostomía guiada por ultrasonido endoscópico en obstrucción al flujo de salida gástrico (con vídeo)

Endoscopic ultrasound-guided gastroenterostomy (EUS-GE) has recently become an alternative to surgery in the treatment of gastric outlet obstruction (GOO), mainly in patients that are not candidates for surgery or the endoscopic placement of a duodenal stent.<sup>1</sup>

We present herein the case of a 56-year-old man with advanced pancreatic cancer and oral intolerance secondary to duodenal stricture caused by tumor infiltration. Endoscopic ultrasound-guided gastrojejunostomy (EUS-GJ) was performed as part of palliative treatment.

With a therapeutic gastroscope, the gastric content was initially aspirated, and the stricture site identified. A 0.035'' hydrophilic guidewire (Jagwire™ Straight Tip, Boston Scientific, USA) was introduced through the stricture, using an 8.5 Fr stent introducer (Oasis® One Action Stent Introduction System, Cook Medical, USA) (Fig. 1A). When the guidewire was in front of the angle of Treitz, the stent introducer and gastroscope were removed, leaving the hydrophilic guidewire in the jejunum. A 7 Fr nasobiliary drainage catheter (Cook Medical, USA) was placed through the guidewire to instill approximately 800 cc of injectable water (Fig. 1B). Twenty milligrams of intravenous butylhyoscine

were administered to reduce peristaltic movement, and the linear echoendoscope (GF-UCT180 Olympus Medical Systems, Tokyo, Japan) was introduced. The jejunal segment was identified with water in its interior, through transgastric echoendoscopic scanning, and its closeness to the nasobiliary drain was corroborated through fluoroscopy. Finally, 30 cc of contrast medium with methylene blue were instilled to opacify the targeted jejunal segment. Gastrojejunostomy was performed with the lumen-apposing stent, using electrocautery (Hot AXIOS™ Stent 20 × 10 mm, Boston Scientific, USA), through direct puncture (no guidewire) and diathermy (Fig. 1C and D). The flow of methylene blue was corroborated through endoscopic vision (Fig. 2A and B), and then through fluoroscopy (Fig. 2C and D).

In 2002, Fritscher-Ravens et al. presented the first use of the EUS-GE technique in an animal model,<sup>2</sup> but it was not until special devices were created several years later that the development of the procedure was completed, and it was applied in humans. In 2012, Binmoeller and Shah, utilizing a lumen-apposing stent, reported on the feasibility of the procedure in 5 pigs.<sup>3</sup> Recently, direct puncture and balloon-assisted puncture are the 2 main techniques that have been described.<sup>1,4</sup> In a multicenter study that included 74 patients, the 2 techniques were compared. Both were found to be equally effective, but the direct puncture technique was a shorter procedure.<sup>5</sup>

Currently, the main indication for EUS-GE is GOO due to obstruction of the antrum-pylorus region, as well as of the first, second, and third part of the duodenum. Contraindications are obstruction of the gastric corpus, obstruction of the first part of the jejunum or the fourth part of the duodenum if the proximal jejunum cannot be reached, large volume ascites, and perigastric varices that prevent an adequate puncture window.<sup>4,6</sup>

We utilized a hybrid technique, a product of the experience of the Manuel Pérez-Miranda group in Valladolid, Spain. We advanced a nasobiliary drainage catheter (without a balloon) through a hydrophilic guidewire up to the targeted segment, enabling it to be filled with water or saline

<sup>☆</sup> Please cite this article as: Soto-Solis R, Pineda-de Paz MR, Osorno-Diaz G, Gallardo-Ramirez MA, Diaz-Coppe A. Gastroenterostomía guiada por ultrasonido endoscópico en obstrucción al flujo de salida gástrico (con vídeo). *Revista de Gastroenterología de México.* 2021;86:101–103.