

3. Beltrán MA. Mirizzi syndrome: History, current knowledge and proposal of a simplified classification. *World J Gastroenterol.* 2012;18:4639–50, <http://dx.doi.org/10.3748/wjg.v18.i34.4639>.
4. Valderrama-Treviño AI, Granados-Romero JJ, Espejel-Deloiza M, et al. Updates in Mirizzi syndrome. *Hepatobiliary Surg Nutr.* 2017;6:170–8, <http://dx.doi.org/10.21037/hbsn.2016.11.01>.
5. Chen H, Siwo EA, Khu M, et al. Current trends in the management of Mirizzi syndrome: A review of literature. *Medicine (Baltimore).* 2018;97:e9691, <http://dx.doi.org/10.1097/MD.0000000000009691>.
6. Ödemiş B, Arhan M, Parlak E, et al. Endoscopic removal of gallstones through a cholecystoduodenal fistula. *Gastrointest Endosc.* 2009;69:339–40, <http://dx.doi.org/10.1016/j.gie.2008.09.006>.
7. Bhandari S, Bathini R, Sharma A, et al. Usefulness of single-operator cholangioscopy-guided laser lithotripsy in patients with Mirizzi syndrome and cystic duct stones: Experience at a tertiary care center. *Gastrointest Endosc.* 2016;84:56–61, <http://dx.doi.org/10.1016/j.gie.2015.12.025>.
8. Nuño-Guzmán CM, Marin-Contreras ME, Figueroa-Sanchez M, et al. Gallstone ileus, clinical presentation, diagnostic and treatment approach. *World J Gastrointest Surg.* 2016;8:65, <http://dx.doi.org/10.4240/wjgs.v8.i1.65>.

A.A. Baca-Arzaga<sup>a</sup>, A. Navarro-Chávez<sup>b</sup>, A. Galindo-Jiménez<sup>b</sup>, J. Garza-Vega<sup>b</sup>, E. Flores-Villalba<sup>a,b,c,\*</sup>

<sup>a</sup> *Escuela de Medicina Tecnológico de Monterrey, Monterrey, Mexico*

<sup>b</sup> *Departamento de Cirugía General, Hospital Regional ISSSTE, Monterrey, Mexico*

<sup>c</sup> *Escuela Nacional de Ingeniería, Tecnológico de Monterrey, Monterrey, Mexico*

\* Corresponding author at: Av. Batallón de San Patricio 112, Real San Agustín, 66278 San Pedro Garza García, N.L. 81 8888 0310.

E-mail address: [eduardofloresvillalba@tec.mx](mailto:eduardofloresvillalba@tec.mx) (E. Flores-Villalba).

2255-534X/ © 2020 Asociación Mexicana de Gastroenterología. Published by Masson Doyma México S.A. This is an open access article under the CC BY-NC-ND license (<http://creativecommons.org/licenses/by-nc-nd/4.0/>).

## Endoscopic ultrasound-guided gastroenterostomy in gastric outlet obstruction (with video)☆



### Gastroenterostomía guiada por ultrasonido endoscópico en obstrucción al flujo de salida gástrico (con vídeo)

Endoscopic ultrasound-guided gastroenterostomy (EUS-GE) has recently become an alternative to surgery in the treatment of gastric outlet obstruction (GOO), mainly in patients that are not candidates for surgery or the endoscopic placement of a duodenal stent.<sup>1</sup>

We present herein the case of a 56-year-old man with advanced pancreatic cancer and oral intolerance secondary to duodenal stricture caused by tumor infiltration. Endoscopic ultrasound-guided gastrojejunostomy (EUS-GJ) was performed as part of palliative treatment.

With a therapeutic gastroscope, the gastric content was initially aspirated, and the stricture site identified. A 0.035'' hydrophilic guidewire (Jagwire™ Straight Tip, Boston Scientific, USA) was introduced through the stricture, using an 8.5 Fr stent introducer (Oasis® One Action Stent Introduction System, Cook Medical, USA) (Fig. 1A). When the guidewire was in front of the angle of Treitz, the stent introducer and gastroscope were removed, leaving the hydrophilic guidewire in the jejunum. A 7 Fr nasobiliary drainage catheter (Cook Medical, USA) was placed through the guidewire to instill approximately 800 cc of injectable water (Fig. 1B). Twenty milligrams of intravenous butylhyoscine

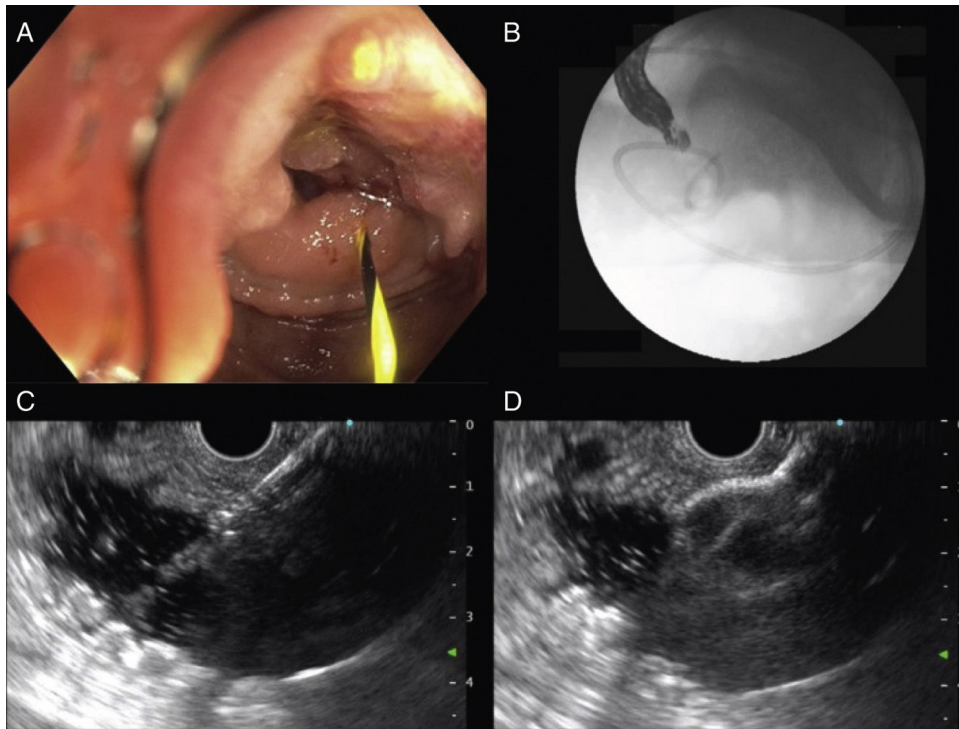
were administered to reduce peristaltic movement, and the linear echoendoscope (GF-UCT180 Olympus Medical Systems, Tokyo, Japan) was introduced. The jejunal segment was identified with water in its interior, through transgastric echoendoscopic scanning, and its closeness to the nasobiliary drain was corroborated through fluoroscopy. Finally, 30 cc of contrast medium with methylene blue were instilled to opacify the targeted jejunal segment. Gastrojejunostomy was performed with the lumen-apposing stent, using electrocautery (Hot AXIOS™ Stent 20 × 10 mm, Boston Scientific, USA), through direct puncture (no guidewire) and diathermy (Fig. 1C and D). The flow of methylene blue was corroborated through endoscopic vision (Fig. 2A and B), and then through fluoroscopy (Fig. 2C and D).

In 2002, Fritscher-Ravens et al. presented the first use of the EUS-GE technique in an animal model,<sup>2</sup> but it was not until special devices were created several years later that the development of the procedure was completed, and it was applied in humans. In 2012, Binmoeller and Shah, utilizing a lumen-apposing stent, reported on the feasibility of the procedure in 5 pigs.<sup>3</sup> Recently, direct puncture and balloon-assisted puncture are the 2 main techniques that have been described.<sup>1,4</sup> In a multicenter study that included 74 patients, the 2 techniques were compared. Both were found to be equally effective, but the direct puncture technique was a shorter procedure.<sup>5</sup>

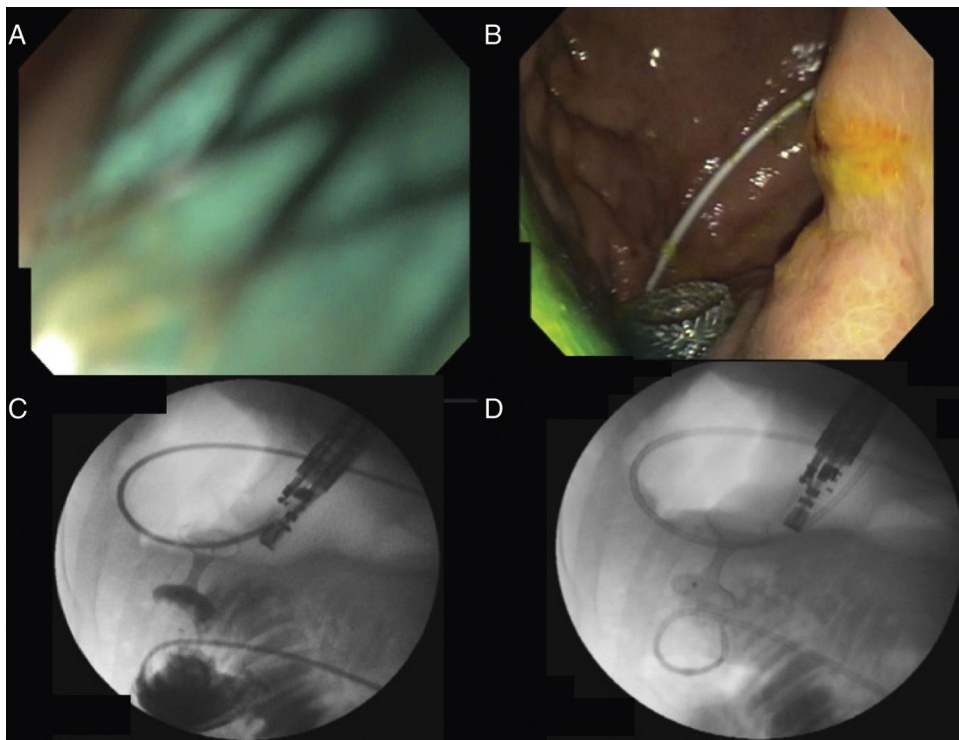
Currently, the main indication for EUS-GE is GOO due to obstruction of the antrum-pylorus region, as well as of the first, second, and third part of the duodenum. Contraindications are obstruction of the gastric corpus, obstruction of the first part of the jejunum or the fourth part of the duodenum if the proximal jejunum cannot be reached, large volume ascites, and perigastric varices that prevent an adequate puncture window.<sup>4,6</sup>

We utilized a hybrid technique, a product of the experience of the Manuel Pérez-Miranda group in Valladolid, Spain. We advanced a nasobiliary drainage catheter (without a balloon) through a hydrophilic guidewire up to the targeted segment, enabling it to be filled with water or saline

☆ Please cite this article as: Soto-Solis R, Pineda-de Paz MR, Osorno-Diaz G, Gallardo-Ramirez MA, Diaz-Coppe A. Gastroenterostomía guiada por ultrasonido endoscópico en obstrucción al flujo de salida gástrico (con vídeo). *Revista de Gastroenterología de México.* 2021;86:101–103.



**Figure 1** A) Advance of the hydrophilic guidewire through the malignant duodenal stricture. B) Fluoroscopy-guided placement of the nasobiliary drainage catheter in front of the angle of Treitz. C) Endoscopic ultrasound-guided puncture of the targeted segment. D) Release of the first flange of the lumen-apposing stent.



**Figure 2** A) Intra-channel release of the second flange. B) Endoscopic confirmation of the release of the second flange (note the presence of methylene blue). C) Contrast medium reflux from the jejunal segment into the stomach through the stent. D) Wash-out of the contrast medium from the stomach into the jejunal segment.

solution. We then added contrast medium and methylene blue as safety measures. The use of a nasobiliary catheter can increase costs, given that water, contrast medium, and methylene blue can be directly instilled using the gastro-scope. However, we believe the catheter provides better fluoroscopic vision control because it prevents erratic distribution of the contrast medium in the small bowel. The lumen-apposing stent release was direct (free-hand), aided only by the electrocautery tip.<sup>1,4</sup>

In 2017, Khashab et al. described the first 10 cases of EUS-GE in the United States.<sup>6</sup> In 2 later multicenter studies, the technique was compared with the standard procedure of surgical gastroenterostomy. Both the Pérez-Miranda group and the Khashab et al. studies showed the safety and efficacy of EUS-GE, situating it as a therapeutic option for patients with GOO.<sup>7,8</sup> In their study, Chen et al. compared EUS-GE with the placement of enteral stents, demonstrating that EUS-GE was an effective option, with a lower number of reinterventions in cases of malignant GOO.<sup>9</sup> Ours is the first performance of EUS-GE reported in Mexico and we believe, with the adequate human and material resources, it is a procedure that can be performed with high success rates and few adverse effects.

## Ethical considerations

The authors declare that the present article contains no information that could identify the patient and it meets the current bioethics research regulations. Informed consent was requested of the patient.

## Authorship

Rodrigo Soto-Solis, Mario R. Pineda-De Paz, Mario A. Gallardo-Ramirez, and Adriana Diaz-Coppe contributed to the concept, design, literature review, and drafting of the manuscript. Georgina Osorno-Diaz and Rodrigo Soto-Solis edited the video. Rodrigo Soto-Solis and Mario R. Pineda-de Paz collected the data and images and reviewed the manuscript to verify the intellectual content. All the authors had access to the manuscript and approved the final version.

## Financial disclosure

No specific grants were received from public sector agencies, the business sector, or non-profit organizations in relation to this study.

## Conflict of interest

The authors declare that there is no conflict of interest.

## Supplementary material

Supplementary material related to this article can be found, in the online version, at doi:<https://doi.org/10.1016/j.rgmxe.2020.02.005>.

## References

1. Rimbaz M, Larghi A, Costamagna G. Endoscopic ultrasound-guided gastroenterostomy: Are we ready for prime time? *Endosc Ultrasound*. 2017;6:235–40, <http://dx.doi.org/10.4103/eus.eus.47.17>. PMID: 28820145.
2. Fritsher-Ravens A, Mosse CA, Mills TN, et al. A through-the-scope device for suturing and tissue approximation under EUS control. *Gastrointest Endosc*. 2002;56:737–42, <http://dx.doi.org/10.1067/mge.2002.129084>. PMID: 12397289.
3. Binmoeller KF, Shah JN. Endoscopic ultrasound-guided gastroenterostomy using novel tools designed for transluminal therapy: A porcine study. *Endoscopy*. 2012;44:499–503, <http://dx.doi.org/10.1055/s-0032-1309382>. PMID: 22531985.
4. Irani S, Baron TH, Itoi T, et al. Endoscopic gastroenterostomy: techniques and review. *Curr Opin Gastroenterol*. 2017;33:320–9, <http://dx.doi.org/10.1097/MOG.0000000000000389>.
5. Chen YI, Kunda R, Storm AC, et al. EUS-guided gastroenterostomy: a multicenter study comparing the direct and balloon-assisted techniques. *Gastrointest Endosc*. 2018;87:1215–21, <http://dx.doi.org/10.1016/j.gie.2017.07.030>.
6. Khashab MA, Kumbhari V, Grimm IS, et al. EUS-guided gastroenterostomy: The first U.S. clinical experience (with video). *Gastrointest Endosc*. 2015;82:932–8, <http://dx.doi.org/10.1016/j.gie.2015.06.017>. PMID: 26215646.
7. Perez-Miranda M, Tyberg A, Poletto D, et al. EUS-guided gastrojejunostomy versus laparoscopic gastrojejunostomy. *J Clin Gastroenterol*. 2017;51:896–9, <http://dx.doi.org/10.1097/MCG.0000000000000887>. PMID: 28697151.
8. Khashab M, Bukhari M, Baron T, et al. International multicenter comparative trial of endoscopic ultrasonography-guided gastroenterostomy versus surgical gastrojejunostomy for the treatment of malignant gastric outlet obstruction. *Endosc Int Open*. 2017;5:E274–81, <http://dx.doi.org/10.1055/s-0043-101695>. PMID: 28382326.
9. Chen YI, Itoi T, Baron TH, et al. EUS-guided gastroenterostomy is comparable to enteral stenting with fewer re-interventions in malignant gastric outlet obstruction. *Surg Endosc*. 2017;31:2946–52, <http://dx.doi.org/10.1007/s00464-016-5311-1>. PMID: 27834024.

R. Soto-Solis<sup>a,b,\*</sup>, M.R. Pineda-de Paz<sup>a</sup>, G. Osorno-Diaz<sup>a</sup>, M.A. Gallardo-Ramirez<sup>b</sup>, A. Diaz-Coppe<sup>a</sup>

<sup>a</sup> *Servicio de Endoscopia, Centro Médico Nacional 20 de Noviembre, ISSSTE, Mexico City, Mexico*

<sup>b</sup> *Departamento de Gastroenterología, Hospital Ángeles Pedregal, Mexico City, Mexico*

\*Corresponding author at: Camino a Santa Teresa 1055, Torre Ángeles, consultorio 650, Héroes de Padierna, Magdalena Contreras, CP 10700, Mexico City, Mexico. Phone: 52(55)51355982.

E-mail address: [rodrigotomd@hotmail.com](mailto:rodrigotomd@hotmail.com) (R. Soto-Solis).

2255-534X/ © 2021 Published by Masson Doyma México S.A. on behalf of Asociación Mexicana de Gastroenterología. This is an open access article under the CC BY-NC-ND license (<http://creativecommons.org/licenses/by-nc-nd/4.0/>).