



REVISTA DE GASTROENTEROLOGÍA DE MÉXICO

www.elsevier.es/rgmx



SCIENTIFIC LETTER

Double pylorus secondary to peptic ulcer disease

Doble píloro secundario a enfermedad ulcerosa péptica

Pyloric duplication is the formation of an accessory channel between the distal stomach and the duodenal bulb, in which the gastric antrum and the bulb communicate by means of 2 openings separated by a channel or bridge.

An 83-year-old woman had a history of hip prosthesis replacement, arthrosis, high blood pressure, and diabetes mellitus, for which she received numerous medications, including nonsteroidal anti-inflammatory drugs (NSAIDs). Her cardiology control follow-up revealed a decrease in hemoglobin from 12 g/dl to 9.7 g/dl (MCV 89.7, MCH 29.3), and so she was referred to the gastroenterology department.

The patient reported a history of reflux and intermittent epigastralgia, for which she sporadically took ranitidine and omeprazole. One week before the consultation, she experienced a self-limited episode of melena, and so was scheduled for upper endoscopy. Physical examination showed slight paleness and no other alterations.

Upper endoscopy revealed a deep ulcer in the antrum, measuring approximately 3 cm, with defined edges and a fibrin base (Fig. 1A). There was a perforation at the edge of the ulcer adjacent to the pylorus, which enabled the passage of the instrument into the duodenum (Fig. 1B). The pathologic anatomy of the edges of the ulcer showed only mild superficial chronic gastritis, with no atrophy or metaplasia. The

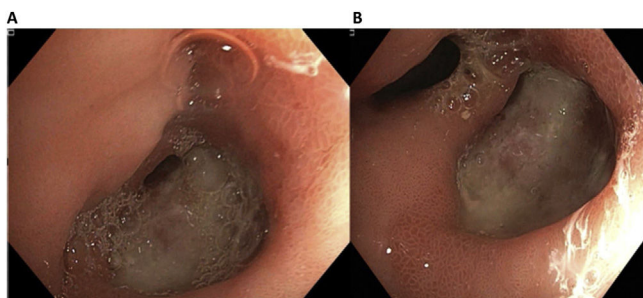


Figure 1 A) Antral ulcer adjacent to the pylorus and measuring approximately 3 cm, deforming its opening. B) The ulcer presented with a perforation bordering the pylorus that enabled the passage of the instrument (double lumen).

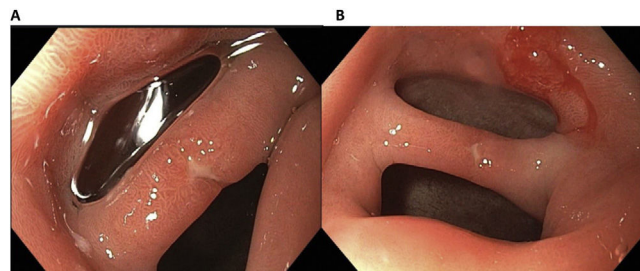


Figure 2 A) Isolated erosions in the mucosal septum. B) Mucosal septum creating two openings into the duodenum – the double pylorus sign.

presence of *Helicobacter pylori* (*H. pylori*) was negative. Oral lansoprazole, 30 mg every 12 h, was indicated.

At 3 months, the patient was asymptomatic, and a control endoscopy was programmed. It revealed re-epithelialization of the ulcer, with only isolated erosions and a definitive mucosal septum that created two openings into the duodenum from the stomach (double pylorus sign) (Figs. 2A and B).

The prevalence of double pylorus varies from 0.001 to 0.4%,^{1,2} and the condition is also known as double-channel pylorus, gastroduodenal fistula, pyloric membrane, and pyloric diaphragm.³

Double pylorus originates due to the presence of an ulcer in the gastric wall that perforates the duodenum or vice versa, and when it re-epithelializes, creates a mucosal septum.^{2–4} The fistula is generally produced in the lesser curvature of the stomach and is connected to the upper wall of the duodenal bulb. However, cases have been described in which the ulcer occurs in the greater curvature and communicates with the third or fourth part of the duodenum.⁵

H. pylori infection, NSAID use, and certain chronic systemic diseases are the usual risk factors.^{1,5} Double pylorus is an acquired complication in the majority of cases, although congenital cases have been reported.⁴ Acquired cases of double pylorus are secondary to peptic ulcer disease or gastric cancer.

In general, double pylorus is asymptomatic and is an incidental finding after an episode of upper gastrointestinal bleeding, as occurred with our patient. Diagnosis is made through endoscopy, upon observing an accessory orifice of variable diameter, with the absence of peristalsis.

Treatment of double pylorus tends to be conservative, with a high dose of a proton pump inhibitor. In some cases,

endoscopic septum division can be considered. Surgical management should never be the first choice, but up to 20% of patients require surgery due to refractory symptoms or other complications.^{2,4} With respect to progression, double pylorus remains permeable in the majority of cases (64%), it fuses with the normal pylorus in 27%, and closes on its own in 9%.²

Ethical considerations

The authors declare that no experiments were conducted on humans for this study. In addition, we utilized the protocols for obtaining information from the patient database of our work center, preserving the anonymity of the patient, requesting informed consent.

Financial disclosure

No financial support was received in relation to this article.

Author contributions

The authors have participated in the concept and design of the article, its drafting, and in approving the final version for publication.

Conflict of interest

The authors declare that there is no conflict of interest.

References

1. Oktaricha H, Miftahussurur M. Double pylorus in upper gastrointestinal bleeding. *Case Rep Gastroenterol*. 2021;15:332–7, <http://dx.doi.org/10.1159/000513804>.
2. Fousekis F, Aggeli P, Kotsaftis P, et al. Double pylorus: report of a case with endoscopic follow-up and review of the literature. *Gastroenterol Res*. 2018;11:154–6, <http://dx.doi.org/10.14740/gr960w>.
3. Hernández Hernández R, Estévez-López M, Estrada-Vaillant A, et al. Píloro doble. Presentación de un caso y revisión de la literatura. *Rev Méd Electrón*. 2019;41:189–95 [Accessed 20 Sep 2023]. Available from: http://scielo.sld.cu/scielo.php?script=sci_arttext&pid=S1684-18242019000100189&lng=es
4. Vida-Pérez L, Castillo-Molina L, González-Galilea A, et al. Doble píloro: hallazgo inusual de una enfermedad común. *Gastroenterol Hepatol*. 2009;32:75–6, <http://dx.doi.org/10.1016/j.gastrohep.2008.09.002>.
5. Kiyak M, Üçer M, Şentürk-Demirtaş C, et al. Double pylorus presenting with gastrointestinal bleeding: a rare case report. *Clin Ter*. 2023;174:4–7, <http://dx.doi.org/10.7417/CT.2023.2489>.

H. Cedrón-Cheng^{a,*}, S.A. Chávez-Sánchez^b

^a *Servicio de Gastroenterología, Clínica Anglo Americana, Lima, Peru*

^b *Servicio de Gastroenterología, Hospital Nacional Cayetano Heredia, Lima, Peru*

* Corresponding author. Calle Alfredo Salazar 350 - SanIsidro - Lima, Peru. Phone: +51 999697998.

E-mail address: hcedron@gmail.com (H. Cedrón-Cheng).