




# REVISTA DE GASTROENTEROLOGÍA DE MÉXICO

[www.elsevier.es/rgmx](http://www.elsevier.es/rgmx)



## CLINICAL IMAGE IN GASTROENTEROLOGY

### Nivolumab-induced gastritis in a patient with metastatic melanoma<sup>☆</sup>

### Gastritis inducida por nivolumab en un paciente con melanoma metastásico

D. Martínez-Acitores de la Mata<sup>a,\*</sup>, V. Busto-Bea<sup>a</sup>, C. Cerezo-Aguirre<sup>b</sup>

<sup>a</sup> Departamento de Gastroenterología, Complejo Hospitalario de Navarra, Pamplona, Navarra, Spain

<sup>b</sup> Departamento de Patología, Complejo Hospitalario de Navarra, Pamplona, Spain



A 70-year-old man with metastatic melanoma (T3bN2M1) treated with nivolumab (62 cycles, 3 mg/kg every 14 days) for the last 2.5 years was admitted to the hospital with epigastric pain, hyporexia, and vomiting of one-month progression. Laboratory data and abdominal computed tomography showed no significant findings. Esophagogastroduodenoscopy was performed, revealing thick mucosal exudates, diffuse congestion, edema, erythema, and friability of the gastric mucosa (Fig. 1). Gastric biopsies showed an inflammatory cell infiltrate in the lamina propria, crypt abscesses, and glandular destruction (Fig. 2), suggestive of an adverse event related to nivolumab therapy. There was no evidence of *Helicobacter pylori* (*H. pylori*) infection. Nivolumab was discontinued and the patient received proton pump inhibitor (PPI) therapy. The patient was discharged 3 weeks after admission and remains asymptomatic 6 months after nivolumab suspension. Immune checkpoint inhibitors,

such as nivolumab, are frequently associated with gastrointestinal adverse events. Diarrhea and enterocolitis are the more common presentations, and esophagitis and gastritis are rare. Nivolumab-induced gastritis can benefit from immunotherapy cessation, PPI use, and corticosteroid therapy. Testing for *H. pylori* infection should be carried out, as said bacterium can worsen the clinical course.

#### Ethical considerations

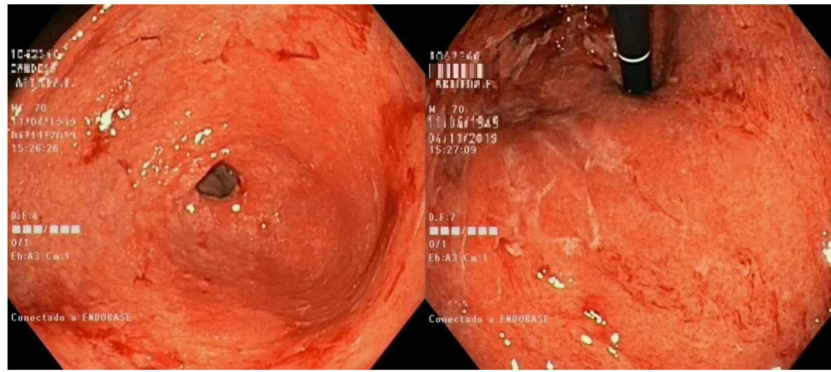
The patient provided his informed consent to receive the treatment and participate in the present research, which complies with the current regulations on bioethical research and was authorized by the institutional ethics committee.

The authors declare that the present article contains no personal information that could identify the patient.

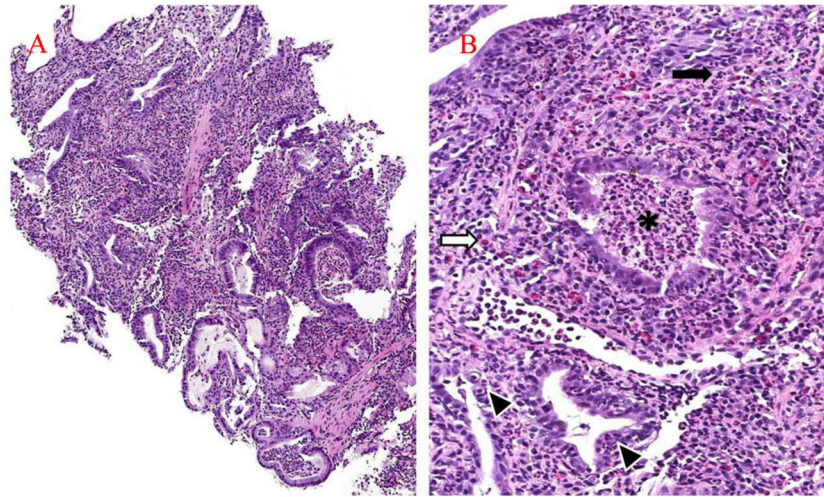
<sup>☆</sup> Please cite this article as: Martínez-Acitores de la Mata D, Busto-Bea V, Cerezo-Aguirre C. Gastritis inducida por nivolumab en un paciente con melanoma metastásico. Revista de Gastroenterología de México. 2021;86:90–91.

\* Corresponding author at: Complejo Hospitalario de Navarra. Calle de Irunlarrea, 3, 31008, Pamplona, Navarra. Tel.: +34 629744259.

E-mail address: [Diegoacitores132@hotmail.com](mailto:Diegoacitores132@hotmail.com)  
(D. Martínez-Acitores de la Mata).



**Figure 1** Esophagogastroduodenoscopy showing thick mucosal exudates with diffuse mucosal congestion, edema, and erythema, as well as gastric atrophy.



**Figure 2** A) Gastric biopsy shows marked architectural distortion secondary to the presence of a dense inflammatory infiltrate within the lamina propria (H&E x100). B) The inflammatory infiltrate is mainly composed of neutrophils (black arrow) but eosinophils are also present (white arrow). Cryptitis (arrowheads) and crypt abscesses (asterisk) are prominent (H&E x200).

### Financial disclosure

No financial support was received in relation to this study/article.

### Conflict of interest

The authors declare that there is no conflict of interest.