



REVISTA DE GASTROENTEROLOGÍA DE MÉXICO

www.elsevier.es/rgmx



SHORT COMMUNICATION

Association between cholesterol gallstones and testosterone replacement therapy in a patient with primary hypogonadism[☆]



S. Squarza^{1,*}, U.G. Rossi^{1,2}, P. Torcia¹, M. Cariati¹

¹ Department of Radiology, ASST Santi Paolo e Carlo, Hospital San Carlo Borromeo, Milan, Italy

² Interventional Radiology Unit, Galliera Hospital, Mura delle Cappuccine 14, Genoa

Received 27 March 2017; accepted 7 September 2017

KEYWORDS

Gallstones;
Testosterone;
Cholesterol;
Primary
hypogonadism;
Therapy;
Gallbladder

Abstract A 16-year-old boy had a past medical history of primary hypogonadism, due to bilateral anorchia. He presented with gallstones located in the gallbladder and a mild dilatation of the intrahepatic biliary tree. The histology study reported cholesterol gallstones. The patient had been treated with testosterone replacement therapy since infancy. We suggest a possible correlation between testosterone replacement therapy and the presence of cholesterol gallstones.

© 2018 Published by Masson Doyma México S.A. on behalf of Asociación Mexicana de Gastroenterología. This is an open access article under the CC BY-NC-ND license (<http://creativecommons.org/licenses/by-nc-nd/4.0/>).

PALABRAS CLAVE

Cálculos biliares;
Testosterona;
Colesterol;
Hipogonadismo
primario;
Terapia;
Vesícula biliar

Asociación de coleditiasis y terapia de reemplazo de testosterona en un paciente con hipogonadismo primario

Resumen Tratamos a un niño de 16 años de edad con hipogonadismo primario debido a la anorquia bilateral, que presentó cálculos biliares en la vesícula biliar con una leve dilatación del árbol biliar intrahepático. La histología de los cálculos biliares confirmó la naturaleza de colesterol de los mismos. El niño fue tratado desde la infancia con terapia de reemplazo de testosterona. Sugerimos una posible correlación entre la terapia de reemplazo de testosterona y la presencia de cálculos biliares de colesterol.

© 2018 Publicado por Masson Doyma México S.A. en nombre de Asociación Mexicana de Gastroenterología. Este es un artículo Open Access bajo la licencia CC BY-NC-ND (<http://creativecommons.org/licenses/by-nc-nd/4.0/>).

[☆] Please cite this article as: Squarza S, Rossi UG, Torcia P, Cariati M. Asociación de coleditiasis y terapia de reemplazo de testosterona en un paciente con hipogonadismo primario. Revista de Gastroenterología de México. 2018;83:205–207.

* Corresponding author. ASST Santi Paolo e Carlo, Department of Radiology and Interventional Radiology, Via Pio II, 3 20153 Milan, Italy, Telephone: +39 02 40222465; Fax: +39 02 40222465.

E-mail address: silvia.squarza@yahoo.it (S. Squarza).

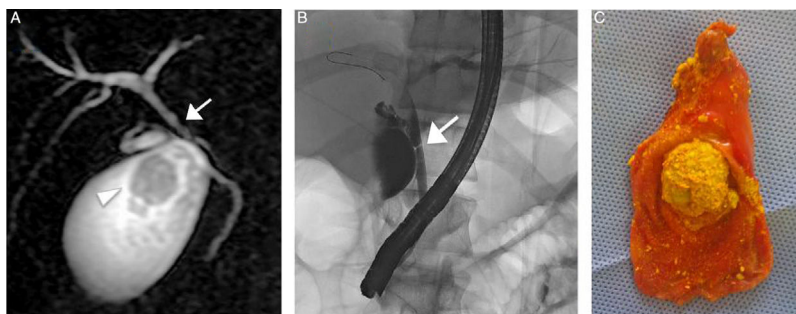


Figure 1 A) MRI study showing the 2.8 cm gallstones (arrowhead) and confirming the common hepatic duct stricture (arrow). B) Endoscopic retrograde cholangiopancreatography confirming the common hepatic duct stricture (arrow) with mild dilatation of the intrahepatic biliary tree. C) Gallbladder with multiple gallstones (note the largest one measuring 2.8 cm) after laparoscopic cholecystectomy.

Primary hypogonadism due to bilateral anorchia is a rare condition characterized by the complete absence of testicular tissue in an individual with a normal karyotype and phenotype. Its etiology is not completely understood, and various hypotheses have been proposed: an alteration in gonadal vascularization, an endocrinologic disorder, or a possible genetic etiology.^{1,2}

Clinical data on those patients are very limited. Virilization is the primary aim of therapy and it usually involves injectable testosterone ester or transdermal testosterone application.³

The aim of the present article was to report the case of a 16-year-old boy with primary hypogonadism, due to bilateral anorchia, who developed cholelithiasis, which in our opinion was caused by his replacement therapy. He underwent treatment with injectable ester testosterone enanthate, since infancy, and the current monthly dose of the intramuscular injection was 200 mg. The patient arrived at our hospital to undergo clinical and laboratory follow-up after a 3-month history of right upper abdominal pain. Upon physical examination, his height was 1.73 m and weight was 76.7 kg. Abdomen was normal, blood pressure was 126/71 mmHg, and heart rate was 68 bpm. Laboratory data showed normal testosterone (2.54 ng/ml), reduced luteinizing hormone (0.10 U/l) and follicle-stimulating hormone (0.4 U/l), and a mild elevation of serum gamma glutamyl transferase (345 U/l), aspartate aminotransferase (72 U/l), alanine aminotransferase (255 U/l), and direct bilirubin (1.6 mg/dl). Plasma cholesterol levels (low-density lipoprotein [LDL] and high-density lipoprotein [HDL]) were normal.

Abdominal ultrasound revealed normal liver structure, but gallstones located in the gallbladder with mild dilatation of the intrahepatic biliary tree. An MRI study confirmed the mild dilatation of the intrahepatic biliary tree, multiple gallstones (one measured 2.8 cm and the others less than 1 cm) in the gallbladder, and common hepatic duct stricture. None of the gallstones had a signal on the fat sat sequence, corroborating cholesterol gallstones.

The patient underwent endoscopic retrograde cholangiopancreatography, confirming the common hepatic duct stricture, with mild dilatation of the intrahepatic biliary tree. Consequently, he was treated with bilioplasty (6 x 40 mm, COOK, Bloomington, Indiana, USA), with the

placement of a 10-Fr biliary endoprosthesis (COOK, Bloomington, Indiana, USA). Seventy-two hours after the endoscopic retrograde cholangiopancreatography, the patient underwent laparoscopic cholecystectomy, corroborating mild dilatation of the gallbladder with multiple gallstones. The histologic study reported gallstones with a mean cholesterol content of 83% and a higher biliary saturation index (143). **Figure 1** shows the MRI (A), endoscopic retrograde cholangiopancreatography (B), and laparoscopic cholecystectomy (C).

The biliary endoprosthesis was endoscopically removed at the follow-up at one month. No abdominal symptoms were demonstrated in the clinical observation, abdominal symptom assessment, laboratory data, and abdominal ultrasound at the follow-up at 36 months. Serum liver enzyme levels were normal, and the liver and biliary tree had regular aspects.

Risk factors for gallstones in children include hemolytic disease, obesity, prematurity, sepsis, total parenteral nutrition, chronic liver disease, inflammatory bowel diseases, diuretic use, and ceftriaxone use, all of which were ruled out, clinically and through laboratory and imaging data, as causes of the gallstones in our patient.

It is well-known that testosterone plays an important role in male sexual differentiation, as well as being a central modulator of metabolic processes. To date, limited data are available regarding testosterone's effects on the modulation of hepatic cholesterol homeostasis-related proteins.⁴⁻⁵

Cholesterol homeostasis is controlled by coordinated changes in the expression of multiple genes involved in cholesterol biosynthesis, uptake, and efflux. The transhepatic transport of cholesterol from plasma lipoproteins into the bile is critical for overall cholesterol homeostasis and its alterations may lead to cholesterol gallstone formation.⁶

Several studies have been conducted on animals in relation to the effects of androgens on lipid metabolism. Tyagi et al. and Kline et al. demonstrated that LDL cholesterol levels increased significantly in animals treated with testosterone enanthate and its active metabolite inhibited gallbladder motility through nongenomic actions.^{7,8}

Concerning plasma cholesterol uptake in the liver, the low-density lipoprotein receptor (LDLr) is responsible for

removing LDL cholesterol from the blood. A recent study demonstrated that testosterone deficiency causes severe hypercholesterolemia and altered hepatic LDLr expression, with reduced LDL-cholesterol clearance. That could be reversed by testosterone replacement therapy, with increased cholesterol uptake by the liver and its biliary concentration.⁵

There are also several studies in the literature conducted on prostate cancer cell lines demonstrating that androgens cause a marked and coordinated upregulation of the expression of several lipogenic genes.⁹ In particular, Heemers et al. demonstrated androgen-induced changes in lipogenic gene expression in androgen-responsive tissues outside of the genital tract.¹⁰

In addition, our patient had an elevated biliary saturation index and mean cholesterol content in the gallstones, according to the literature.

All these data support the hypothesis that testosterone plays an important role in cholesterol metabolism. In fact, testosterone increases cholesterol uptake by the liver through the regulation of LDLr expression, most likely leading to augmented biliary concentration and reduced gallbladder motility.^{5,8}

Considering all the above data, we support the hypothesis that androgen therapy improves cholesterol production and uptake by the liver, with an augmented risk for gallstones. Further studies providing more data are needed to support our hypothesis.

Ethical disclosures

Protection of human and animal subjects. The authors declare that no experiments were performed on humans or animals for this study.

Confidentiality of data. The authors declare that no patient data appear in this article.

Right to privacy and informed consent. The authors declare that no patient data appear in this article.

Financial disclosure

No financial support was received in relation to this study/article.

Conflict of interest

The authors declare that there is no conflict of interest.

References

1. Bobrow M, Gough MH. Bilateral absence of testes. *Lancet*. 1970;1:366.
2. Rouso I, Iliopoulos D, Athanasiadou F, et al. Congenital bilateral anorchia: Hormonal, molecular and imaging study of a case. *Genet Mol Res*. 2006;5:638–42.
3. Boehm U, Bouloux PM, Dattani MT, et al. European consensus statement on congenital hypogonadotropic hypogonadism-pathogenesis, diagnosis and treatment. *Nat Rev Endocrinol*. 2015;11:547–64.
4. Constantinou C, Mpatsoulis D, Natsos A, et al. The low density lipoprotein receptor modulates the effect of hypogonadism on diet-induced obesity and related metabolic perturbations. *J Lipid Res*. 2014;55:1434–47.
5. Cai Z, Xi H, Pan Y, et al. Effect of testosterone deficiency on cholesterol metabolism in pigs fed a high-fat and high-cholesterol diet. *Lipids Health Dis*. 2015;7:18.
6. Zanlungo S, Rigotti A, Nervi F. Hepatic cholesterol transport from plasma into bile: Implications for gallstone disease. *Curr Opin Lipidol*. 2004;15:279–86.
7. Tyagi A, Rajalakshmi D, Jeyaraj A, et al. Effects of long-term use of testosterone enanthate. II. Effects on lipids, high and low density lipoprotein cholesterol and liver function parameters. *Int J Androl*. 1999;22:347–55.
8. Kline LW, Karpinski E. Testosterone and dihydrotestosterone inhibit gallbladder motility through multiple signalling pathways. *Steroid*. 2008;73:1174–80.
9. Swinnen JV, Ulrix W, Heyns W, et al. Coordinate regulation of lipogenic gene expression by androgens: Evidence for a cascade mechanism involving sterol regulatory element binding proteins. *Proc Natl Acad Sci U S A*. 1997;94:12975–80.
10. Heemers H, Vanderhoydonc F, Roskams T, et al. Androgens stimulate coordinated lipogenic gene expression in normal target tissues in vivo. *Mol Cell Endocrinol*. 2003;205:21–31.