

# Endoscopic ultrasound-guided celiac plexus neurolysis in patients with unresectable pancreatic cancer

Ramirez-Luna MA<sup>1</sup>, Chavez-Tapia NC<sup>2</sup>, Franco-Guzman AM<sup>2</sup>, Garcia-Saenz-de-Sicilia M<sup>2</sup>, Tellez-Avila FI<sup>2</sup>

<sup>1</sup> Department of Endoscopy. Instituto Nacional de Ciencias Medicas y Nutricion Salvador Zubiran, Mexico City, Mexico.

<sup>2</sup> Department of Gastroenterology. Instituto Nacional de Ciencias Medicas y Nutricion Salvador Zubiran, Mexico City, Mexico.

**Correspondence:** Miguel A. Ramírez, M.D. Department of Endoscopy. Instituto Nacional de Ciencias Médicas y Nutrición "Salvador Zubirán". Vasco de Quiroga #15. Col. Sección XVI. Del. Tlalpan. C.P. 14000. Mexico City, Mexico. (+ 525) 554870900, ext: 2715. E-mail: mangelramirez@yahoo.com

Fecha recibido: 7 abril 2008 • Fecha aprobado: 22 julio 2008

## Abstract

**Background:** The treatment of pain in patients with pancreatic cancer is a difficult topic for the patients and their physicians. There are different treatment modalities with variable results. Celiac plexus neurolysis (CPN) is a technique with good previous results using fluoroscopy, CT guidance and recently, guided by endoscopic ultrasound (EUS). The aim of this study is to report the experience of EUS guided CPN (EUS CPN) for treatment of abdominal pain in patients with unresectable pancreatic cancer. **Methods:** Patients with inoperable pancreatic cancer diagnosed by CT, MRI and/or EUS were included. The measurement of pain was made with a visual analog pain scale applied before and after the procedure. Follow up was made at weeks 2 and 4 after the procedure. The use of morphine before and after EUS CPN was evaluated. Complications related to the procedure were recorded. **Results:** Eleven patients (five men and six women) underwent to the procedure, the mean age was 59 years (range 43-82). In follow-up at four weeks after the procedure, pain scores were reduced by at least 5 points of visual analog pain scale in 9 (72.2%) patients. At least a fifty percent reduction in pain or more was documented in 7 (63.6%) patients. Five patients substantially reduced their pain medication. No complications were seen in this study. **Conclusions:** The EUS NPC is an efficient and safe

## Resumen

**Antecedentes:** El tratamiento del dolor en pacientes con cáncer de páncreas es difícil para el paciente y sus médicos. El uso de las diferentes modalidades de tratamiento tiene disponibilidad, complicaciones y resultados variables. La neurolysis de plexo celíaco (NPC) es una técnica con buenos resultados usando guía fluoroscópica o por tomografía computarizada. El objetivo de este estudio es reportar la experiencia de la neurolysis del plexo celíaco guiado por ultrasonido endoscópico (NPC USE) en pacientes con cáncer de páncreas irresecable. **Métodos:** Los pacientes con cáncer pancreático inoperable diagnosticados por TC, RMI y / o USE en el Instituto Nacional de Ciencias Médicas y Nutrición Salvador Zubirán, México; fueron incluidos en este estudio. La medición del dolor se hizo con una visual analógica del dolor aplicada antes y después del procedimiento. El seguimiento fue realizado en las semanas dos y cuatro después del procedimiento. El uso de morfina antes y después de la USE NPC se evaluó. Las complicaciones relacionadas con el procedimiento fueron registradas. **Resultados:** Once pacientes (cinco hombres y seis mujeres) fueron sometidos a NPC USE. La mediana de edad fue 59 años (intervalo 43-82). En el seguimiento a cuatro semanas la intensidad del dolor se redujo por al menos cinco puntos en la EVA, en nueve (72.2%) pacientes. En siete (63.6%) pacientes

method for pain treatment in those patients with inoperable pancreatic cancer.

**Key words:** celiac plexus; neurolysis; endoscopic ultrasound.

se observó una reducción de al menos 50% de la intensidad del dolor. En cinco, se redujo de manera significativa el uso de medicamentos. No se identificaron complicaciones.

**Conclusión:** La NPC USE es un método eficaz y seguro para el tratamiento del dolor en pacientes con cáncer de páncreas irresecable.

**Palabras clave:** plexo celiaco, neurolisis, ultrasonido endoscópico.

## Introduction

The management of abdominal pain in patients with inoperable pancreatic cancer is a clinical challenge. This symptom is significantly associated with an impaired quality of life,<sup>1</sup> herein the necessity for an effective treatment. There are different modalities of treatment for this problem: non-steroidal anti-inflammatory drugs (NSAID), narcotics, fluoroscopy and computed tomography (CT)-guided celiac plexus neurolysis (CPN) and surgery. The success and complications in these different modalities are variable. Narcotics are the most commonly used treatment, however some problems related to their chronic use are difficult to tolerate, e.g. dependency, constipation, delirium, nausea, and vomiting. All these secondary effects can adversely affect quality of life.

The injecting of alcohol into the celiac plexus to destroy the nervous fibers is an effective method for treatment of pain in patients with pancreatic cancer. There are reports of better overall health-related quality of life in patients with CPN than those patients with only pharmacological management.<sup>2</sup>

The percutaneous route to inject absolute alcohol into the celiac plexus under either fluoroscopic or CT guidance are both effective techniques but previous reports show that CPN endoscopic ultrasound-guided (EUS CPN) is safer, effective and less expensive than the percutaneous route.<sup>3-5</sup>

The aim of the present study was to evaluate the safety and efficacy of EUS CPN for the palliation of patients with pain related to inoperable pancreatic cancer.

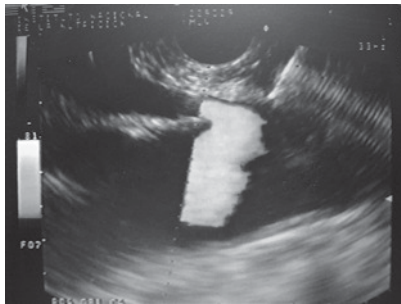## Materials and methods

In a retrospective analysis of data obtained prospectively the records of patients with pain caused by pancreatic cancer who underwent EUS CPN at the Instituto Nacional de Ciencias Médicas y Nutrición "Salvador Zubirán" from March 2005 to May 2007 were evaluated. All patients have unresectable pancreatic cancer confirmed by computed tomography (CT), magnetic resonance imaging (MRI) and/or EUS; EUS criteria and fine-needle aspiration (FNA) were used when a tissue diagnosis was not available before EUS. They underwent to EUS CPN during the same EUS procedure for diagnosis.

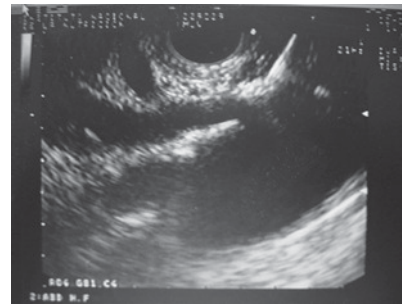
Before the procedure all patients had laboratory tests including prothrombin time and full blood count. The patients were placed in left decubitus position and sedated by using a combination of midazolam, propofol and phentanyl by anesthesiologist. Patients were continually monitored with an automated noninvasive blood pressure device, electrocardiogram, and pulse oximetry throughout the procedure. EUS CPN was performed with a linear array echoendoscope GFUCT-140 (Olympus) by an experienced echoendoscopist. The angle formed by the aorta and celiac trunk was identified through the posterior gastric wall. Under direct EUS visualization, a 22 gauge, 8 cm aspiration needle (Wilson-Cook Medical, Inc. Winston-Salem, N.C.) primed with normal saline solution was placed immediately adjacent and anterior to the aorta at the level of the celiac trunk (**figure 1**). After injecting 2 mL of saline solution to clear the needle, an aspiration test was performed, if no blood was obtained, 10 mL of 1% lidocaine was

**Figure 1.**

Needle adjacent and anterior to the aorta at the level of the celiac trunk.

**Figure 2.**

Injection of 1% lidocaine.

**Table 1.**

Baseline characteristics of the patients

Patient	Gender	Age (y)	CA 19-9 (U/L)	Total Bilirubin mg/dL	Serum Amylase (U/L)	Serum Lipase (U/L)	Alkaline Phosphatase (U/L)	Hemoglobin (g/dL)
1	M	43	10.9	0.72	28	29	88	11.7
2	F	64	67.1	1.07	NA	NA	262	10.9
3	M	71	11844	1.5	120	46	1542	11.3
4	F	59	187.5	0.39	24	23	91	13.7
5	M	58	998	10.4	NA	NA	1118	11.7
6	M	52	0.8	0.3	113	51	127	14.4
7	M	54	36963	0.56	33	28	92	11.2
8	F	65	3445	0.62	45	37	63	13.5
9	F	81	17182	4.9	19	16	394	7.6
10	F	56	.80	0.60	NA	NA	97	11.7
11	F	82	554	0.61	NA	NA	57	12.9

M: male; F: female; y: years; NA: not available.

injected (**figure 2**). The aspiration test was repeated, and if no blood, 20 mL of dehydrated 98% absolute alcohol was injected. The needle was then flushed with 3 mL of saline solution and withdrawn from the patient. After the procedure a Doppler ultrasound of the celiac trunk and aorta was made to evaluate permeability. The average estimated time for the EUS CPN portion of the procedure was 10 minutes. After the procedure all patients remained under observation for at least 2 hours to rule out any complications. All patients were reevaluated for complications 7 days after the procedure.

Dosage and class of pharmacologic treatment were evaluated before the procedure as well as 15 days and 30 days after procedure. Measurement of intensity of pain was made with a validated visual analog pain scale (0-10) in all patients<sup>6</sup> by a pain

specialist. Measurements two and four weeks after the procedure were made. The complications related to the EUS CPN were determined in agreement with the medical records.

Medians, ranges and proportions were used to summarize the demographics and clinical variables. EUS CPN pain scores paired before and after (15 and 30 days) were compared with the Friedman test.

## Results

Eleven patients underwent EUS CPN. The characteristics of the patients are in **table 1**. Five men (45.5%) and six women (54.5%) were included (median age was 59 years; range 43 to 82 years).

**Table 2.**

Characteristics of tumors observed on patients included in the study

Patient	Histological type	Tumor Location	Tumor size (mm)*	Vascular invasion
1	Neuroendocrine	Body	70f60	Yes
2	Adenocarcinoma	Body	75f70	Yes
3	Adenocarcinoma	Head	69f45	Yes
4	Adenocarcinoma	Body	50f45	Yes
5	Adenocarcinoma	Head	60f60	Yes
6	Adenocarcinoma	Head	59f54	Yes
7	Adenocarcinoma	Body	30f42	Yes
8	Adenocarcinoma	Head	35f50	Yes
9	Adenocarcinoma	Body	30f40	Yes
10	Adenocarcinoma	Body	NA	Yes
11	Adenocarcinoma	Body	30f40	Yes

\*Maximum diameters; NA: no available.

**Table 3.**

Score of pain and treatment before and after celiac plexus neurolysis

Patient	Visual analog pain scale (0-10)			Treatment	
	Before	15 days	30 days	Before	30 days
1	8	2	3	Narcotic	NSAID
2	8	10	NA§	Narcotic	NA§
3	8	4	3	Narcotic	Narcotic
4	10	2	2	Narcotic	Narcotic
5	6	3	4	Narcotic	NT
6	8	2	2	Narcotic	NT
7	9	8	9	Narcotic	Narcotic
8	10	5	5	Narcotic	Narcotic
9	10	0	5	Narcotic	Narcotic
10	10	0	0	Narcotic	NSAID
11	9	0	2	Narcotic	NSAID

NA: not available; NSAID non-steroidal anti-inflammatory drugs; NT: not treatment required. § Patient died at day 22 after procedure.

The tumor was located in the head of the pancreas in 4 patients (36.4%), and 7 (63.6%) in the body. Adenocarcinoma was the most common histological type (10/11 cases). 100% of the patients had major arterial or mesenteric venous invasion based in EUS and/or CT findings. The characteristic of the tumor are in **table 2**.

Overall, pain scores decreased significantly from median of 9 (range 6-10) before EUS CPN to a median of 2 (range 0-10) at 2 weeks after EUS CPN. The differences persisted 4 weeks after EUS CPN (median 3; range 0-9) ( $p < 0.001$ ).

Two weeks after the procedure, compared with baseline, eight patients had a reduction of  $\geq 4$  points in visual analog pain scale. At 4 weeks these 8 patients continued to show this improvement.

All patients were treated with narcotics before EUS CPN. After the procedure, two patients went without any medical treatment and another three patients only received NSAID. Morphine usage was not significantly different over time in 5 (45.4%) patients; however their score on the visual analog pain scale had reduced (**table 3**).

## Complications

There were no major complications. No patient was hospitalized after an outpatient procedure. Among patients already hospitalized, none had prolongation of their hospital stay because of the procedure. Five (45.4%) patients had transient abdominal pain after the procedure. More frequent stools for a period  $\leq 72$  hours were noted in six (54.5%) patients.

## Discussion

This work represents the first report in full-text from a Mexican center in relationship with EUS CPN. Our results show that EUS CPN reduced pain scores in 81.8% of the patients. Pain scores decreased in at least 50% from baseline within 2 and 4 weeks after the procedure. These results are similar to previous reports.<sup>5</sup>

The CPN with different methods has been described with good results. Eisenberg *et al*<sup>7</sup> and Ischia *et al*,<sup>8</sup> both concluded that CPN was effective in reducing pain in 70 to 90% and 60 to 75% of patients, respectively. They used different percutaneous techniques including fluoroscopy and CT guidance. Both EUS CPN and CT-guidance are effective and safe methods. According with our results and those obtained by other authors, advantages of EUS CPN are the ability to obtain a tissue sample, apply therapeutic measures like prosthesis and obtain better sensibility and specificity for tumor staging all in the same procedure.<sup>9-10</sup> EUS CPN is performed with the patient under conscious sedation and may therefore be better tolerated than CPN performed by percutaneous techniques with the patient under local anesthesia. Laparoscopic CPN has been recently reported,<sup>11</sup> one study with nine patients shows good initial results of the procedure performed surgically. When, hypothetically, we compare with the surgical approach, proposed advantages of EUS CPN are less time, cost and minimal invasion.

A systematic review that included five RCTs (no one included EUS CPN) involving 302 patients

concluded that in patients with inoperable pancreatic cancer, neurolytic celiac plexus blockade (NCPB) is associated with improved pain control and reduced narcotic usage.<sup>12</sup> All this studies<sup>8,11,12</sup> show that the CPN or NCPB are the key to the procedure irrespective of the technique.

Regarding “blockade” vs. “neurolysis”, the first is a temporary method using steroids and the second is a permanent treatment using alcohol to destroy the neural fibers of the celiac trunk. In our study neurolysis was the only procedure applied.

The limitations of this study include the inherent difficulties in retrospective studies, the small number of patients, lack of quality-of-life evaluation, and difficulties in measuring pain, which is a variable and subjective experience. It is important to mention that pain specialists obtained pain scores and not endoscopic team members which eliminate a potential bias. In conclusion, the EUS CPN is an efficient and safe method for pain management in patients with inoperable pancreatic cancer.

## Bibliography

1. Muller-Nordhom J, Roll S, Bohmig M, Nocon M, Reich A, Braun C *et al.* Health-related quality of life in patients with pancreatic cancer. *Digestion* 2006;74(2):118-25.
2. Kawamata M, Ishitani K, Ishikawa K *et al.* Comparison between celiac plexus block and morphine treatment on quality of life in patients with pancreatic cancer pain. *Pain* 1996;64:597-602.
3. Gress F, Schmitt C, Sherman S, Ikenberry S, Lehman G. A prospective randomized comparison of endoscopic ultrasound- and computed tomography-guided celiac plexus block for managing chronic pancreatitis pain. *Am J Gastroenterol* 1999;94:900-5.
4. Wiersema MJ, Wiersema LM. Endosonography-guided celiac plexus neurolysis. *Gastrointest Endosc* 1996;44:656-62.
5. Gunaratnam N, Sarma A, Norton ID, Wiersema M. A prospective study of EUS-guided celiac plexus neurolysis for pancreatic cancer pain. *Gastrointest Endosc* 2001;54:316-324.
6. Jensen MP, Karoly P, Braver S. The measurement of clinical pain intensity: a comparison of six methods. *Pain* 1986;27:117-26.
7. Eisenberg E, Carr DB, Chalmers TC. Neurolytic celiac plexus block for treatment of cancer pain: a meta-analysis. *Anesth Analg* 1995;80:290-5.
8. Ischia S, Ischia A, Polati B, Finco G. Three posterior percutaneous celiac plexus block techniques. A prospective, randomized study in 61 patients with pancreatic cancer pain. *Anesthesiology* 1992;76: 534-40.
9. Vilmann P, Jacobsen GK, Henriksen FW, Hancke S. Endoscopic ultrasonography with guided fine needle aspiration biopsy in pancreatic disease. *Gastrointest Endosc* 1992;38:172-3.
10. Wiersema MJ. Accuracy of endoscopic ultrasound in diagnosing and staging pancreatic carcinoma. *Pancreatol* 2001;1:625-632.
11. Strong VE, Dalal KM, Malhotra VT, Cubert KH, Coit D, Fong Y, Allen PJ. Initial report of laparoscopic celiac plexus block for pain relief in patients with unresectable pancreatic cancer. *J Am Coll Surg* 2006;203:129-31.
12. Yan BM, Myers RP. Neurolytic Celiac Plexus Block for Pain Control in Unresectable Pancreatic Cancer. *Am J Gastroenterol* 2007;102:430-438.