

# Laparoscopic management of idiopathic esophageal achalasia

Ketan M. Desai MD,\* Nathaniel J. Soper MD\*

\* Department of Surgery, Washington University School of Medicine.

Correspondence: Ketan M. Desai MD, Department of Surgery, Washington University School of Medicine, 660 South Euclid, WUMS Box 8109, 63110, St. Louis, MO, USA. Tel. (314) 362-8389, (314) 747-0591. E-mail: desaik@msnotes.wustl.edu.

Recibido para publicación: 02 de mayo de 2003.

Aceptado para publicación: 31 de julio de 2004.

**RESUMEN Introducción:** la acalasia fue descrita en 1682 como un trastorno motor del músculo liso del esófago. En 1913 se introdujo la técnica de cardiomiectomía transabdominal y en 1958 la vía transtorácica, en 1991 se describió la cardiomiectomía por vía laparoscópica y posteriormente el abordaje toracoscópico. Muchos cirujanos han adoptado esta vía de abordaje como el de elección para el tratamiento de la acalasia. **Objetivos:** analizar la utilidad y actualidades de cirugía endoscópica en manejo de la acalasia de esófago, así como generalidades en su presentación clínica y diagnóstico. **Material y métodos:** se realizó una revisión de la literatura médica y la serie de casos tratados por nuestro grupo de 1996 al 2004. **Resultados:** de 1996 a 2004, 84 pacientes fueron sometidos a esofagomiectomía de Heller por laparoscopia. A todos se les agregó una funduplicatura parcial (78 Toupet y seis Dor) para el tratamiento de acalasia. El tiempo quirúrgico varió de 2-3 horas (m 2.5 h). La perforación transoperatoria de la mucosa esofágica/gástrica ocurrió en tres pacientes la cual fue reparada con cierre primario evolucionando sin complicaciones postoperatorias. Tres pacientes requirieron de dilataciones endoscópicas durante el seguimiento y uno requirió reoperación por adherencias que causaban angulación de la unión esofagogástrica. **Conclusiones:** la miotomía de Heller por laparoscopia aportó una reducción marcada en la disfagia, con síntomas mínimos de regurgitación, pirosis o dolor torácico, con un seguimiento medio de dos años.

**Palabras clave:** laparoscopia, miotomía esofágica, acalasia.

**SUMMARY Introduction:** Idiopathic esophageal achalasia was described in 1682 as a motor disorder of smooth muscle. In 1913 transabdominal cardiomyotomy was introduced and in 1958 this technique was popularized via a left thoracotomy, in 1991 laparoscopic cardiomyotomy was introduced since then many surgeons have adopted this technique as the primary treatment of esophageal achalasia. **Objective:** Evaluate usefulness and recent advances in endoscopic surgery for the management of esophageal achalasia, as well as general issues in clinical presentation and diagnosis. **Methods:** We did a review of the medical literature and of our series of patients treated between 1996 and 2004. **Results:** Between 1996 and 2004, 84 patients underwent laparoscopic Heller myotomy and partial funduplication (78 Toupet and 6 Dor) for the treatment of achalasia. Operative time ranged from 2 to 3 hours with a mean of 2.5 hours. Mucosal perforation (esophageal/gastric) occurred in 3 patients and was repaired with primary closure. During follow-up 3 patients required postoperative endoscopic dilation and one required reoperation due to adhesions causing angulation of the g-e-junction. **Conclusions:** Laparoscopic Heller myotomy provided marked reduction in dysphagia, with minimal complaints of regurgitation, heartburn and chest pain at a mean follow-up of 2 years.

**Key words:** Laparoscopy, esophageal achalasia, myotomy.

## INTRODUCTION

In 1682 Thomas Willis described idiopathic esophageal achalasia as a motor disorder of smooth muscle in which

the lower esophageal sphincter (LES) does not relax properly with swallowing, and the normal peristalsis of the esophageal body is replaced by abnormal contractions.<sup>1</sup> This rare, benign disorder of the esophagus most

commonly affects individuals 25 to 60 years of age and has an equal sex distribution.<sup>2</sup> Defective esophageal emptying secondary to aperistalsis and failure of the LES to relax with swallowing is the hallmark of idiopathic esophageal achalasia. This abnormality leads to progressive proximal dilatation, morbid symptoms and malnutrition.

Following the introduction of the transabdominal cardiomyotomy in 1913 by Ernest Heller, surgeons have explored various access routes to the lower esophagus for the treatment of esophageal motility disorders. In 1958, Ellis et al popularized the cardiomyotomy via a left thoracotomy.<sup>3</sup> The recent inception of advanced minimally invasive surgery has led to improved thoracoscopic and laparoscopic access to the gastroesophageal junction.<sup>4</sup> With the introduction of laparoscopic cardiomyotomy in 1991,<sup>5</sup> many surgeons have adopted this technique as a primary treatment for idiopathic esophageal achalasia.

### CLINICAL PRESENTATION

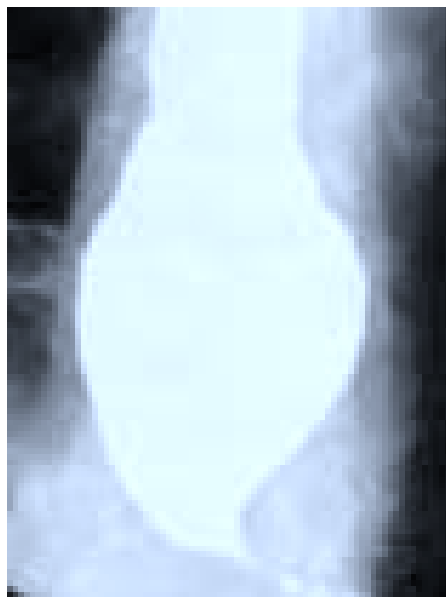Typical symptoms include dysphagia, regurgitation, and chest pain. Other diseases that impair esophageal clearance and/or gastric emptying such as gastroesophageal reflux disease (GERD), esophageal spasm, esophageal carcinoma, and pyloric stenosis may initially present with symptoms similar to those of achalasia. Therefore, before operative therapy is undertaken a thorough evaluation is essential, since laparoscopic Heller myotomy is designed solely to destroy a mechanically defective gastroesophageal sphincter.

### DIAGNOSTIC TESTS

With refractory symptoms of achalasia and in those patients being considered for surgical therapy a host of diagnostic test are considered. Radiographic, endoscopic and physiologic evaluation is performed as part of the complete workup (*Table 1*). Esophageal manometry characterizes the location and tone of the lower esophageal sphincter and rules out other primary esophageal motility disorders by measuring amplitude of esophageal peristalsis, adequacy of propagation of each swallow, and relaxation of the LES. Because achalasia involves the smooth muscle portion of the esophagus, the manometric abnormalities are confined to the distal two-thirds of the esophagus. In the body of the esophagus, aperistalsis is always present. The LES pressure is usually, but not invariably elevated and abnormal LES relaxation is

**TABLE 1**  
DIAGNOSTIC STUDIES

Barium esophagram	<ul style="list-style-type: none"> <li>• “Bird’s break” appearance of the LES with incomplete opening.</li> <li>• Loss of primary peristalsis.</li> <li>• Delayed esophageal emptying.</li> </ul>
Esophageal manometry	<ul style="list-style-type: none"> <li>• Aperistalsis of the esophagus.</li> <li>• Absence of LES relaxation.</li> </ul>
Upper endoscopy	<ul style="list-style-type: none"> <li>• Exclude tumor and/or stricture.</li> </ul>
24 pH testing (optional)	<ul style="list-style-type: none"> <li>• Evaluate competency of LES</li> </ul>



**Figure 1.** Classic “bird’s beak” appearance of distal esophagus.

present in all achalasia patients. Esophagogastroduodenoscopy (EGD) and barium contrast radiographs of the esophagus and stomach help to define anatomic complications such as ulceration, stricture, malignancy, hiatal hernia, or foreshortened esophagus and thus aid in ruling out the diagnosis of pseudoachalasia. Barium esophagram usually will reveal loss of primary peristalsis and tapering of the lower esophagus which often resembles a “bird’s beak” (*Figure 1*). Although not performed routinely, esophageal pH monitoring objectively records the frequency and duration of gastroesophageal reflux, and event recording correlates symptoms with reflux episodes.

### NONOPERATIVE TREATMENT

The majority of achalasia patients are initially managed medically. Patients learn to accommodate to this disorder by using various maneuvers to help empty the esophagus.

phagus which include lifting the neck during swallowing or drinking carbonated beverages. Calcium channel blockers and long acting nitrates are rarely effective in alleviating patient symptoms, but may diminish atypical chest pain. As there is no known cause for the aperistaltic condition of the esophageal musculature, most endoscopic treatments are directed at ablating the non-relaxing lower esophageal sphincter. Many patients initially opt for pneumatic dilation or botulinum toxin injection of the lower esophageal sphincter. However, the effects of these therapies are usually temporary, may render subsequent myotomy more technically difficult and may result in a higher rate of mucosal perforation.<sup>6</sup>

### OPERATIVE TREATMENT

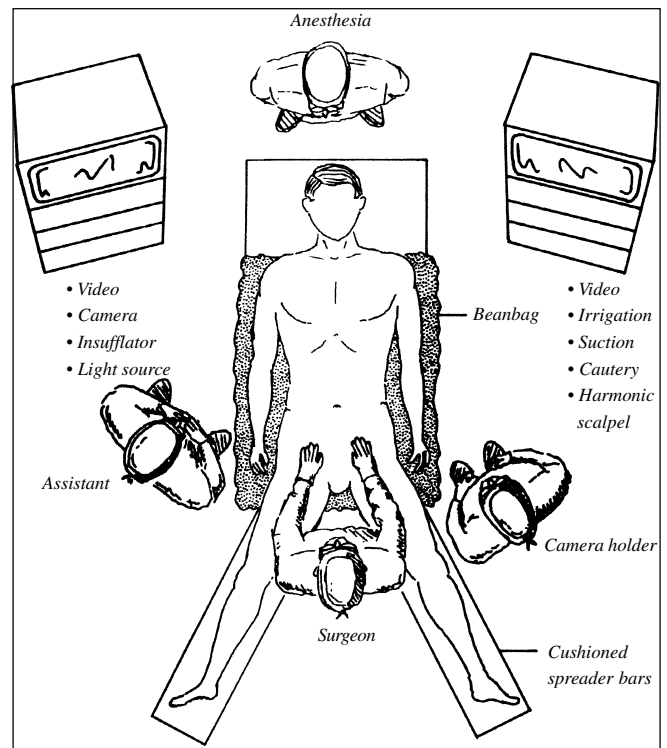
Laparoscopic Heller myotomy is usually recommended for patients with documented idiopathic esophageal achalasia who are young in age, have symptoms unresponsive to endoscopic therapy, or who develop complications. The few absolute contraindications to laparoscopic Heller myotomy include a patient's inability to tolerate general anesthesia or the presence of an uncorrectable coagulopathy. A number of other conditions make laparoscopic Heller myotomy more difficult and should be considered relative contraindications. Prior upper abdominal surgery (especially fundoplication, vagotomy, or gastrectomy) with secondary scarring and adhesion formation may distort anatomy and render the dissection more difficult.

#### Preoperative preparation

A patient of suitable anesthetic risk is admitted the day of surgery after an overnight fast. The bladder is emptied by voiding immediately preoperatively. In the operating room, the patient is placed in a modified lithotomy position on a bean bag cushion (*Figure 2*). After induction of general anesthesia, the stomach is decompressed with an orogastric tube. The arms are tucked and protected at the sides. Pneumatic compression stockings are placed on the lower extremities for deep venous thrombosis prophylaxis. The legs are abducted and supported on cushioned spreader bars.

#### Operation room and patient setup

The operating room personnel and equipment are arranged with the surgeon between the patient's legs, the assistant surgeon on the patient's right, and the ca-

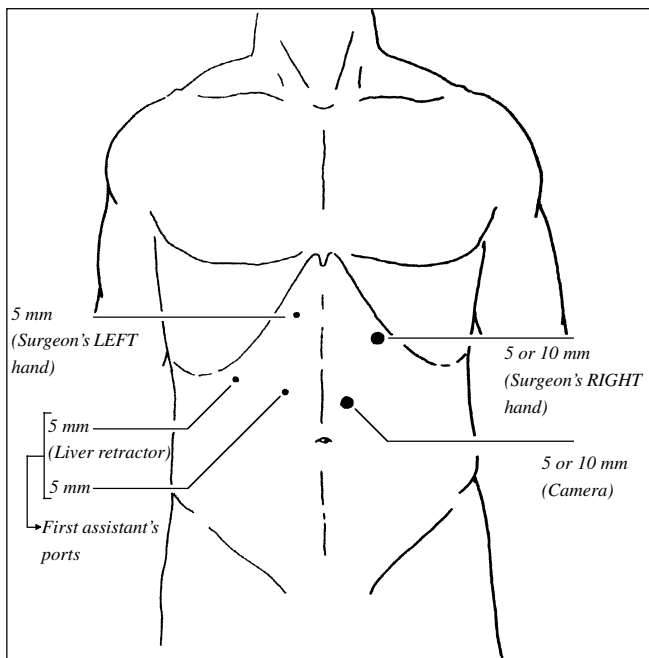


*Figure 2. Operating room layout.*

mera holder to the left. Other surgeons prefer to work from the patient's side for the entire procedure or position the assistant to the patient's left. Video monitors placed at either side of the head of the table can be viewed easily by all members of the operating team. Irrigation, suction, and electrocautery connections come off the head of the table on the patient's right side. Special instruments include endoscopic Babcock graspers, hook cautery, curved dissectors, clip applier, atraumatic liver retractor, 5-mm needle holders and ultrasonic coagulating shears.

#### Surgical technique

**Port placement.** Access to the abdominal cavity is achieved by either a closed or open technique superior to the umbilicus. A port is placed in the left mid-rectus muscle approximately 12 cm below the xiphoid process. The entire abdomen is explored with an angled laparoscope (usually 30-degree oblique) beginning at the area deep to the insertion site. Four additional ports are placed under direct vision of the laparoscope. Ports are typically placed in the following locations to optimize visualization, tissue manipulation, and facilitate suturing (*Figure 3*): right subcostal, 15 cm from the xiphoid process; a point midway between the first two ports in the



**Figure 3.** Port placement.

right mid-rectus region; in the left subcostal region 8 to 10 cm from the xiphoid; and in the right paramedian location at the same horizontal level as the left subcostal trocar (usually 5 cm inferior to the xiphoid process). This port arrangement allows access to the hiatus and permits comfortable suturing by placing the optics between the surgeon's hands. The gastroesophageal junction is usually deep to the xiphoid, and from a point 15 cm distant, only half of the laparoscopic instrument must be introduced to reach the hiatus. With excellent 5 mm equipment and optics, we generally use only one 10-12 port, for the surgeon's right hand, to allow insertion of a SH needle.

**Exposure.** Positioning the patient in reverse Trendelenburg position uses gravity to displace the bowel and stomach from the hiatus. The assistant introduces a self-retaining liver retractor through the right subcostal port, and a Babcock grasper is introduced through the right mid-rectus port to pull the stomach and epiphrenic fat pad inferiorly and to the left. The left triangular ligament is not divided as it aids in retraction of the liver anteriorly. Next, both crura and the anterior vagus nerve are identified after opening the phrenoesophageal ligament.

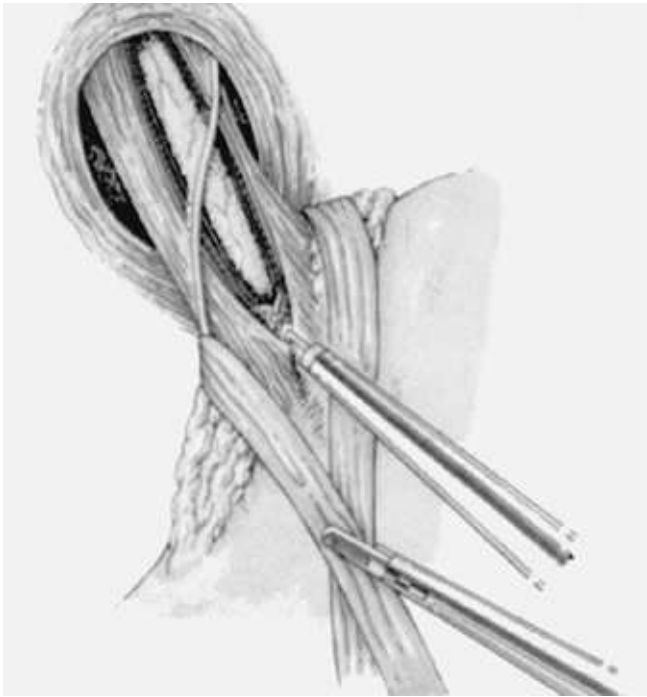**Dissection.** If a hiatal hernia is present, it is reduced into the abdominal cavity with gentle traction after cutting all adhesions to the hernia sac. The right crus is retracted laterally, and the right side of the esophagus is carefully dissected to visualize the aortoesophageal groove and posterior vagus nerve. On

the other side of the esophagus, the left crus is similarly dissected from the esophagus and fundus to its point of origin from the right crural leaflet. A "window" is created between the crura and posterior esophageal wall under direct vision using the angled laparoscope.

The fundus is then fully mobilized by dividing the proximal gastrosplenic ligament. Beginning at a point on the greater curve 8 to 10 cm distal to the esophageal junction, the short gastric vessels are placed on traction and a window is created into the lesser sac. The short gastric vessels are then divided by serial application of the ultrasonic coagulating shears or by clipping and dividing them. To fully mobilize the proximal stomach, all posterior retroperitoneal adhesions to the fundus are divided.

**Esophagomyotomy.** A long myotomy is performed extending up the anterior midline of the esophagus and distal stomach. This is performed by a combination of hook cautery, blunt dissection, and suction dissection (Figure 4). The longitudinal and circular muscles of the distal esophagus are initially divided until the submucosal plane is reached. This dissection is extended 6-7 cm proximally on the esophagus and 1-2 cm distally on the gastric wall.

**Partial fundoplication.** Postoperative gastroesophageal reflux (GERD) following cardiomyotomy is believed to be reduced with the addition of a partial funduplications (anterior or posterior). The frequent occurrence of post-myotomy reflux demonstrated by postoperative pH testing is concerning with reports supporting the need for anti-reflux protection following extensive dissection of the esophageal hiatus or myotomy.<sup>7,8</sup> Following a myotomy, a partial rather than total fundoplication is generally recommended. Despite concerns for long-term durability and recurrent reflux, partial funduplications are used to prevent symptoms of hyper-continenence occasionally associated with Nissen funduplications. Currently, surgeon preference dictates the choice of partial fundoplication. Potential benefits of the different approaches are theoretical. The most common partial fundoplication performed laparoscopically for patients with GERD is the modified 'Toupet' procedure which involves a posterior 270-degree wrap (Figure 5).<sup>9-11</sup> When performed following myotomy, it is hypothesized that the myotomy is held open and a better reflux valve is created as the fundus fills with gastric fluid. The Dor fundoplication, a 180 to 200-degree anterior wrap, has been shown to be a successful alternative in a number of studies.<sup>12</sup> In addition to providing protection following inadvertent perforation during myotomy, the Dor fun-



**Figure 4.** Long myotomy along the anterior, midline of the esophagus (from reference #9, with permission).

doplication requires no posterior esophageal dissection, perhaps decreasing postoperative GERD.

The prevalence of GERD after laparoscopic myotomy and partial fundoplication has been assessed by various groups; however, there is no consensus on the best fundoplication to use for minimizing post-myotomy reflux.

We currently advocate performing a Toupet fundoplication, unless a mucosal perforation occurs. After mobilizing the fundus, a Babcock clamp is passed right to left in front of both crura and behind the esophagus. The Babcock clamp grasps the fundus near the insertion of the short gastric vessels and pulls the fundus left to right around the esophagus. The hiatal defect is closed loosely with several interrupted 0-Ethibond sutures. Retroesophageal exposure of the crura is gained either by using the mobilized fundus to retract the esophagus anteriorly and to the left, or by placing a Penrose drain around the distal esophagus for retraction. The posterior fundoplication is created after the leading edge of the fundus is pulled posterior and to the right of the esophagus. The fundus is sutured to the left crus and to the right side of the cut edge of the myotomy. The anterior fundus is sutured to the left side of the cut edge of the myotomy. The 270-degree fundoplication is secured to the right crus with separate gastro-crural sutures. The surgeon should take generous tissue bites and oppose

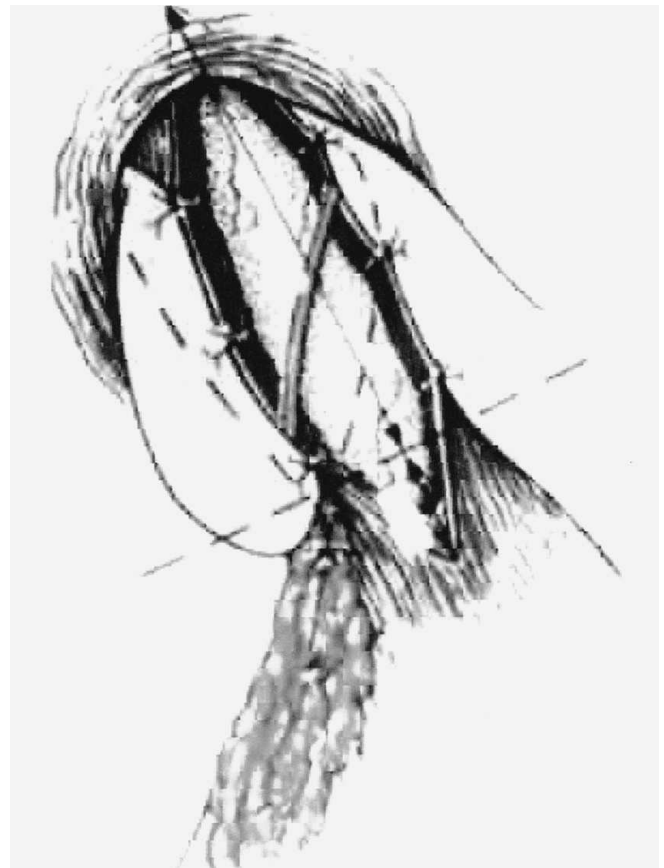the gastric wall to the cut edge of the myotomy and crus without strangulating tissue. Ideally, the wrap should be 2-3 cm in length.

### POSTOPERATIVE CARE

Pneumatic compression stockings are left in place until the patient is awake and ambulating. For the first 24 hours after surgery, patients are given intermittent intravenous ondansetron and ketorolac. Nasogastric tubes are not used. Injectable and/or oral narcotics are administered as needed for pain control. A hypaque swallow study is performed on postoperative day one to rule out leak or anatomic abnormalities. The patient is then advanced to a mechanical soft diet as tolerated for 2-3 weeks while esophageal edema resolves. Most patients are discharged the day after operation.

### COMPLICATIONS

Laparoscopic Heller myotomy and fundoplication is a safe operation when performed by an experienced sur-



**Figure 5.** Partial posterior fundoplication with fundus secured to cut edges of myotomy (from reference #9, with permission).

geon. Although rare, intraoperative complications include gastric or esophageal perforation, liver or splenic injury, short gastric vessel bleeding, and pneumothorax. Directly grasping the esophagus with any instrument should be avoided, due to the risk of esophageal perforation. If a small intraoperative full thickness injury to the esophagus is encountered following myotomy, we recommend primary closure of the mucosa with absorbable suture and coverage with a Dor fundoplication. Since unrecognized perforation of the esophagus is potentially life threatening, this complication should be suspected in any postoperative patient who manifests severe chest pain or signs of infection (fever, pain, tenderness, leukocytosis).

Bleeding from the liver or spleen usually results from retractor or instrument trauma. These injuries are usually recognized at the time of surgery and can be managed with simple pressure or electrocautery. Pleural injuries can also occur during a difficult dissection; however, intervention (tube thoracostomy) is rarely necessary, due to the rapid reabsorption of CO<sub>2</sub>. If a pleural tear occurs and leads to hypotension or increased airway pressure, desufflating the abdomen and then reinsufflating with a lower pressure limit (e.g. 10 mmHg) usually resolves the problem.

## OUTCOMES

The laparoscopic approach results in reduced morbidity and shorter hospitalization when compared to the open

myotomy performed by either laparotomy or thoracotomy.<sup>13</sup> Laparoscopic Heller myotomy is also associated with decreased operative times, decreased rate of conversion to open procedure, and shorter hospital stay when compared with the thoracoscopic approach.<sup>14</sup> In addition, various studies with short to intermediate term follow-up have confirmed that laparoscopic cardiomyotomy results in a marked improvement in symptoms and a high success rate (*Table 2*).<sup>9,15-27</sup> However, long-term outcome of these patients undergoing laparoscopic procedures is still unclear.

Between 1996 and 2002, 84 patients at Washington University School of Medicine underwent laparoscopic Heller myotomy and partial fundoplication (78 Toupet; 6 Dors) for the treatment of achalasia. Following laparoscopic Heller myotomy and fundoplication, patients had minimal postoperative pain, short hospitalization, and fast recovery. Operative time ranged from 2 to 3 hours, with a mean of 2.5 hours. Patients were usually discharged within 24 to 48 hours and returned to work and/or full activity within two weeks of surgery. Mucosal perforation (esophageal/gastric) occurred in 3 patients and was repaired with primary closure. During follow-up, 3 patients required postoperative endoscopic dilation and one required reoperation due to adhesions causing angulation of the gastroesophageal junction. Laparoscopic Heller myotomy provided marked reduction in dysphagia, with minimal complaints of regurgitation, heartburn and chest pain at a mean follow-up of 2 years.

TABLE 2

Reference	Number of patients	Antireflux procedure	Symptom improvement*/success rate (%)	Follow-up (yr) Mean
Hunter <sup>9</sup>	40	yes	90	1.0
Zaninotto <sup>12</sup>	100	yes	92	2.0
Rosati <sup>15</sup>	61	yes	98	1.8
Ancona <sup>16</sup>	17	yes	100	0.7
Esposito <sup>17</sup>	8	yes	100	0.9
Raiser <sup>18</sup>	29	yes	90	1.2
Morino <sup>19</sup>	18	yes	100	0.7
Anselmino <sup>20</sup>	43	yes	95	1.0
Delgado <sup>21</sup>	12	yes	83	0.3
Slim <sup>22</sup>	8	yes	100	1.0
Bonovina <sup>23</sup>	33	yes	97	1.0
Robertson <sup>24</sup>	9	no	88	1.1
Swanstrom <sup>25</sup>	12	yes	100	1.3
Patti <sup>26</sup>	133	yes	93	1.9
Sharp <sup>27</sup>	100	no	93	0.9

\*Good/excellent

## ACKNOWLEDGEMENTS

The authors gratefully acknowledge support from: Washington University Institute for Minimally Invasive Surgery (WUIMIS).

## REFERENCES

- Goyal RK. Disease of the esophagus. In: Fauci A, Braunwald E, Isselbacher K, et al. Harrison's Principles of internal medicine. 14th ed. Mc Graw-Hill; 1998, p. 1590-1.
- Kalrilas PJ. Motility disorders of the esophagus. In: Yamada T, Alpers D, Owyang C, et al (eds.). Textbook of gastroenterology. 3rd ed. Philadelphia: J B Lippincott; 1999, p. 1214-21.
- Ellis FH, Olsen AM, Holman CB, et al. Surgical treatment of cardiospasm (achalasia of the esophagus): considerations of aspects of esophagomyotomy. *JAMA* 1958; 166: 29.
- Pellegrini C, Wetter LA, Patti M, et al. Thoracoscopic esophagomyotomy: initial experience with a new approach for the treatment of achalasia. *Ann Surg* 1992; 216: 291-9.
- Shimi S, Nathanson LK, Cuschieri A. Laparoscopic cardiomyotomy for achalasia. *J R Coll Surg Edinb* 1991; 36(3): 152-4.
- Patti MG, Feo CV, Arcerito M, De Pinto M, Tamburini A, Diener U, Gantert W, Way LW. Effects of previous treatment on results of laparoscopic Heller myotomy for achalasia. *Dig Dis Sci* 1999; 44(11): 2270-6.
- Patti MG, Arcerito M, De Pinto M, Feo CV, Tong J, Gantert W, Way LW. Comparison of thoracoscopic and laparoscopic Heller myotomy for achalasia. *J Gastrointest Surg* 1998; 2(6): 561-6.
- Bowrey DJ, Peters JH. Laparoscopic esophageal surgery. *Surg Clin North Am* 2000; 80.
- Hunter JG, Trus TL, Branum GD, Waring JP. Laparoscopic Heller myotomy and fundoplication for achalasia. *Ann Surg* 1997; 225: 655-65.
- Baigrie RJ, Watson DI, Myers JC, Jamieson GG. Outcome of laparoscopic Nissen fundoplication in patients with disordered preoperative peristalsis. *Gut* 1997; 40: 381-5.
- Lund RJ, Wetcher GJ, Raiser F, et al. Laparoscopic Toupet fundoplication for gastroesophageal reflux disease with poor esophageal body motility. *J Gastrointestinal Surg* 1997; 1: 301-8.
- Zaninotto G, Costantini M, Molena D, Buin F, Carta A, Nicoletti L, Ancona E. Treatment of esophageal achalasia with laparoscopic Heller myotomy and Dor partial anterior fundoplication: prospective evaluation of 100 consecutive patients. *J Gastrointest Surg* 2000; 4(3): 282-9.
- Vaezi MF, Richter JE. Current therapies for achalasia: Comparison and efficacy. *J Clin Gastroenterol* 1998; 27: 121-35.
- Stewart KC, Finley RJ, Clifton JC, Graham AJ, Storseth C, Incelet R. Thoracoscopic versus laparoscopic modified Heller myotomy for achalasia: efficacy and safety in 87 patients. *J Am Coll Surg* 1999; 189(2): 164-9.
- Rosati R, Fumagalli U, Bonavina L, et al. Laparoscopic approach to esophageal achalasia. *Am J Surg* 1995; 169: 424-7.
- Ancona E, Anselmino M, Zaninotto G, et al. Esophageal achalasia: Laparoscopic versus conventional open Heller-Dor operation. *Am J Surg* 1995; 170: 265-70.
- Esposito PS, Sosa JL, Sleeman D, et al. Laparoscopic management of achalasia. *Am Surgeon* 1997; 63: 221-3.
- Raiser F, Perdakis G, Hinder RA, et al. Heller myotomy via minimal access surgery: An evaluation of anti-reflux procedures. *Arch Surg* 1996; 131: 593-8.
- Morino M, Rebecchi F, Festa V, et al. Laparoscopic Heller cardiomyotomy with intraoperative manometry in the management of oesophageal achalasia. *Int Surg* 1995; 80: 332-5.
- Anselmino M, Zaninotto G, Costantini M, et al. One-year follow-up after laparoscopic Heller-Dor operation for esophageal achalasia. *Surg Endosc* 1997; 11: 3-7.
- Delgado F, Bolufer JM, Martinez-Abad M, et al. Laparoscopic treatment of esophageal achalasia. *Surg Lap Endosc* 1996; 2: 83-90.
- Slim K, Pezet D, Chipponi J, et al. Laparoscopic myotomy for primary esophageal achalasia: Prospective evaluation. *Hepato-Gastroenterology* 1997; 44: 11-5.
- Bonovina L, Rosati R, Segalin A, et al. Laparoscopic Heller-Dor operation for the treatment of oesophageal achalasia: Technique and early results. *Ann Chir Gynaecol* 1995; 84: 165-8.
- Robertson GSM, Lloyd DM, Wicks ACB, et al. Laparoscopic Heller's cardiomyotomy without an anti-reflux procedure. *Br J Surg* 1995; 82: 957-9.
- Swanstrom LL, Pennings J. Laparoscopic esophagomyotomy for achalasia. *Surg Endosc* 1995; 9: 286-92.
- Patti MG, Pellegrini CA, Horgan S, Arcerito M, Omelanczuk P, Tamburini A, Diener U, Eubanks TR, Way LW. Minimally invasive surgery for achalasia: an 8-year experience with 168 patients. *Ann Surg* 1999; 230(4): 587-93.
- Sharp KW, Khaitan L, Scholz S, Holzman MD, Richards WO. 100 consecutive minimally invasive Heller myotomies: lessons learned. *Ann Surg* 2002; 235(5): 631-8.