



REVISTA DE GASTROENTEROLOGÍA DE MÉXICO

www.elsevier.es/rgmx



CLINICAL IMAGE IN GASTROENTEROLOGY

Dysphagia lusoria[☆]

Disfagia lusoria

O. Gómez-Escudero*

Clínica de Gastroenterología, Endoscopia Digestiva y Motilidad Gastrointestinal "Endoneurogastro", Hospital Ángeles, Puebla, Puebla, Mexico



Dysphagia lusoria is a term utilized to describe dysphagia secondary to extrinsic vascular compression of the esophagus. The abnormal condition was described in 1794 by David Bayford in a 62-year-old female patient with dysphagia secondary to an aberrant right subclavian artery.¹ It has also been associated with extrinsic compression of the aortic arch or one of its branches, with a prevalence of 0.5–1.8%.^{2,3} The word "lusoria" comes from the Latin phrase *lusus naturae*, which means "freak of nature".³ The diagnostic method is a barium swallow test, and when there is doubt, angiogram. Treatment depends on symptom severity and ranges from dietary modifications and alternating small bolus and liquid swallows to focusing on the cardiovascular disease causing the compression, which can include medical, surgical, or interventional radiology treatment, to obliterate or redirect the aberrant vessel.^{3,4} The case of an 81-year-old woman with intermittent retrosternal dysphagia to solids is presented herein. The videofluoroscopic swallow study shows extrinsic compression exactly at the level of the aortic arch (Fig. 1A and B), consistent with the diagnosis of dysphagia lusoria.

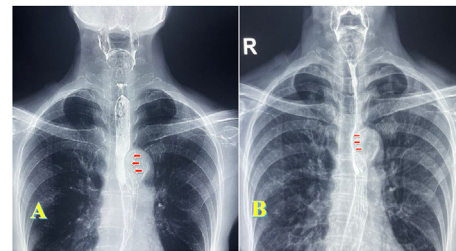


Figure 1 (A) Videofluoroscopic swallow study showing extrinsic esophageal compression at the level of the aortic arch. (B) The same finding, with reduced caliber of barium passage at the level of the aortic arch.

Ethical considerations

The author declares that no experiments were conducted on animals or humans, that the present work maintains patient data anonymity. Informed consent was obtained from the patient for publishing this article. This document is in the possession of the corresponding author, meets the current bioethical research regulations.

Financial disclosure

No financial support was received in relation to this article.

[☆] Please cite this article as: Gómez-Escudero O. Dysphagia lusoria. *Rev Gastroenterol Mex.* 2023;88:429–430.

* Corresponding author at: Clínica de Gastroenterología, Endoscopia Digestiva y Motilidad Gastrointestinal "Endoneurogastro", Hospital Ángeles Puebla, Puebla, Pue, Mexico.

E-mail address: octavio.gomezmd@yahoo.com.mx

Conflict of interest

The author declares that there is no conflict of interest.

References

1. Asherson N, David Bayford. His syndrome and sign of dysphagia lusoria. *Ann R Coll Surg Engl.* 1979;61:63–7. [PMC2494476](#).
2. Carrizo GJ, Marjani MA. Dysphagia lusoria caused by an aberrant right subclavian artery. *Tex Heart Inst J.* 2004;31:168–71. [PMC427379](#).
3. Levitt B, Richter JE. Dysphagia lusoria: a comprehensive review. *Dis Esophagus.* 2007;20:455–60, <http://dx.doi.org/10.1111/j.1442-2050.2007.00787.x>.
4. Bennett AL, Cock C, Heddle R, et al. Dysphagia lusoria: a late onset presentation. *World J Gastroenterol.* 2013;21(19):2433–6, <http://dx.doi.org/10.3748/wjg.v19.i15.2433>.