

^b *División de Gastroenterología y Nutrición Pediátrica, Star Médica Hospital Infantil Privado, Mexico City, Mexico*
^c *División de Genética Humana, Centro Estatal de Cancerología, Chihuahua, Mexico*

*Corresponding author. Hospital Infantil de Especialidades de Chihuahua, Av. Carlos Pacheco, s/n, Chihuahua, Mexico. Tel.: 4332900; Ext.: 22941.
 E-mail address: dr.maciasflores@hotmail.com (J.A. Macias-Flores).

2255-534X/ © 2023 Published by Masson Doyma México S.A. on behalf of Asociación Mexicana de Gastroenterología. This is an open access article under the CC BY-NC-ND license (<http://creativecommons.org/licenses/by-nc-nd/4.0/>).

Atypical presentation in adolescence of a gastroesophageal junction adenocarcinoma[☆]



Presentación atípica en la adolescencia de un adenocarcinoma de la unión esofagogástrica

Gastroesophageal junction adenocarcinoma (GEJA) accounts for 0.05% of pediatric malignant gastrointestinal tumors.¹ The common age at presentation is above 50 years, and so its appearance in children and adolescents is extremely rare.²

There are very few case reports in pediatric patients,¹ and they are listed in Table 1. Staging and treatment in that population is based on those established for adults. Prognosis is usually poor, given that those tumors in children are often poorly differentiated, and because the disease is largely unsuspected, it is diagnosed in advanced stages with metastasis, resulting in a mortality rate close to 100%. Thus, cases of dysphagia in children should potentially be studied.^{1,3}

Due to the low presentation frequency of the tumor, its causes are not yet well defined.⁴ They have been related to certain risk factors in adults, such as smoking, alcohol use, fatty food and red meat consumption, A blood type, as well as Epstein-Barr virus infection and *Helicobacter pylori* infection, with the vacAs1-, vacAm1-, cagA-positive genotypes; those infections are potentiated in patients that are carriers of the cytokine gene polymorphisms, such as IL-1B-511*T/*T or IL-1B-511*T/*C. Cases are most likely *de novo* in children but germline mutations in E-cadherin, with an autosomal dominant inheritance pattern, must not be ruled out, which if present, can be a treatment target.²

Dysphagia is the most prevalent symptom, followed by weight loss, anemia, dehydration, nausea, epigastric or retrosternal pain, regurgitation, and hematemesis.⁴

In 1996, Siewert et al. proposed a classification based on the definition of GEJA, which is a neof ormation that grows within 5 cm of the cardia, in a distal or proximal direction, and that is divided into 3 subtypes:

- Type I: adenocarcinoma of the distal esophagus, extending 1 to 5 cm above the junction.
- Type II: adenocarcinoma of the cardia; “junctional carcinoma”, extending 1 cm above and 2 cm below the junction.
- Type III: subcardial gastric carcinoma, extending 2 to 5 cm below the junction.⁵

In the past, standard treatment was open surgical resection with negative margins. Currently, tumors that only affect the mucosa (T1a) can be treated through endoscopic resection.⁶ In patients with locally advanced disease (T3 or T4), perioperative chemotherapy and radiotherapy significantly improve survival.⁷ Treatment with epirubicin, cisplatin, and 5-fluorouracil have increased survival by 36%, compared with the 23% in patients treated only through surgery.⁸

A 15-year-old boy was seen at the outpatient service of the *Hospital Central del Estado de Chihuahua*. He had a medical history of 4 months of progressive dysphagia, anemia syndrome, and weight loss. He was hospitalized, with Hb of 5.5 g/dl, MCV of 74 fl, MCH of 24 pg, and platelets of 500 × 10³/ul. He underwent transfusion with two units of red blood cells and then had an upper endoscopic examination. Retroflexion during the upper endoscopy revealed a tumor in the cardia, 6 cm from the mucosa. Its aspect was adenomatous and friable, and it bled during the insufflation. The tumor extended into the lesser curvature and the inferior third of the esophagus, partially obstructing the lumen (Fig. 1), and corresponded to a type II GEJA, according to Siewert. A tomography scan of the chest and abdomen identified a 5.7 × 2.6 cm infiltrative gastric tumor, with perigastric lymph node invasion, that had clinical staging (cTNM) of T3, N2, M0 (Fig. 2). The histopathologic findings through immunohistochemistry were a moderately differentiated adenocarcinoma, with invasion of the stroma, no microsatellite instability, integral DNA repair protein expression, and null p53 expression. The patient underwent preoperative chemotherapy administra-

Table 1 Cases of GEJA reported in children and adolescents

Author	Year	Number of cases reported	Age
Elliott MJ ³	1983	1 male	14 years
Sasaki H ¹	1999	1 female	11 years
Subbiah V ²	2011	1 male	17 years

[☆] Please cite this article as: Amaya Villagrán G, Loya Lazcano KM, Baeza Zapata AA. Presentación atípica en la adolescencia de un adenocarcinoma de la unión esofagogástrica. *Rev Gastroenterol Méx.* 2023;88:299–301.

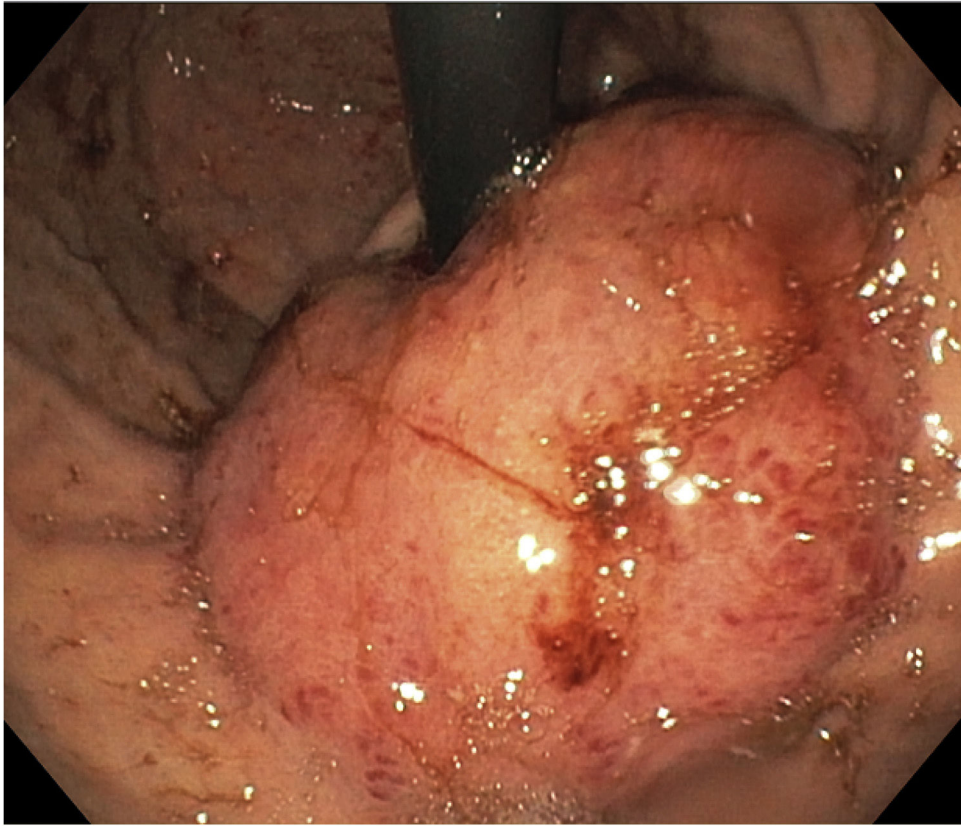


Figure 1 Tumor in the cardia extending into the inferior third of the esophagus, seen by retroflexion during upper endoscopy.

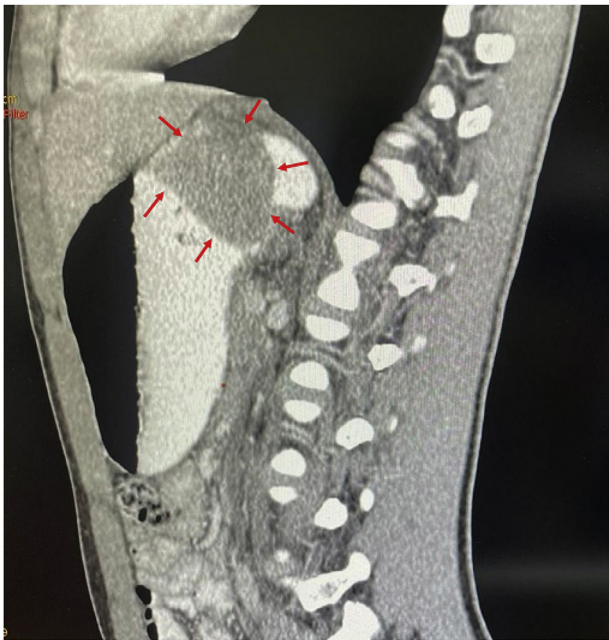

Figure 2 Sagittal view of a computed tomography scan, with oral and intravenous contrast media, showing a cardia-dependent tumor occupying the gastric fundus.

tion with fluorouracil, leucovorin, oxaliplatin, and docetaxel (FLOT). Four months ago, he underwent total gastrectomy, extended with transhiatal resection of the esophagus, and retromesocolic Roux-en-Y reconstruction. After the surgery,

the patient was given 4 more chemotherapy cycles with the FLOT regimen and currently is undergoing radiotherapy, with good response.

With our report of this case and the review of the literature, our aim was to favor the general understanding of these rare pediatric tumors and promote their diagnostic suspicion in a patient that presents with a history of dysphagia, weight loss, and anemia.

Ethical considerations

The authors declare that this article contains no personal information that can identify the patient. All protocols according to the ethics committee of the *Hospital Central del Estado* were followed, with respect to preserving patient privacy. A written statement of informed consent was not requested, given that no personal information was used that could identify the patient and the photographs showed no personal data. Even so, the patient and mother gave their verbal consent for the publication of this case.

Financial disclosure

No financial support was received in relation to this article.

Conflict of interest

The authors declare that there is no conflict of interest.

References

1. Sasaki H, Sasano H, Ohi R, et al. Adenocarcinoma at the esophageal gastric junction arising in an 11-year-old girl. *Pathol Int.* 1999;49:1109–13, <http://dx.doi.org/10.1046/j.1440-1827>.
2. Subbiah V, Varadhachary G, Herzog CE, et al. Gastric adenocarcinoma in children and adolescents. *Pediatr Blood Cancer.* 2011;57:524–7, <http://dx.doi.org/10.1002/pbc.23051>.
3. Elliott MJ, Ashcroft T. Primary adenocarcinoma of the gastro-oesophageal junction in childhood. A case report. *Scand J Thorac Cardiovasc Surg.* 1983;17:65–6, <http://dx.doi.org/10.3109/14017438309102382>.
4. Theilen TM, Chou AJ, Klimstra DS, et al. Esophageal Adenocarcinoma and Squamous Cell Carcinoma in Children and Adolescents: Report of 3 Cases and Comprehensive Literature Review. *J Pediatr Surg Case Rep.* 2016;5:23–9, <http://dx.doi.org/10.1016/j.epsc.2015.12.008>.
5. Pastina M, Menna C, Andreotti C, et al. The esophagogastric junctional adenocarcinoma an increasing disease. *J Thorac Dis.* 2017;9:1455–8, <http://dx.doi.org/10.21037/jtd.2017.05.70>.
6. Pericay C, Macías-Declará I, Arrazubi V, et al. Treatment in esophagogastric junction cancer: past, present and future. *Cir Esp (Engl Ed).* 2019;97:459–64, <http://dx.doi.org/10.1016/j.cireng.2019.03.020>.
7. Okereke IC. Management of gastroesophageal junction tumors. *Surg Clin North Am.* 2017;97:265–75, <http://dx.doi.org/10.1016/j.suc.2016.11.004>.
8. Cunningham D, Allum WH, Stenning SP, et al. Perioperative chemotherapy versus surgery alone for resectable gastroesophageal cancer. *N Engl J Med.* 2006;355:11–20, <http://dx.doi.org/10.1056/NEJMoa055531>.

G. Amaya Villagrán^a, K.M. Loya Lazcano^a, A.A. Baeza Zapata^{b,*}

^a *Servicio de Medicina Interna, Hospital Central del Estado de Chihuahua «Jesús Enrique Grajeda Herrera», Chihuahua, Chihuahua, Mexico*

^b *Departamento de Gastroenterología y Endoscopia Digestiva, Servicio de Medicina Interna, Hospital Central del Estado de Chihuahua «Jesús Enrique Grajeda Herrera», Chihuahua, Chihuahua, México*

* Corresponding author at. Calle Rosales 3302 Colonia Obrera C.P. 31350 Chihuahua, Chihuahua, Mexico. Tel.: 6145630009. E-mail address: armando-baeza@outlook.com (A.A. Baeza Zapata).

2255-534X/ © 2023 Asociación Mexicana de Gastroenterología. Published by Masson Doyma México S.A. This is an open access article under the CC BY-NC-ND license (<http://creativecommons.org/licenses/by-nc-nd/4.0/>).

Dieulafoy's lesion of the rectum: A case report[☆]



Lesión de Dieulafoy en el recto: reporte de un caso

A 31-year-old woman, whose only relevant past medical history was scoliosis, treated with meloxicam, carisoprodol, and dexamethasone for 15 years, was admitted to the emergency room due to 16 episodes of hematochezia in 24h, asthenia, adynamia, and generalized weakness. Upon admission, her vital signs were normal, except for tachycardia of 100 bpm. Physical examination revealed skin pallor, uncompromised cardiopulmonary function, and abdomen with no signs of peritoneal irritation. The rectal examination identified no active bleeding, hemorrhoids, or palpable tumor; remnants of blood were on the examination glove when exiting the rectum; and there was immediate capillary refill. Laboratory study results were hemoglobin 8.9 g/dl, hematocrit 28.8%, mean erythrocyte volume 77.6 fl, platelets $259 \times 10^3/\mu\text{l}$, leukocytes $4.69 \times 10^3/\mu\text{l}$, INR 1.02, creatinine 0.7 mg/dl, sodium 143, potassium 4.2, and chloride 109.

Colonoscopy revealed a protruding 4-5 mm vascular lesion that was 5 cm from the anal verge, in the region of the rectum, normal mucosa, and no ulcerations (Fig. 1A and

B). No hemorrhoidal disease was viewed during retroflexion. The examination reached the transverse colon, showing no other alterations. Band ligation was applied on the Dieulafoy's lesion with no complications (Fig. 2A and B). The day after the procedure, the patient's progression was adequate, she was hemodynamically and clinically stable, and her vital signs were within normal limits. Upon physical examination, there were no remnants of blood on the examining glove when removed from the rectum after the digital rectal exam. The patient was discharged to her home with an open emergency room appointment in case of any alarm symptoms. The patient presented with no rebleeding at follow-up.

Dieulafoy's lesion was first described by Gallard in 1884 and then defined by the French surgeon, Paul Georges Dieulafoy, in 1898, naming it "exulceratio simplex".¹ It is a vascular anomaly of the gastrointestinal tract that consists of the presence of a submucosal vessel, with an abnormally dilated diameter of up to 3 mm that erodes into the mucosa, in the absence of a previous ulcer, causing a small defect in the wall, with fibrinoid necrosis at the base; the rest of the mucosa is intact.²

Dieulafoy's lesion is a rare cause of gastrointestinal bleeding, with an incidence of up to 5%. Given its arterial nature, it can be life-threatening. In a Mexican case series, 50% of patients presented with hemodynamic instability.^{3,4}

The etiology and pathophysiology of Dieulafoy's lesion are not well understood. The most widely accepted theory is that an ischemic lesion caused by atrophy and a tear in the mucosa leads to disruption of the overlying epithelium, with the subsequent exposure of a submucosal vessel to the intestinal content that results in mechanical and chem-

[☆] Please cite this article as: Martínez-Ortiz CA, Alvarez-Sores ED, Lara-Orozco U, Murcio-Pérez E. Lesión de Dieulafoy en el recto: reporte de un caso. *Rev Gastroenterol Méx.* 2023;88:301–304.