

C.E. Alcántara-Figueroa<sup>a,b,\*</sup>, D.C. Calderón-Cabrera<sup>b</sup>,  
E.F. Estela-Vásquez<sup>b</sup>, E.F. Coronado-Rivera<sup>a,d</sup>,  
C.A. Calderón-De la Cruz<sup>c</sup>

<sup>a</sup> Escuela de Medicina, Universidad Privada Antenor  
Orrego, Trujillo, La Libertad, Peru

<sup>b</sup> Servicio de Gastroenterología, Hospital Belén, Trujillo,  
La Libertad, Peru

<sup>c</sup> Servicio de Patología, Hospital Nacional Arzobispo  
Loayza, Cercado de Lima, Lima, Peru

<sup>d</sup> Servicio de Anestesiología, Hospital Belén de Trujillo,  
Trujillo, La Libertad, Peru

\* Corresponding author.

E-mail address: [christian378@hotmail.com](mailto:christian378@hotmail.com)

(C.E. Alcántara-Figueroa).

## Severe gastroduodenitis due to *Strongyloides stercoralis* infection: An unusual cause of intestinal obstruction



### Gastroduodenitis severa por *Strongyloides stercoralis*: una causa rara de obstrucción intestinal

*Strongyloides stercoralis* (*S. stercoralis* or *Ss*) is an intestinal nematode that is highly prevalent in tropical regions of Africa, Asia, and South America<sup>1</sup>. Approximately 50-100 million individuals are infected worldwide, particularly in Brazil and Thailand, with a prevalence of 13% and 23.7%, respectively<sup>2</sup>. The majority of infected persons are asymptomatic, but some, especially immunocompromised individuals, have severe manifestations<sup>3-5</sup>.

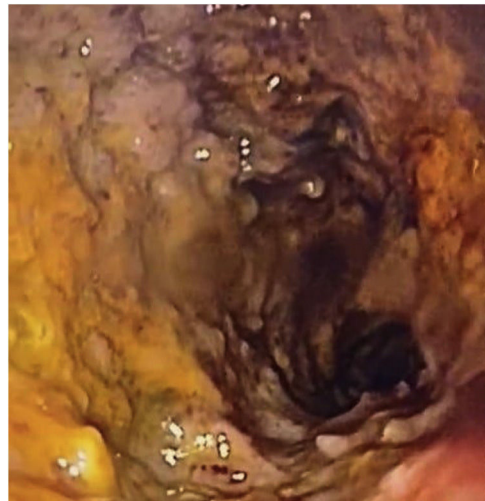A 16-year-old male from Tabatinga, in the Brazilian state of Amazonas, sought medical attention at a hospital in Leticia, due to the 3-week progression of fever, epigastric abdominal pain radiating to the right iliac fossa, excessive vomiting, bloody diarrhea, and weight loss (20 kg). Laboratory work-up results were leukocytosis (20,600/mm<sup>3</sup>), neutrophilia (17,922/ $\mu$ l), and thrombocytosis (610,000/ $\mu$ l); human immunodeficiency virus was negative; and *Ss* was detected in stool, for which the patient received ambulatory treatment with a subtherapeutic dose of albendazole.

His fever persisted and the patient had bilious vomiting and increased abdominal pain at one week of treatment. He went to the emergency room, where signs of peritoneal irritation were documented. An exploratory laparotomy was performed, revealing an indurated retrocecal appendix that was then resected.

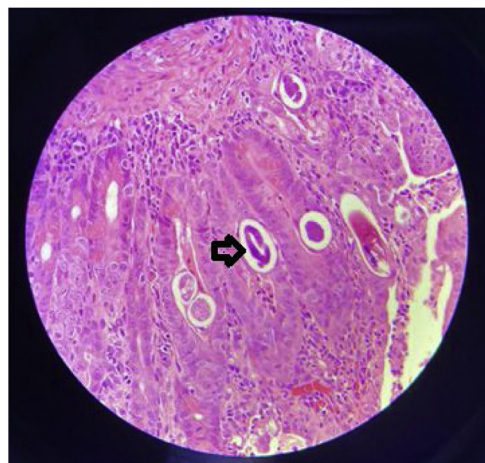
Nevertheless, the patient continued to present with fever, excessive vomiting, and a lack of bowel movements for one week. He was referred to the *Hospital Internacional de Colombia* (HIC) on day 10 of his hospitalization.

The patient was in poor general condition and hemodynamically unstable. He also presented with high bilioenteric output through the nasogastric tube and had signs of peritoneal irritation. Anthropometry revealed weight of 39 kg (P0, -3.10 SD), height of 150 cm (P0, -2.9 SD), and BMI of 17.3 kg/m<sup>2</sup> (P6, -1.5 SD). The patient required

vasoactive support (norepinephrine). Severe anemia was reported (Hb: 7g/dl) and he underwent red blood cell transfusion. Contrast abdominal tomography identified generalized distension of the small bowel segments and thickening of the duodenal wall. Panendoscopy revealed severe erosive gastroduodenitis, pseudomembranes, and multiple inflammatory pseudopolyps in the duodenal bulb (Fig. 1). The histologic study reported severe gastroduodenitis due to *Ss* (Fig. 2). Management with ivermectin 200  $\mu$ g/kg/day, oral albendazole 800 mg/day, and endove-



**Figure 1** Edematous mucosa with a nodular pattern, erythema, and ulcers of the duodenal bulb can be seen.



**Figure 2** Fragments of *Strongyloides stercoralis* larvae (arrow).

☆ Please cite this article as: Cuadros-Mendoza CA, Lozano-Agudelo K, Otoyca-Castrillon JP, Serrato-Roa F, Navarro-Mejia YA. Gastroduodenitis severa por *Strongyloides stercoralis*: una causa rara de obstrucción intestinal. *Rev Gastroenterol Méx.* 2023;88:188-190.

nous piperacillin/tazobactam 80 mg/kg/dose every 6 hours, all for 14 days, was indicated. Larvae were expelled during 13 treatment days. Stool exam was positive for *Ss*. Tests for hepatitis B, hepatitis C, cytomegalovirus, and Epstein-Barr virus were negative. Human-T lymphotropic virus type 1 (HTLV-1) had a signal-to-cutoff (S/CO) value of 173.210 (normal: < S/CO value of 1). No ocular involvement was found in the ophthalmologic evaluation. An echocardiogram showed mild dysfunction of the left ventricle and dyskinesia of the basal septum. Blood culture at admission and the control culture at 2 weeks were negative.

The patient presented with improved signs of ileus on day 10 and complete tolerance of oral diet on day 14. Stool exams were negative after 2 weeks of treatment, with nutritional recovery (reaching 44 kg). He was discharged from the hospital after 2 months.

*Ss* has a complex life cycle, with the capacity to exist and replicate in the host for decades because the larvae mature in the gastrointestinal tract and invade the perianal skin, completing the autoinfection cycle<sup>6</sup>.

*Ss* has 4 clinical presentations: a) acute strongyloidiasis: presentation includes rash at the site of penetration of the larvae, cough, wheezing, low-grade fever, epigastric tenderness, diarrhea, nausea or vomiting<sup>7</sup>; b) chronic strongyloidiasis: it is usually asymptomatic but can cause abdominal pain, nausea, vomiting, diarrhea, malabsorption syndrome, paralytic ileus, rash or larva currens (serpiginous, erythematous papules that rapidly progress) in the perianal area and thighs<sup>8</sup>; c) hyperinfection: it occurs when there is a high parasite load and is predominantly seen in endemic zones. It is limited to the gastrointestinal tract and lungs (accelerated autoinfection cycle). Its main presentation is diarrhea that is generally high output and occasionally dysenteric, associated with abdominal pain and vomiting. Paralytic ileus, malabsorption, hypoalbuminemia, edema, weight loss and/or massive alveolar hemorrhage are seen in advanced phases<sup>7,8</sup>; and d) disseminated disease: evidence of larval migration to sites outside of the parasitic replication cycle, finding larvae in the central nervous system, liver, kidney, and other organs<sup>4-6</sup>.

The main risk factor for hyperinfection or dissemination is cellular immunosuppression that is generally secondary (e.g., steroid use). Our patient presented with symptoms of intestinal obstruction secondary to severe gastroduodenitis due to a hyperinfection syndrome. He had not received steroids, but nevertheless presented with several risk factors, such as place of residence, malnutrition, and HTLV-1 infection (said virus decreases Th2 lymphocytes, eosinophils, mastocytes, and several interleukin mediators of the immune response to parasites)<sup>8</sup>.

Treatment should be aggressive, because without it, the mortality rate approaches 100%. Ivermectin, at a dose of 200 mcg/kg/day, is the medication of choice<sup>9</sup>. The definitive length of treatment duration has yet to be defined, but prolonged regimens of one to 2 weeks are indicated for immunocompromised patients, to prevent relapses<sup>9</sup>. Thiabendazole or albendazole is utilized as second-line treatment<sup>10</sup>. The combination of ivermectin and thiabendazole, until the absence of parasites in stool exams is achieved or there is improvement of ileus, has been suggested<sup>10</sup>. The addition of antibiotics to act against Gram-negative or anaerobic microbes that cause sepsis due to

bacterial translocation is also recommended. Due to the severity of our patient's clinical picture, we combined ivermectin, albendazole, and piperacillin/tazobactam. Thiabendazole was not considered for use due to its poor safety profile. Treatment was extended up to 14 days, because even though the patient showed signs of intestinal transit at day 10, the exit of larvae persisted up to treatment day 13.

In conclusion, the early diagnosis of *Ss* hyperinfection requires a high level of clinical suspicion and the disease should be included in the differential diagnosis of patients with intestinal obstruction that live in endemic areas and/or are immunocompromised.

## Ethical considerations

A written statement of informed consent was requested from the patient's mother to publish patient data and images. We declare that this article contains no personal information that could identify the patient.

**Data confidentiality.** The authors declare that they have followed the protocols of their work center on the publication of patient data.

**Right to privacy and informed consent.** The authors declare that no patient data appear in this article.

## Financial disclosure

No financial support was received in relation to this article.

## Authorship

All the authors contributed to the conception and design of the work, data acquisition, the critical review of the intellectual content, and the definitive approval of the version presented herein.

## Conflict of interest

The authors declare that there is no conflict of interest.

## References

1. Krolewiecki A, Nutman TB. Strongyloidiasis: a neglected tropical disease. *Infect Dis Clin North Am.* 2019;33:135–51, <http://dx.doi.org/10.1016/j.idc.2018.10.006>.
2. Schär F, Trostorf U, Giardina F, et al. *Strongyloides stercoralis*: global distribution and risk factors. *PLoS Negl Trop Dis.* 2013;7:1–18, <http://dx.doi.org/10.1371/journal.pntd.0002288>.
3. Mohamed R, Hamodat MM, Al-Abadi MA. Gastric strongyloidiasis: report of 2 cases and brief review of the literature. *Lab Med.* 2017;48:93–6, <http://dx.doi.org/10.1093/labmed/lmw041>.
4. Vásquez-Ríos G, Pineda-Reyes R, Pineda-Reyes J, et al. *Strongyloides stercoralis* hyperinfection syndrome: a deeper understanding of a neglected disease. *J Parasit Dis.* 2019;43:167–75, <http://dx.doi.org/10.1007/s12639-019-01090-x>.
5. Geri G, Rabbat A, Mayaux J, et al. *Strongyloides stercoralis* hyperinfection syndrome: a case series and a review of the literature. *Infection.* 2015;43:691–8, <http://dx.doi.org/10.1007/s15010-015-0799-1>.

6. Gómez-Hinojosa P, García-Encinas C, Carlin-Ronquillo A, et al. Infección por *Strongyloides* imitando enfermedad inflamatoria intestinal. *Rev Gastroenterol Mex.* 2020;85:366–8, <http://dx.doi.org/10.1016/j.rgmx.2019.08.004>.
  7. Ahmadpour E, Ghanizadegan MA, Razavi A, et al. *Strongyloides stercoralis* infection in human immunodeficiency virus-infected patients and related risk factors: a systematic review and meta-analysis. *Transbound Emerg Dis.* 2019;66:2233–43, <http://dx.doi.org/10.1111/tbed.13310>.
  8. Tariq H, Kamal Mu, Reddy P, et al. Anemia, intractable vomiting, chronic diarrhea, and syndrome of inappropriate antidiuretic secretion: a diagnostic dilemma: disseminated strongyloidosis in a patient with newly diagnosed HTLV infection-case report and review of literature. *Medicine (Baltimore).* 2017;96:e9229, <http://dx.doi.org/10.1097/MD.0000000000009229>.
  9. Krishnan S, Barger G, Chandrasekar P. Recurrent *Strongyloides stercoralis* hyperinfection syndrome. Case report and a brief review. *Infect Dis Clin Pract.* 2006;14:240–3, <http://dx.doi.org/10.1097/01.idc.0000205842.97644.c1>.
  10. Igual-Adell R, Oltra-Alcaráz C, Soler-Company E, et al. Efficacy and safety of ivermectin and thiabendazole in the treatment of strongyloidiasis. *Expert Opin Pharmacother.* 2004;5:2615–9, <http://dx.doi.org/10.1517/14656566.5.12.2615>.
- C.A. Cuadros-Mendoza<sup>a,\*</sup>, K. Lozano-Agudelo<sup>a</sup>, J.P. Otoyca-Castrillon<sup>b</sup>, F. Serrato-Roa<sup>a</sup>, Y.A. Navarro-Mejia<sup>c</sup>
- <sup>a</sup> *Departamento de Salud Digestiva Pediátrica, Complejo Médico Fundación Cardiovascular de Colombia - Hospital Internacional de Colombia*  
<sup>b</sup> *Departamento de Cirugía Pediátrica, Complejo Médico Fundación Cardiovascular de Colombia - Hospital Internacional de Colombia*  
<sup>c</sup> *Departamento de Patología, Complejo Médico Fundación Cardiovascular de Colombia - Hospital Internacional de Colombia*
- \* Corresponding author. Hospital Internacional de Colombia, Km 7 Autopista Bucaramanga - Piedecuesta Valle de Menzuli. Tel.: (+57) 3173769314.  
E-mail address: [carloscuadros17@gmail.com](mailto:carloscuadros17@gmail.com) (C.A. Cuadros-Mendoza).