

6. Iwamuro M, Kondo E, Takata K, et al. Diagnosis of follicular lymphoma of the gastrointestinal tract: a better initial diagnostic workup. *World J Gastroenterol*. 2016;22:1674–83, <http://dx.doi.org/10.3748/wjg.v22.i4.1674>.
7. Fujiya M, Kashima S, Ikuta K, et al. Decreased numbers of vascular networks and irregular vessels on narrow-band imaging are useful findings for distinguishing intestinal lymphoma from lymphoid hyperplasia. *Gastrointest Endosc*. 2014;80:1064–71, <http://dx.doi.org/10.1016/j.gie.2014.03.030>.
8. Zhu Q-Q, Zhu W-R, Wu J-T, et al. Comparative study of intestinal tuberculosis and primary small intestinal lymphoma. *World J Gastroenterol*. 2014;20:4446–52, <http://dx.doi.org/10.3748/wjg.v20.i15.4446>.
9. Watanabe T. Treatment strategies for nodal and gastrointestinal follicular lymphoma: Current status and future development. *World J Gastroenterol*. 2010;16:5543–54, <http://dx.doi.org/10.3748/wjg.v16.i44.5543>.

C.E. Alcántara-Figueroa<sup>a,b,\*</sup>, H.D. Valencia-Mariñas<sup>a,c</sup>,  
C.I. León-Vega<sup>c</sup>, E.F. Coronado-Rivera<sup>a,d</sup>,  
E.F. Estela-Vásquez<sup>b</sup>

<sup>a</sup> *Escuela de Medicina, Universidad Privada Antenor Orrego, Trujillo, Peru*

<sup>b</sup> *Departamento de Gastroenterología, Hospital Belén, Trujillo, La Libertad, Peru*

<sup>c</sup> *Departamento de Cirugía Oncológica, Instituto Regional Enfermedades Neoplásicas, Trujillo, La Libertad, Peru*

<sup>d</sup> *Departamento de Anestesiología, Hospital Belén, Trujillo, La Libertad, Peru*

\* Corresponding author at: Urb. Las Flores del Golf Mz A Lote 15, Dpto 202, Víctor Larco Herrera, Trujillo, La Libertad, Peru. Tel.: +51969672075.

E-mail address: [christian378@hotmail.com](mailto:christian378@hotmail.com) (C.E. Alcántara-Figueroa).

2255-534X/ © 2022 Asociación Mexicana de Gastroenterología. Published by Masson Doyma México S.A. This is an open access article under the CC BY-NC-ND license (<http://creativecommons.org/licenses/by-nc-nd/4.0/>).

## Weil's disease as a differential diagnosis of jaundice: A case report<sup>☆</sup>



### Enfermedad de Weil como diagnóstico diferencial en síndrome icterico: reporte de un caso

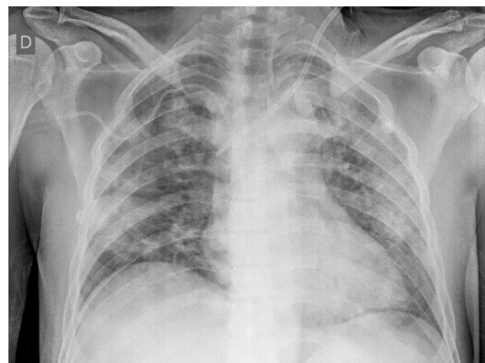
A 64-year-old man with no comorbidities presented with symptoms for 7 days of jaundice, asthenia, fever, calf muscle pain, mild upper abdominal pain, and reduced urine output. Upon admission to a hospital in Lima, Peru, he was hemodynamically stable, had a score of 15 on the Glasgow coma scale, and had slight abdominal pain in the right hypochondrium and epigastrium. Laboratory work-up reported hemoglobin at 11.8 g/dL, leukocytes at 19,800, platelets at 30,000, urea at 206, creatinine at 5.7, amylase at 684 (normal value < 110 U/L), lipase at 1,283 (normal value < 300 U/L), and altered liver profile (Table 1). Chest x-ray was normal. No gallstones or bile duct alterations were identified in the abdominal ultrasound study.

The initial diagnostic focus was acute kidney failure secondary to severe acute pancreatitis and probable severe cholangitis. Treatment was started with fluid resuscitation, ceftriaxone, and intravenous metronidazole. The next day the patient was admitted to the intensive care unit. An abdominal tomography scan revealed no significant alterations in the pancreas or liver and the antibiotic was changed to intravenous meropenem for 14 days. Due to the presence of fever, calf muscle pain, marked direct bilirubinemia and no other alterations in the liver profile, and imaging studies that were negative for biliary, pancreatic, or neoplastic disease, an infectious etiology was suspected. Upon broad-

ening the clinical history, it was discovered that the patient had been exposed to rodents, when cleaning a water cistern, 2 weeks prior to his hospital admission. A microscopic agglutination test was performed due to high suspicion of leptospirosis, confirming the diagnosis. Urea and creatinine levels continued to increase, and so hemodialysis was started on day 3. Liver involvement also worsened (Table 1).

One week later, the patient showed improved liver involvement but continued to undergo hemodialysis and developed respiratory failure due to diffuse alveolar hemorrhage (Fig. 1), with a drop in hemoglobin to 5 g/dL. He was given supplemental oxygen through a face mask with a reservoir bag and did not require mechanical ventilation. The patient finally presented with favorable progression and was discharged on day 31 of hospitalization, continuing hemodialysis as an outpatient.

Leptospirosis is a zoonotic infection with worldwide distribution, that is produced by spirochetes from the genus *Leptospira*. It predominates in tropical regions, especially during the rainy season, in areas with scant resources and the presence of rodents.<sup>1</sup> In Peru, an incidence of 1.55 to 7.11 cases per 100,000 inhabitants was reported for the period from 2017 to 2021.<sup>2</sup> In 2021, an additional 513 cases



**Figure 1** Chest x-ray taken on hospitalization day 6: diffuse alveolar pattern.

<sup>☆</sup> Please cite this article as: Flores LE, Carlin A, García CA. Enfermedad de Weil como diagnóstico diferencial en síndrome icterico: reporte de un caso. *Rev Gastroenterol Méx*. 2023;88:78–80.

**Table 1** Liver profile.

	Day 1	Day 4	Day 6	Day 8	Day 10	Day 14	Day 17	Day 28
Total bilirubin (mg/dL)	22.4	40.2	49.3	43.5	36.5	24.9	6.6	3.0
Direct bilirubin (mg/dL)	20.9	36.8	44.8	40.3	33.6	23.6	5.6	2.4
AST (U/L)	263	172	114	101	83	61	62	48
ALT (U/L)	126	132	95	69	49	33	26	57
ALP (U/L)	186	235	325	384	356	–	–	283
GGT (U/L)	132	245	308	369	293	–	–	75
Albumin (g/dL)	2.7	–	–	–	2.4	–	–	–

and one death were reported. Approximately 80% of the cases were reported by the departments of Madre de Dios and Loreto (jungle), whereas Lima (coast) reported less than 1.5%.<sup>2</sup> The patient described herein was from Lima.

*Leptospira* is maintained in nature due to chronic kidney infection in domestic and wild carriers (rodents, among other small mammals, as well as cattle and domestic dogs and cats) that colonize the brush border of the proximal renal tubule.<sup>1</sup>

Infection can be produced through direct or indirect contact with the urine or tissues of infected animals. *Leptospira* spirochetes enter the organism through cuts or abrasions in the skin, through the mucous membranes, or through the inhalation of aerosols, and are disseminated in the blood. Leptospirosis and the associated vasculitis explain the broad spectrum of its clinical presentation.<sup>3</sup>

The incubation period is 10 days (5–14 days). Leptospirosis can present as a subclinical disease, a self-limited systemic disease (90% of infections), or a severe disease. It can involve 2 phases: an initial septicemic phase in the first 5–7 days, characterized by the presence of *Leptospira* organisms in the blood or cerebrospinal fluid that cause high fever, headache, muscle pain that is predominant in the calves and lumbar area, abdominal pain, nausea, vomiting, diarrhea, cough, and conjunctival suffusion (red eyes with no secretions). The posterior immune phase lasts 4–30 days, in which circulating IgM antibodies and leptospirosis are produced, and patients can present with jaundice, kidney failure, difficulty breathing, hemoptysis, aseptic meningitis, heart arrhythmias, and pancreatitis.<sup>3,4</sup> The most characteristic severe form is Weil's disease. It can appear after the acute phase and is characterized by altered liver function, and pulmonary and renal involvement. The mortality rate in patients with untreated severe disease reaches 40%.<sup>5</sup>

Patients present with a characteristic liver profile: marked direct hyperbilirubinemia (up to 80 mg/dL), associated with a slight increase (2–3 times the normal value) in other enzymes that indicate cholestasis (ALP, GGT) and a slight increase in transaminases (<200 U/L).<sup>6,7</sup> *Leptospira* spirochetes infiltrate the space of Disse and damage the hepatocytes, altering their intercellular binding and causing bile leakage from the bile canaliculi into the sinusoids, which explains the very high levels of direct bilirubin, with no major alterations in ALP or GGT. In addition, due to the fact that there is no hepatocellular necrosis, transaminase levels are not elevated.<sup>1</sup>

Renal involvement varies in severity, ranging from mild, nonoliguric acute kidney injury to established acute kidney failure. The majority of patients that survive recover their

kidney function but some present with lasting chronic kidney disease.<sup>3</sup>

Some patients present with multifactorial hyperlipasemia and hyperamylasemia that is generally secondary to acute kidney failure and the critical status of the patients. Nevertheless, cases of acute pancreatitis due to leptospirosis, that even include fatal outcomes, have been reported.<sup>8</sup> The mechanism of pancreatitis is not clearly defined but it has been postulated that the vasculitis and associated ischemic injury cause the activation of proteolytic enzymes and autodigestion.<sup>8</sup> In the present case, the patient had hyperlipasemia and hyperamylasemia that were not associated with typical abdominal pain or contributory imaging studies, and so the diagnosis of acute pancreatitis was ruled out.

Direct and indirect detection methods are available. The direct detection methods include dark-field microscopy and the polymerase chain reaction technique, in both blood and urine. The standard indirect method is the microscopic agglutination test, in which live antigens react with antibodies in the blood sample, with 77.4% sensitivity and 97.6% specificity. Currently in Peru, the microscopic agglutination test is exclusively performed at the *Instituto Nacional de Salud*, at no cost to the patient.<sup>9</sup>

When leptospirosis is suspected, antibiotic treatment should be started, albeit, according to a recent meta-analysis, its efficacy continues to be controversial.<sup>10</sup> Mild disease is treated with oral doxycycline and severe disease with intravenous penicillin or ceftriaxone.<sup>10</sup> Support treatment is essential. Patients that present with acute kidney injury should receive intense intravenous fluid resuscitation and if they progress to oliguric kidney failure, the early start of hemodialysis reduces mortality.<sup>11</sup> In addition, due to the associated vasculitis, the use of corticosteroids has been suggested in severe cases that have no pulmonary or renal involvement, but in a systematic review, Rodrigo et al. concluded that there is not sufficient evidence for suggesting their use.<sup>12</sup>

In patients with acute kidney failure and acute marked direct hyperbilirubinemia, with no major alterations in the remaining liver function tests and with imaging studies that are negative for obstructive biliary disease, rodent exposure should be searched for and leptospirosis added to the differential diagnosis, for the consequent study and early management of the disease, resulting in a decrease in mortality, as occurred in the case of our patient. Likewise, the fact that these patients can present with hyperlipasemia and hyperamylasemia secondary to acute kidney failure and the critical status of the patient should be kept in mind.

## Ethical disclosures

Informed consent was not required for the publication of the present case because the article contains no personal data that could identify the patient. In addition, the present work meets the current bioethical research norms.

## Financial disclosure

No specific grants were received from public sector agencies, the business sector, or non-profit organizations in relation to this article.

## Conflict of interest

The authors declare that there is no conflict of interest.

## References

1. Haake DA, Levett PN. Leptospirosis in humans. *Curr Top Microbiol Immunol*. 2015;387:65–97, [http://dx.doi.org/10.1007/978-3-662-45059-8\\_5](http://dx.doi.org/10.1007/978-3-662-45059-8_5).
2. Centro Nacional de Epidemiología, Prevención y Control de Enfermedades – MINSA. Número de casos de leptospirosis, Perú 2017-2022 [actualizado 5 Abr 2022; citado 12 May 2022]. Available from: <https://www.dge.gob.pe/portal/docs/vigilancia/sala/2022/SE12/leptospirosis.pdf>.
3. Karpagam KB, Ganesh B. Leptospirosis: a neglected tropical zoonotic infection of public health importance—an updated review. *Eur J Clin Microbiol Infect Dis*. 2020;39:835–46, <http://dx.doi.org/10.1007/s10096-019-03797-4>.
4. Levett PN. Leptospirosis. *Clin Microbiol Rev*. 2001;14:296–326, <http://dx.doi.org/10.1128/CMR.14.2.296-326.2001>.
5. Taylor AJ, Paris DH, Newton PN. A systematic review of the mortality from untreated leptospirosis. *PLoS Negl Trop Dis*. 2015;9:e0003866, <http://dx.doi.org/10.1371/journal.pntd.0003866>.

6. Gancheva GI. Liver involvement in leptospirosis. *Int J Infect Dis Therapy*. 2016;1:6–12, <http://dx.doi.org/10.11648/j.ijidt.20160101.12>.
7. Wysocki J, Liu Y, Shores N. Leptospirosis with acute liver injury. *Proc (Bayl Univ Med Cent)*. 2014;27:257–8, <http://dx.doi.org/10.1080/08998280.2014.11929130>.
8. Maier A, Kaeser R, Thimme R, et al. Acute pancreatitis and vasoplegic shock associated with leptospirosis - a case report and review of the literature. *BMC Infect Dis*. 2019;19:395, <http://dx.doi.org/10.1186/s12879-019-4040-1>.
9. Niloofa R, Fernando N, de Silva NL, et al. Diagnosis of Leptospirosis: Comparison between Microscopic Agglutination Test, IgM-ELISA and IgM Rapid Immunochromatography Test. *PLoS One*. 2015;10:e0129236, <http://dx.doi.org/10.1371/journal.pone.0129236>.
10. Guzmán-Pérez M, Blanch-Sancho JJ, Segura-Luque JC, et al. Current evidence on the antimicrobial treatment and chemoprophylaxis of human leptospirosis: a meta-analysis. *Pathogens*. 2021;10:1125, <http://dx.doi.org/10.3390/pathogens10091125>.
11. Andrade L, de Francesco-Daher E, Seguro AC. Leptospirosis nephropathy. *Semin Nephrol*. 2008;28:383–94.
12. Rodrigo C, Lakshitha de Silva N, Goonaratne R, et al. High dose corticosteroids in severe leptospirosis: a systematic review. *Trans R Soc Trop Med Hyg*. 2014;108:743–50, <http://dx.doi.org/10.1093/trstmh/tru148>.

L.E. Flores<sup>a,\*</sup>, A. Carlin<sup>a,b</sup>, C.A. García<sup>a</sup>

<sup>a</sup> *Servicio de Gastroenterología, Hospital Cayetano Heredia, Lima, Peru*

<sup>b</sup> *Universidad San Ignacio de Loyola, Lima, Peru*

\* Corresponding author at: Sector 2, Grupo 3, Mz H, Lote16, Villa El Salvador, Lima 15831, Peru.

E-mail address: [luis.flores.e@upch.pe](mailto:luis.flores.e@upch.pe) (L.E. Flores).

2255-534X/ © 2022 Asociación Mexicana de Gastroenterología. Published by Masson Doyma México S.A. This is an open access article under the CC BY-NC-ND license (<http://creativecommons.org/licenses/by-nc-nd/4.0/>).

## Reactive ileal lymphoid hyperplasia related to SARS-CoV-2 infection as a unique clinical feature resembling Crohn's disease<sup>☆</sup>



### Hiperplasia linfóide ileal reactiva relacionada con infección por SARS-CoV-2 como característica clínica singular parecida a la enfermedad de Crohn

Although the symptoms and imaging features of coronavirus disease 2019 (COVID-19), caused by severe acute respiratory syndrome coronavirus 2 (SARS-CoV-2), predominantly involve the respiratory system, manifestations of the disease and its possible complications in extrathoracic organs, such as the gastrointestinal (GI) tract and musculoskeletal system, can be found.<sup>1</sup>

We present herein a case of terminal ileitis related to reactive ileal lymphoid hyperplasia (RILH) that occurred in a patient with underlying COVID-19. A 29-year-old man, a smoker, with an unremarkable past medical history, was admitted to the hospital during Spain's Omicron coronavirus wave, presenting with acute abdominal pain in the right lower quadrant (RLQ), of 2-day progression, unaccompanied by diarrhea, respiratory symptoms, or fever. He had received an mRNA COVID-19 vaccine 8 months before admission. A nasopharyngeal swab specimen was positive for RT-PCR SARS-CoV-2, with low cycle threshold values. Respiratory auscultation was normal and blood test results showed increased acute phase reactants. No other labo-

<sup>☆</sup> Please cite this article as: Qanneta R, Feliu-Masgoret M, García-Pardo G et al. Hiperplasia linfóide ileal reactiva relacionada con infección por SARS-CoV-2 como característica clínica singular parecida a la enfermedad de Crohn. *Rev Gastroenterol Méx*. 2023;88:80–82.