

Informed consent was requested from the patients to receive treatment or participate in the research described.

The present work meets the current bioethical research regulations and was approved by the ethics committee of the *Hospital Universitario Clínico San Cecilio*.

This article contains no personal information that can identify the patients.

No experiments were conducted on animals or humans.

## Financial disclosure

No financial support was received in relation to this article.

## Conflict of interest

The authors declare that there is no conflict of interest.

## References

- Giday SA, Pickett-Blakely OE, Buscaglia JM, et al. Capsule retention in a patient with small-bowel diverticulosis. *Gastrointest Endosc*. 2009;69:384–6, <http://dx.doi.org/10.1016/j.gie.2008.03.1085>.
- Liao Z, Gao R, Xu C, et al. Indications and detection, completion, and retention rates of small-bowel capsule endoscopy: a systematic review. *Gastrointest Endosc*. 2010;71:280–6, <http://dx.doi.org/10.1016/j.gie.2009.09.031>.
- Courcoutsakis N, Pitiakoudis M, Mimidis K, et al. Capsule retention in a giant Meckel's diverticulum containing multiple enteroliths. *Endoscopy*. 2011;43:e308–9, <http://dx.doi.org/10.1055/s-0030-1256641>.
- Rondonotti E, Spada C, Adler S, et al. Small-bowel capsule endoscopy and device-assisted enteroscopy for diagnosis and treatment of small-bowel disorders: European Society of Gastrointestinal Endoscopy (ESGE) technical review. *Endoscopy*. 2018;50:423–46, <http://dx.doi.org/10.1055/a-0576-0566>.
- Bhattarai M, Bansal P, Khan Y. Longest duration of retention of video capsule: a case report and literature review. *World J Gastrointest Endosc*. 2013;5:352–5, <http://dx.doi.org/10.4253/wjge.v5.i7.352>.
- Biondi A, Persiani R, Vigorita V, et al. Education and imaging: gastrointestinal: videocapsule retention: rationale for surgical indication. *J Gastroenterol Hepatol*. 2011;26:608, <http://dx.doi.org/10.1111/j.1440-1746.2011.06618.x>.

M.M. Díaz-Alcázar<sup>a,\*</sup>, I. Aguilar-Cruz<sup>b</sup>

<sup>a</sup> *UGC Aparato Digestivo, Hospital Universitario Clínico San Cecilio de Granada, Spain*

<sup>b</sup> *Servicio de Urgencias, Hospital Universitario Clínico San Cecilio de Granada, Spain*

\* Corresponding author at: Hospital Universitario Clínico San Cecilio de Granada, Avenida de la Investigación s/n, 18016 Granada, Spain.

*E-mail address:* [mmardiazalcazar@gmail.com](mailto:mmardiazalcazar@gmail.com) (M.M. Díaz-Alcázar).

2255-534X/ © 2022 Asociación Mexicana de Gastroenterología. Published by Masson Doyma México S.A. This is an open access article under the CC BY-NC-ND license (<http://creativecommons.org/licenses/by-nc-nd/4.0/>).

## Granulomatosis with polyangiitis (Wegener's granulomatosis) with gastrointestinal involvement: A case report<sup>☆</sup>

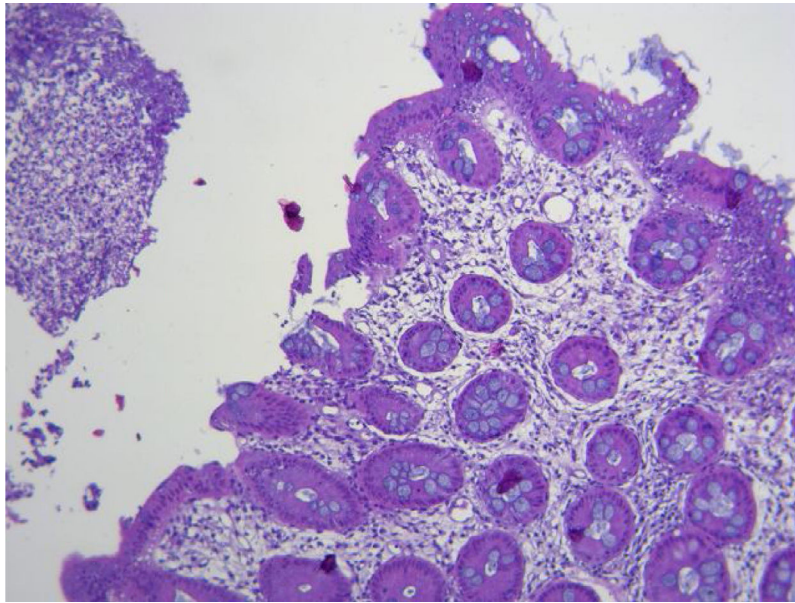


### Granulomatosis con poliangiitis (granulomatosis de Wegener) con involucro gastrointestinal: reporte de caso

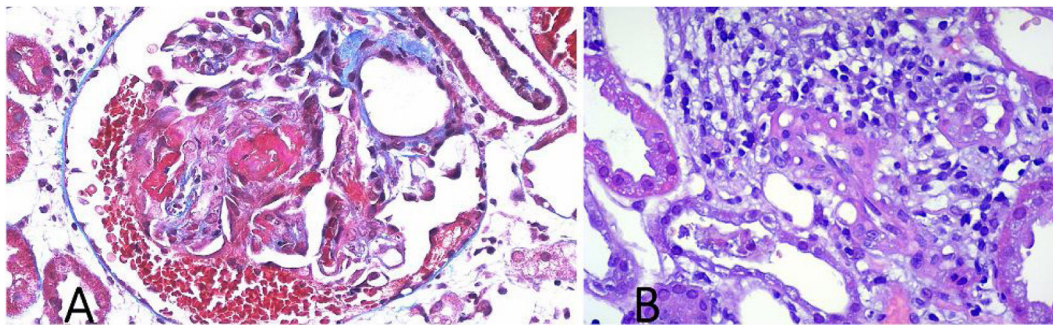
Granulomatosis with polyangiitis (GPA), formerly known as Wegener's granulomatosis<sup>1,2</sup>, is a necrotizing vasculitis that affects the small vessels, with systemic granulomatous inflammation predominantly in the upper respiratory tract, lungs, and kidneys. It is associated with the presence of cytoplasmic anti-neutrophil cytoplasmic antibodies (c-ANCA) and anti-proteinase 3 (anti-PR3) antibodies<sup>1-3</sup>. Albeit infrequently, cases of GPA with gastrointestinal (GI) involvement have been reported at 5–11%<sup>1,2</sup>. The clinical manifestations vary from abdominal pain to massive bleeding and perforation<sup>3,4</sup>.

We present herein the case of a 57-year-old woman, with an unremarkable past medical history, that presented with constitutional symptoms and symmetrical polyarthralgia for two months, as well as bloody stools on three occasions, resulting in her seeking medical attention at the emergency department. Upon hospital admission, her vital signs were within normal parameters. Physical examination revealed abdominal pain in the hypogastrium, increased peristalsis, no signs of peritoneal irritation, joint inflammation in the wrists and ankles, and prolonged capillary refill time; the rest of the examination showed no alterations. Laboratory test results were hemoglobin 9 g/dL, leukocytes 13,220 cell/mm<sup>3</sup>, PMN 81.3%, creatinine 3.40 mg/dL, BUN 39.5 mg/dL, urea 84.6 mg/dL, creatinine clearance 14.6 mL/min, sodium 135 mmol/L, potassium 4.99 mmol/L, C-reactive protein 210 mg/dL; urinalysis: proteinuria 1.51 g/L, hemoglobinuria +++, >100 erythrocytes, 8–10 leukocytes per field, and negative urine culture. Non-contrasted abdominal computed axial tomography (CAT) scan identified wall thickening and edema of the gastric mucosa, and in the terminal ileum, with scant free fluid. Management was started with omeprazole and antibiotic therapy with linezolid and metronidazole. Upper GI endoscopy and colonoscopy were performed, observing a 5 mm ulcer in the antrum (Forrest III) and multiple small ulcerations, with fibrin and a cobblestone pattern, in the terminal ileum and cecum. Biopsy results reported a perivascular inflammatory infiltrate, fibrinous exudate, edema of the lamina propria, and no evidence of malignancy (Fig. 1).

<sup>☆</sup> Please cite this article as: Pérez-Macías JP, Rodarte-Shade M, Garza-García CA, Tueme-De la Peña D, Rodríguez-Guerra ML. Granulomatosis con poliangiitis (granulomatosis de Wegener) con involucro gastrointestinal: reporte de caso. *Rev Gastroenterol Méx*. 2022;87:392–394.



**Figure 1** Histopathologic study of the colonoscopy biopsies showing the mucosa of the cecum with edema and tubular glands with fibrinous exudate on the surface.



**Figure 2** Histopathologic study of the kidney biopsies showing signs of glomerulonephritis with cellular proliferation in a semilunar pattern (A) and the kidney parenchyma with cellular infiltration consistent with vasculitis (B).

Methylprednisolone and mesalazine were started and the rheumatology service was consulted. Laboratory results showed positive C-ANCA 1:1,280 and positive anti-PR3 with 427 IAs. Percutaneous kidney biopsy revealed granulomatosis with polyangiitis (Fig. 2). Cyclophosphamide was added, along with trimethoprim/sulfamethoxazole as *Pneumocystis jirovecii* prophylaxis. The patient improved and was released on day seven of hospitalization. There were no remarkable findings at the follow-up at six months.

The current worldwide incidence of GPA is 20 cases per million, affecting patients between 50 and 70 years of age, with a predominance in White and Asian populations<sup>2,4</sup>. Clinical manifestations include constitutional symptoms, rapidly progressive necrotizing glomerulonephritis, and involvement of the respiratory tract, peripheral nerves, eyes, joints, and skin<sup>1,2,4</sup>. GI involvement is rare and tends to occur after the diagnosis of GPA. When it presents simultaneously, it is associated with greater kidney involvement and mortality<sup>1,2,5</sup>. The disease is caused by a mesenteric vasculitis or direct damage to the submucosal vessels<sup>2-6</sup>. It tends to present as abdominal pain, nausea, vomiting, gastrointestinal bleeding, intestinal ischemia, and perforation<sup>3,5-8</sup>. Those symptoms tend to remit with the management of GPA<sup>1,2</sup>.

Nevertheless, other causes of gastrointestinal involvement must be ruled out before starting treatment<sup>1,6,9</sup>.

The diagnosis of gastrointestinal involvement in GPA is based on the presence of GI symptoms, associated with the involvement of other organs, and is complemented by the presence of C-ANCA in 90% of cases, anti-PR3 in 75%, or myeloperoxidase in 20%<sup>2,4,6-8</sup>. Pneumoperitoneum, wall thickening, abscesses, free fluid, and microaneurysms in the mesenteric artery can be seen in imaging studies<sup>1,9</sup>. Endoscopy and colonoscopy may be normal, even in severe cases, but multiple small, round, clear ulcers, associated with clots or recent bleeding, and with diffuse erythema and edema of the mucosa, are commonly observed<sup>1,5,9</sup>. Biopsies confirm GI involvement, reporting neutrophil infiltrates in the submucosal small vessels (arterioles, venules, and capillaries), causing necrosis, ulceration of the mucosa, granulomatous inflammation surrounded by irregular fibroid necrosis, thrombosis, and fibrosis<sup>1,4,5,9</sup>.

Conservative management with fasting, fluid therapy, nutrition, systemic antibiotic therapy, and systemic glucocorticoids in combination with immunosuppressants, such as cyclophosphamide or rituximab, enable resolution in weeks, in the majority of patients<sup>1,2,4</sup>. In cases of intesti-

nal perforation or severe bleeding, surgical management is required<sup>1,3,6,8</sup>.

Without treatment, the prognosis is fatal outcome at six months<sup>4</sup>. With treatment, the prognosis is reserved, due to the high relapse rate (30–60%)<sup>2,4,7</sup>. The main causes of death are surgical complications in 44% of patients<sup>7</sup> and chronic kidney failure in 50%<sup>2</sup>.

To the best of our knowledge, this is the first case of a patient with GPA with GI involvement to be reported in Latin America. It is important to emphasize the relation between GPA and GI bleeding, to make the diagnosis and provide opportune treatment.

## Ethical considerations

The present study complies with the current bioethical research regulations, including the protection of persons and animals, data confidentiality following the protocols of the work center regarding their publication and the preservation of patient anonymity, right to privacy, and informed consent. The authors declare that there is no personal information that can enable patient identification.

## Financial disclosure

No specific grants were received from public sector agencies, the business sector, or non-profit organizations in relation to this study.

## Conflict of interest

The authors declare that there is no conflict of interest.

## References

- Erikson P, Segelmark M, Hallböök O, et al. Frequency, diagnosis, treatment, and outcome of gastrointestinal disease in granulomatosis with polyangiitis and microscopic polyangiitis. *J Rheumatol*. 2018;45:529–37, <http://dx.doi.org/10.3899/jrheum.170249>.
- Geetha D, Jefferson JA. ANCA-associated vasculitis: core curriculum 2020. *Am J Kidney Dis*. 2020;75:124–37, <http://dx.doi.org/10.1053/j.ajkd.2019.04.031>.
- Deger SM, Sahin T, Vural C, et al. Wegener's granulomatosis with massive gastrointestinal hemorrhage due to jejunal and colonic involvement: report of a case. *Surg Today*. 2008;38:166–9, <http://dx.doi.org/10.1007/s00595-007-3574-9>.
- Lynch JP, Derhovanessian A, Tazelaar H, et al. Granulomatosis with polyangiitis (Wegener's Granulomatosis): evolving concepts in treatment. *Semin Respir Crit Care Med*. 2018;39:434–58, <http://dx.doi.org/10.1055/s-0038-1660874>.
- Latus J, Koetter I, Fritz P, et al. Gastrointestinal involvement in granulomatosis with polyangiitis and microscopic polyangiitis: histological features and outcome. *Int J Rheum Dis*. 2014;17:412–9, <http://dx.doi.org/10.1111/1756-185X.12203>.
- Mehmet Arhan, Seyfettin Köklü, Yalcin F, et al. Severe intestinal bleeding in a patient with Wegener's granulomatosis. *Am J Gastroenterol*. 2009;104:2119–20, <http://dx.doi.org/10.1038/ajg.2009.209>.
- Pagnoux C, Mahr A, Cohen P, et al. Presentation and outcome of gastrointestinal involvement in systemic necrotizing vasculitides: analysis of 62 patients with polyarteritis nodosa, microscopic polyangiitis, Wegener granulomatosis, Churg-Strauss syndrome, or rheumatoid arthritis-associated vasculitis. *Medicine (Baltimore)*. 2005;84:115–28, <http://dx.doi.org/10.1097/01.md.0000158825.87055.0b>.
- Steele C, Bohra S, Broe P, et al. Acute upper gastrointestinal haemorrhage and colitis: an unusual presentation of Wegener's granulomatosis. *Eur J Gastroenterol Hepatol*. 2001;13:993–5, <http://dx.doi.org/10.1097/00042737-200108000-00023>.
- Deniz K, Ozşeker HS, Balas S, et al. Intestinal involvement in Wegener's granulomatosis. *J Gastrointest Liver Dis*. 2007;16:329–31.

J.P. Pérez-Macías<sup>a,\*</sup>, M. Rodarte-Shade<sup>a</sup>,  
C.A. Garza-García<sup>b</sup>, D. Tueme-De la Peña<sup>a</sup>,  
M.L. Rodríguez-Guerra<sup>a</sup>

<sup>a</sup> *Departamento de Cirugía General, Hospital Christus Muguerza Alta Especialidad, Monterrey, Nuevo León, Mexico*

<sup>b</sup> *Departamento de Nefrología y Medicina Interna, Hospital Christus Muguerza Alta Especialidad, Monterrey, Nuevo León, Mexico*

\* Corresponding author at: 1. Universidad de Monterrey, Escuela de Medicina, Especialidades Médicas. Av. Ignacio Morones Prieto 4500, Jesús M. Garza, San Pedro Garza García, N.L. C.P. 66238. 2. Departamento de Cirugía, Hospital Christus Muguerza, Alta Especialidad. Miguel Hidalgo 2525, Obispaño, Monterrey, Nuevo León, C.P. 64060, Mexico. Tel.: +521 3525575834.

E-mail address: [drjorgepabloperez@gmail.com](mailto:drjorgepabloperez@gmail.com) (J.P. Pérez-Macías).

2255-534X/ © 2022 Asociación Mexicana de Gastroenterología. Published by Masson Doyma México S.A. This is an open access article under the CC BY-NC-ND license (<http://creativecommons.org/licenses/by-nc-nd/4.0/>).

## Esophageal bezoar: A multidisciplinary approach<sup>☆</sup>



## Bezoar esofágico: un abordaje multidisciplinario

Esophageal bezoar is a rare condition that is usually associated with structural or motility disorders<sup>1</sup>. Endoscopy is the

main tool for diagnosis and treatment, requiring a single session or multiple sessions<sup>1,2</sup>.

An 81-year-old man was admitted in the emergency department with dysphagia and hypersalivation after having eaten bread and fish three days prior. He had a history of diabetes mellitus, ischemic stroke, ischemic heart disease, and was in treatment with acetylsalicylic acid, metformin, pantoprazole, indapamide, and perindopril. The patient had presented with progressive dysphagia to solid food for the past few months but had not sought medical attention. Physical examination, chest X-ray, and blood test were normal.

An esophageal endoscopy was performed. The esophagus was completely obstructed by a firm, yellowish concretion, 25 cm from the incisor teeth (Figs. 1 and 2). Multiple endo-

<sup>☆</sup> Please cite this article as: Muñiz-Muñoz M, Segovia-Alonso P, Delgado-Álvarez MP, Villanueva-Hernández R. Bezoar esofágico: un abordaje multidisciplinario. *Rev Gastroenterol Méx*. 2022;87:394–396.