

treatment of choice, conservative medical management with antibiotic therapy should be considered in mild cases^{3,4}.

Ethical considerations

The authors declare that the manuscript contains no personal information that can identify the patient, who signed a statement of informed consent for the performance of the studies. The corresponding author is in possession of said document. No experiments were conducted on animals or humans. The correct protocol was followed at all times, with the agreement of the patient and her family.

Financial disclosure

No financial support was received in relation to this article.

Conflict of interest

The authors declare that they have no conflict of interest.

References

- Saijo F, Sawada K, Nomura R, et al. Penetration and perforation of terminal ileum diverticulitis. *Case Rep Surg.* 2020, <http://dx.doi.org/10.1155/2020/7361389>.
 - Liu CY, Chang WH, Lin SC, et al. Analysis of clinical manifestations of symptomatic acquired jejunoileal diverticular disease. *World J Gastroenterol.* 2005;11:5557–60, <http://dx.doi.org/10.3748/wjg.v11.i35.5557>.
 - Kassir R, Boueil-bourlier A, Baccot S, et al. Jejuno-ileal diverticulitis: Etiopathogenicity, diagnosis and management. *Int J Surg Case Rep.* 2015;10:151–3, <http://dx.doi.org/10.1016/j.ijscr.2015.03.044>.
 - Ramistella AM, Brenna M, Fasolini F, et al. Jejuno-ileal diverticulitis: a disorder not to underestimate. *Int J Surg Case Rep.* 2019;58:81–4, <http://dx.doi.org/10.1016/j.ijscr.2019.04.015>.
- J. García-Márquez*, F.J. García-Verdejo,
A.M. Caballero-Mateos
- Unidad de Aparato Digestivo, Hospital Universitario San Cecilio, Granada, Spain*
- * Corresponding author at: Hospital Universitario San Cecilio, Avenida de la Investigación s/n, 18016, Granada, Spain. Tel.: 618242443.
E-mail address: joagarmar@hotmail.com
(J. García-Márquez).
- 2255-534X/ © 2021 Asociación Mexicana de Gastroenterología. Published by Masson Doyma México S.A. This is an open access article under the CC BY-NC-ND license (<http://creativecommons.org/licenses/by-nc-nd/4.0/>).

Arterial embolization for the control of lower gastrointestinal bleeding. Treatment or complication? ☆



Embolización arterial para control de sangrado gastrointestinal bajo. ¿Tratamiento o complicación?

Ischemic colitis (IC) is the most common cause of intestinal ischemia (60-70%). Fulminant presentation occurs in less than 5% of all cases, but it is a life-threatening situation with a high mortality rate^{1,2}. The causes of IC have been classified as systemic or local, occlusive or non-occlusive, and iatrogenic or non-iatrogenic, with post-embolization IC standing out in the latter group³. We report herein a case of arterial post-embolization fulminant IC.

A middle-aged female patient, with a personal history of high blood pressure, type 2 diabetes mellitus, and dyslipidemia, was admitted for abdominal pain and vomiting of 2-month progression. Two days later, she developed rectal bleeding, with hemodynamic instability (Hb 6 g/dl), and acute renal failure (Cr 6 mg/dl). Abdominal CT-angiography showed active intraluminal bleeding, arising

from the splenic flexure (Fig. 1). Superselective arterial embolization of the distal branch of the left colic artery was performed, utilizing microspheres, with no immediate adverse events. At 24-48 h post-embolization, after new episodes of massive rectal bleeding, urgent colonoscopy was performed, leading to a diagnosis of fulminant ischemic pancolitis (Fig. 2).

Due to persistent hemodynamic instability and massive rectal bleeding, with no response to conservative treatment, urgent surgical intervention was decided upon and total colectomy with ileostomy was carried out.

The histopathologic evaluation of the surgical specimen confirmed the diagnosis of gangrenous IC.

Fulminant forms of IC, resulting in gangrenous necrosis with perforation, peritonitis, and death, do not exceed 5%. Only clinical suspicion confirmed by endoscopic findings enables early diagnosis and salvage therapy (colectomy in most cases)^{2,4}.

Multiple factors predispose to the development of IC. The most common causes are non-occlusive (atherosclerosis, hypoperfusion states, etc.), whereas the occlusive forms are more atypical. Those secondary to embolization are now exceptional¹.

Adverse events of arterial embolization are infrequent because most procedures are currently performed utilizing superselective catheterization^{5,6}. In a large study on 134 patients, intestinal ischemia was below 6%⁷.

The risk of symptomatic intestinal ischemia depends on the clinical-anatomic setting of the patient and the tech-

☆ Please cite this article as: Valdés-Delgado T, Jiménez-García VA, Galván-Fernández MD. Embolización arterial para control de sangrado gastrointestinal bajo. ¿Tratamiento o complicación? *Revista de Gastroenterología de México.* 2022;87:119–122.

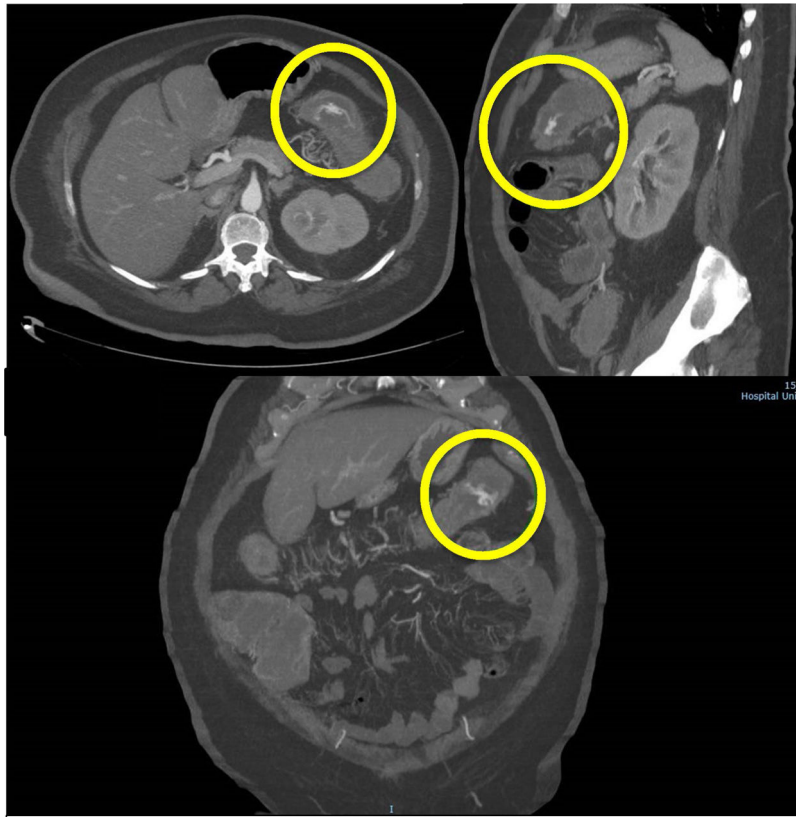


Figure 1 Abdominal CT angiography: active intraluminal bleeding of the left colic artery, with contrast medium extravasation (circle).

nical aspects of the interventional radiology procedure. Procedure-related aspects that minimize said adverse event include the adequate selection of the embolization agents and avoidance of extensive embolization^{4,8}. The few cases of intestinal ischemia reported after superselective embolization have been due to the fact that the compensatory collateral circulation pathways were not respected, as likely occurred in the present report.

Nevertheless, choosing a suitable embolic agent is important. Available options include microcoils, gelfoam, polyvinyl alcohol (PVA), and microspheres, and outcomes vary, depending on the material chosen and its utilization. Gelfoam is used as a temporary embolic agent and is relatively safe, but it is not conducive to complete embolization and the rate of recurrent bleedings is higher than that of other embolic agents. Particles achieve rapid and complete embolization of the target artery, regardless of artery type and diameter. However, the complication rate is higher than that of other agents, owing to the high risk of non-target embolization. Microspheres present a greater risk for ischemia, compared with PVA particles, due to the more distal vascular occlusion that appears to be related to their compressibility capacity. Microcoils can be clearly seen in lateral fluoroscopic imaging and are easily and accurately positioned. Although we used gelfoam fragments and particles safely and successfully, those agents have their disadvantages. For example, they

are not sufficiently radiopaque, thus the final resting position cannot be easily controlled, which makes manipulating the quantity of the agents more difficult. We performed embolization with gelfoam fragments and particles. Because it is a procedure that is not as tightly controlled as embolization with microcoils, it is more likely to trigger bowel infarction^{6,7}.

Although uncommon, fulminant IC is a life-threatening condition with a high mortality rate², if an urgent therapeutic approach is not performed^{4-7,9}. To minimize its risk, superselective embolization should be used whenever possible⁷, keeping in mind that adverse events related to the clinical-anatomic setting of the patient can still occur.

Ethical considerations

Informed consent was not required for the present type of study. Consent for publication was obtained, regarding all personal data included in the case.

Funding

This study was not supported by any funding.

Conflict of interest

The authors declare that they have no conflict of interest.

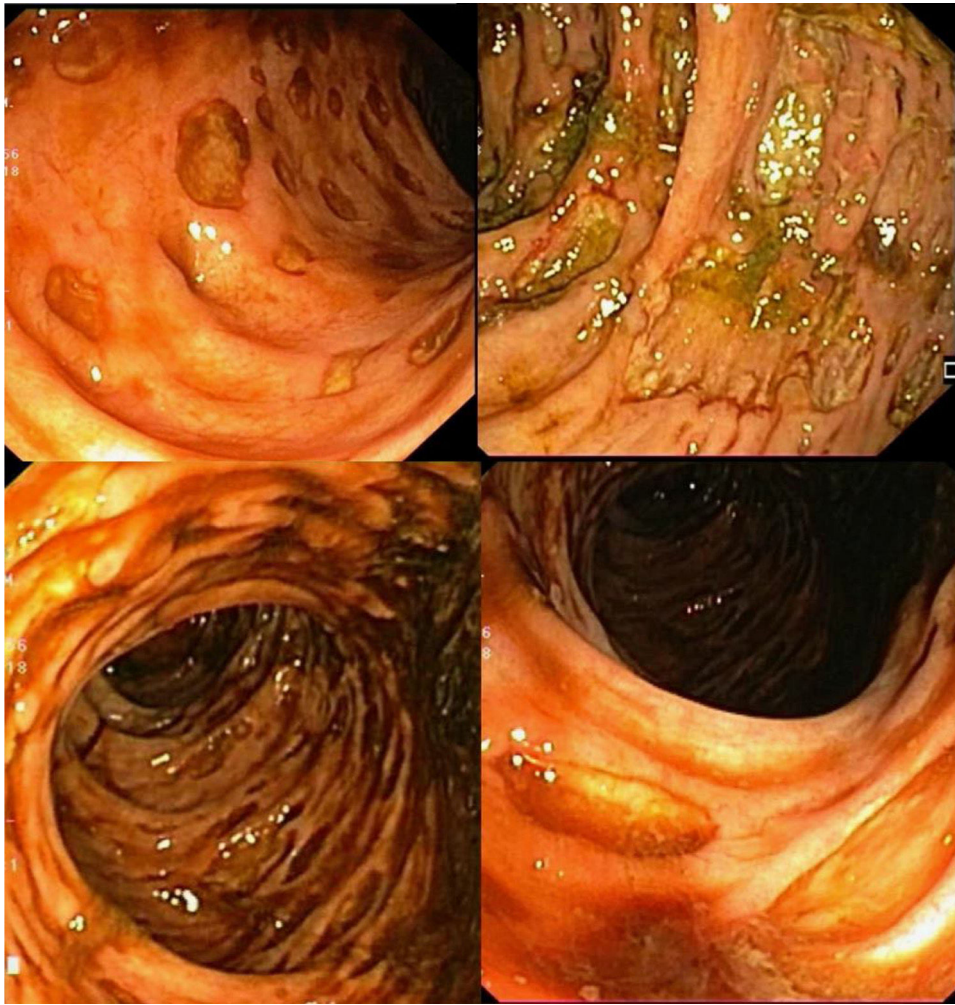


Figure 2 Colonoscopy: extensive punched-out ulcer lesions distributed from the sigmoid colon to the cecum.

References

1. Mohanapriya T, Singh KB, Arulappan T, et al. Ischemic Colitis. *Indian J Surg.* 2012;74:396–400.
2. Cosme A, Montoro M, Santolaria S, et al. Prognosis and follow-up of 135 patients with ischemic colitis over a five-year period. *World J Gastroenterol.* 2013;19:8042–6.
3. Kang H, Kim HG, Ju JK, et al. Fulminant gangrenous ischemic colitis: Is it the solely severe type of ischemic colitis? *Int J Colorectal Dis.* 2012;27:125–6.
4. García-Mónaco RD, Peralta O, Fernández-Antruejo L, et al. Embolización superselectiva en el tratamiento de la hemorragia digestiva baja masiva. *Acta Gastroenterol Latinoam.* 2011;41:119–28. PMID: 21894725.
5. Kwon JH, Han YH. Efficacy and safety of superselective trans-catheter arterial embolization of upper and lower gastrointestinal bleeding using N-butyl-2-cyanoacrylate. *Emerg Radiol.* 2018;25:111–20.
6. Lv LS, Gu JT. Super-selective arterial embolization in the control of acute lower gastrointestinal hemorrhage. *World J Clin Cases.* 2019;7:3728–33.
7. Kwon JH, Kim MD, Han K, et al. Transcatheter arterial embolisation for acute lower gastrointestinal haemorrhage: a single-centre study. *Eur Radiol.* 2019;29:57–67.
8. Noh SM, Shin JH, Kim HIL, et al. Clinical outcomes of angiography and transcatheter arterial embolization for acute gastrointestinal bleeding: analyses according to bleeding sites and embolization types. *Korean J Gastroenterol.* 2018;71:219–28.
9. Shi ZX, Yang J, Liang HW, et al. Emergency transcatheter arterial embolization for massive gastrointestinal arterial hemorrhage. *Medicine (Baltimore).* 2017;96:e9437.

T. Valdés-Delgado*, V.A. Jiménez-García,
M.D. Galván-Fernández

Unidad de Gastroenterología y Endoscopia, Hospital Universitario Virgen Macarena, Sevilla, Spain

*Corresponding author at: Departamento de Gastroenterología, Av. Dr. Fedriani s/n, Sevilla 41009, Spain. Tel.: +34-680239587; Fax: +34-955008805.
E-mail address: teresavaldes4@hotmail.com
(T. Valdés-Delgado).

2255-534X/ © 2021 Asociación Mexicana de Gastroenterología. Published by Masson Doyma México S.A. This is an open access article under the CC BY-NC-ND license (<http://creativecommons.org/licenses/by-nc-nd/4.0/>).

An unusual case of intestinal obstruction beyond the proximal ileum due to the internal bumper of a percutaneous endoscopic gastrostomy[☆]



Un caso inusual de obstrucción intestinal más allá de íleon proximal debido a migración interna de una gastrostomía endoscópica percutánea

Percutaneous endoscopic gastrostomy (PEG) is a popular technique, through which a flexible feeding tube is endoscopically placed in the stomach. The aim of the PEG is to maintain feeding and drug administration in patients that cannot use the oral route¹⁻³. It is a simple procedure, with a low incidence of complications. When complications do appear, the clinical picture is usually atypical, and so adequate clinical suspicion is required for their diagnosis¹⁻⁴. In addition, optimal care of the device could prevent the development of equipment-related harmful complications⁴.

A 74-year-old man had a history of hemophilia A. One month earlier, he sought medical attention for occipital trauma and a computed tomography (CT) scan identified a parietal/temporal fracture, with no signs of intracranial bleeding. One month later, he went to the emergency service at another center due to acute worsening of alertness. Physical examination revealed deviation of the eyes and head to the right, left homonymous hemianopsia, left-sided facial muscle paralysis, and left hemiplegia. The brain CT scan showed intraparenchymal hemorrhage in the frontal and temporal lobes, with midline shift. The patient was transferred to the intensive care unit, after undergoing right parietal decompressive craniotomy. Insertion of a PEG tube was considered necessary for feeding purposes and drug administration. After a prolonged hospital stay (2 months), the patient progressively recovered an adequate level of alertness. PEG tube removal was attempted through external traction and several attempts failed. Although endoscopic removal is the recommendation in case of failure of external traction, it was decided to section the PEG tube with scissors, and the patient was informed that it would exit the body in the passage of stool. He was discharged to his home.

Six months later, the patient arrived at our hospital emergency department due to generalized abdominal pain, fecaloid vomiting, and fever of 3-day progression. He also described previous episodes of self-limited abdominal colicky pain, at varying locations, for the past 5 months. An abdominal CT scan revealed regional inflammation and proximal ileum ectasia due to impaction of a round foreign body, 2 cm in diameter, at the terminal ileum (Fig. 1). There were no signs of abscesses or bowel perforation. Because endoscopic removal of the PEG bumper was not feasible, the patient was transferred to the operating room and a laparotomy was performed. A foreign body, congruent with the internal bumper of a PEG, was removed from the terminal ileum (Fig. 2) through enterotomy. After recovering intestinal peristalsis and oral tolerance, the patient was discharged.

PEG is a simple, cost-effective procedure, with a low mortality rate, that ensures nutrition and drug administration. PEG is increasingly popular, especially in the management of patients after stroke². As a consequence of its increased use, there has also been an increment in PEG-associated complications¹⁻³. Migration of the internal bumper of the PEG is a rare complication, with few cases described in the scientific literature. Intestinal peristalsis can nudge the internal bumper, in the absence or dysfunction of the external bumper, resulting in ulcers or even perforations^{2,3}. Clinical features are nonspecific, and patients seek medical attention at emergency services when mechanical obstruction occurs, even though abdominal pain and vomiting are symptoms that are frequently present, even months before the acute episode¹⁻⁶.

Physical examination and complementary explorations between episodes can be normal, making accurate diagnostic suspicion crucial. Cases in the literature describe gastric outlet and duodenal obstruction as a complication of migrated gastrostomy tube^{5,6}, as well as pancreatitis due to obstruction at the ampulla of Vater⁷. However, to the best of our knowledge, this is the first report of a case of internal bumper migration beyond the proximal ileum¹. Adequate manipulation of the PEG can resolve most of those types of complications, but distal migrations are more likely to require surgical management.

Potential benefits of endoscopic control during PEG removal have been proposed⁴. Nevertheless, daily care and optimal manipulation appear to be the best methods for preventing complications^{1,3}. Collecting all information about the PEG characteristics and registering the chronology of its manipulation are recommended strategies for preventing complications. Early suspicion and diagnosis can prevent distal migrations, and consequently increase the possibility of successful endoscopic management.

In conclusion, PEG has become a routine technique with potential benefits, but it is not without risks. We present

[☆] Please cite this article as: Moragón-Ledesma S, Gurjián-Arena AA, Díaz-Fontenla F, Galeano-Valle F, Demelo-Rodríguez P. Un caso inusual de obstrucción intestinal más allá de íleon proximal debido a migración interna de una gastrostomía endoscópica percutánea. *Rev Gastroenterol Méx.* 2022;87:122–124.