



REVISTA DE GASTROENTEROLOGÍA DE MÉXICO

www.elsevier.es/rgmx



CLINICAL IMAGE IN GASTROENTEROLOGY

Scurvy, a disease forgotten as cause of gastrointestinal manifestations[☆]



El escorbuto, patología olvidada como causa de manifestaciones gastrointestinales

F.X. Cano Calderero^{a,*}, M.D. Santelli Romano^b

^a Servicio de Digestivo, Hospital Universitario San Agustín de Avilés, Principado de Asturias, Spain

^b Facultad de Ciencias Médicas, Universidad Católica de Santiago de Guayaquil, Guayaquil, Ecuador

Scurvy is currently a very rare disease and is caused by severe ascorbic acid deficiency. It is often a clinical characterization in patients with critical nutritional alterations or predisposing diseases.^{1,2} Collagen synthesis is directly affected, generally resulting in mucocutaneous, gastrointestinal, and neurologic manifestations.³

A 66-year-old woman presented with severe malnutrition (marasmus), a body mass index (BMI) of 12, and serum proteins within the reference range. She was admitted to the Gastrointestinal Service due to asthenia, abdominal pain, and chronic diarrhea, symptoms to which the patient attributed her underweight and progressive asthenia. Colonoscopy identified friable mucosa and patchy erosions in the colon (Fig. 1), with nonspecific biopsy results. Physical examination revealed ecchymosis in the upper limbs (Fig. 2), exfoliative dermatitis, gingival bleeding, partial edentulism (Fig. 3), and swelling of the lower limbs (Fig. 4).

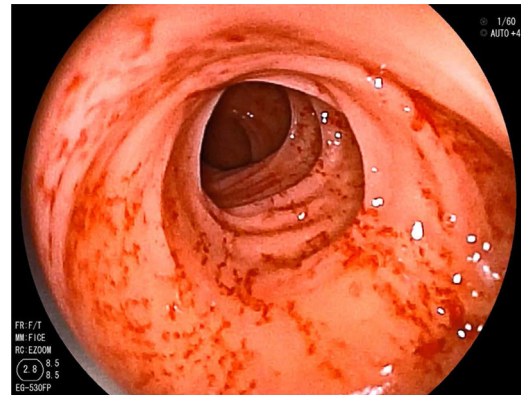


Figure 1 Patchy erosions with marked friability of the colonic mucosa.

Clinical suspicion was scurvy, and so vitamin C determination in blood by chromatography was ordered. The result was below 0.1 mg/dL, with a range of 0.40–2.00 mg/dL.

Financial disclosure

The authors declare that no financial support or stipend was received from any public or private institution.

[☆] Please cite this article as: Cano Calderero FX, Santelli Romano MD. El escorbuto, patología olvidada como causa de manifestaciones gastrointestinales. Rev Gastroenterol México. 2021;86:437–438.

* Corresponding author. Servicio Digestivo Hospital Universitario San Agustín. Tel.: +34 985 123 000.

E-mail address: dr.canocalderero@gmail.com (F.X. Cano Calderero).

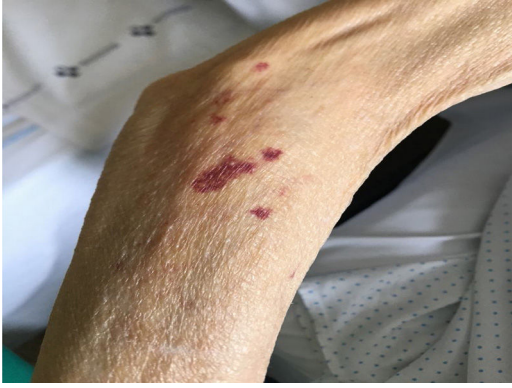

Figure 2 Ecchymosis and capillary fragility in the upper limbs.

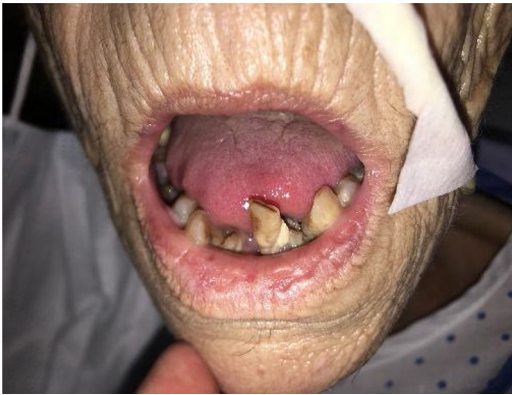

Figure 3 Chronic gingivitis with partial edentulism.

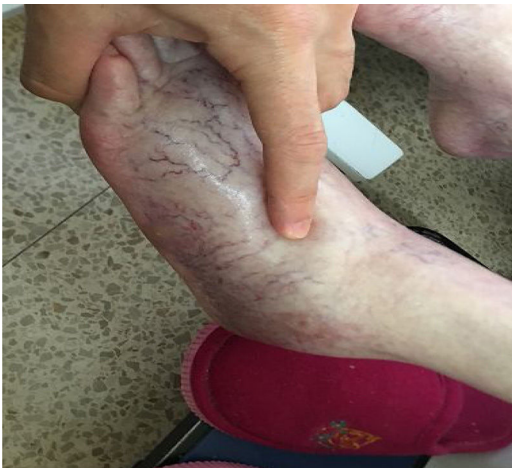

Figure 4 Pitting edema in the perimalleolar region.

Conflict of interest

The authors declare that there is no conflict of interest inherent in the drafting or publishing of this article.

Ethical considerations

The authors declare that no experiments were conducted on humans or animals for the present article, eliminating the need for prior authorization by the Bioethics Committee of their center and that they have followed the protocols of their work center on the publication of patient data. They declare they have preserved patient anonymity at all times and consider that the images and specific information provided do not allow the patient to be identified. Thus, informed consent was not required for the publication of the present case. Nevertheless, verbal consent was given to the lead author by the patient, when the photos were being taken.

References

1. Pan T, Hennrikus EF, Hennrikus WL. Modern day scurvy in pediatric orthopaedics: a forgotten illness. *J Pediatr Orthop.* 2021;41:e279–84.
2. Golriz F, Donnelly LF, Devaraj S, et al. Modern American scurvy – experience with vitamin C deficiency at a large children’s hospital. *Pediatr Radiol.* 2017;47:214–20.
3. Institute of Medicine (US) Panel on Dietary Antioxidants and Related Compounds. *Dietary Reference Intakes for Vitamin C, Vitamin E, Selenium, and Carotenoids.* Washington (DC): National Academies Press (US); 2000.