

## Acknowledgements

The authors wish to thank Dr. Alejandra Consuelo Sánchez of the Department of Gastroenterology and Nutrition at the *Hospital Infantil de México Federico Gómez*, Mexico City, Mexico.

## References

- Erginel B, Gün F, Kocaman H, et al. Three cases of triple A syndrome (Allgrove syndrome) in pediatric surgeon view. *Acta Chir Belg.* 2016;116:119–21, <http://dx.doi.org/10.1080/00015458.2016.1139835>.
- Capataz Ledesma M, Méndez Pérez P, Rodríguez López R, et al. Síndrome de Allgrove (triple A). Hallazgo de una mutación no descrita en el gen AAAS. *An Pediatr (Barc).* 2013;78:109–12, <http://dx.doi.org/10.1016/j.anpedi.2012.06.009>.
- García Compeán D, Ramón Martínez H, Villegas González MJ, et al. Acalasia, alacrima sin insuficiencia suprarrenal, con disfunción neurológica periférica y autonómica (síndrome de Allgrove). *Rev Gastroenterol Mex.* 1998;63:33–6.
- Martínez Guzmán O, Hernández Abrego MP, Villanueva Mendoza C. Síndrome de Allgrove: reporte de un caso. *Bol Med Hosp Infant Mex.* 2009;66:76–9.
- González Rodríguez RI, Serrano Mendoza M, Montiel Jarquín AJ, et al. Síndrome de Allgrove. Informe de un caso. *Rev Fac Med UNAM.* 2016;59:16–9.
- Foster C, Choudhary A. Severe malnutrition causing superior mesenteric artery syndrome in an adolescent with triple A syndrome. *J Pediatr Endocrinol Metab.* 2016;29:1221–4, <http://dx.doi.org/10.1515/jpem-2015-0373>.
- Hallal C, Kieling CO, Nunes DL, et al. Diagnosis, misdiagnosis, and associated diseases of achalasia in children and adolescents: a twelve-year single center experience. *Pediatr Surg Int.* 2012;28:1211–7, <http://dx.doi.org/10.1007/s00383-012-3214-3>.
- Zaninotto G, Bennett C, Boeckstaens G, et al. The 2018 ISDE achalasia guidelines. *Dis Esophagus.* 2018;31:1–29, <http://dx.doi.org/10.1093/dote/doy071>.
- Grabowski A, Korlacki W, Pasierbek M, et al. Pediatric achalasia. Single-center study of interventional treatment. *Prz Gastroenterol.* 2017;12:98–104, <http://dx.doi.org/10.5114/pg.2016.64845>.
- Van Lennep M, van Wijk MP, Omari TI, et al. Clinical management of pediatric achalasia: a survey of current practice. *J Pediatr Gastroenterol Nutr.* 2019;68:521–6, <http://dx.doi.org/10.1097/MPG.0000000000002221>.
- Brown B, Agdere L, Muntean C, et al. Alacrima as a harbinger of adrenal insufficiency in a child with Allgrove (AAA) syndrome. *Am J Case Rep.* 2016;17:703–6, <http://dx.doi.org/10.12659/ajcr.899546>.
- Kurnaz E, Duminuco P, Aycan Z, et al. Clinical and genetic characterisation of a series of patients with triple A syndrome. *Eur J Pediatr.* 2018;177:363–9, <http://dx.doi.org/10.1007/s00431-017-3068-8>.
- Pedreira CC, Zacharin MR. Allgrove syndrome: when a recognizable pediatric disorder occurs in adulthood. *Med J Aust.* 2004;180:74–5.

Y. Rivera-Suazo<sup>a,\*</sup>, M.X. Espriu-Ramírez<sup>a</sup>, S.A. Trauernicht-Mendieta<sup>a</sup>, L. Rodríguez<sup>b</sup>

<sup>a</sup> *Departamento de Gastroenterología y Nutrición, Hospital Infantil de México Federico Gómez, Mexico City, Mexico*

<sup>b</sup> *Departamento de Gastroenterología, Hepatología y Nutrición Pediátrica, Unidad de Procedimientos, Yale University School of Medicine, New Haven, CT, United States*

\*Corresponding author at: Hospital Star Médica Infantil Privado, Viaducto Río Becerra 97, Consultorio 506, Nápoles, Benito Juárez, Código Postal 03810, Mexico City, Mexico. 5553401000, extensión 2518.

E-mail address: [rivera.suazo@outlook.com](mailto:rivera.suazo@outlook.com) (Y. Rivera-Suazo).

2255-534X/ © 2020 Asociación Mexicana de Gastroenterología. Published by Masson Doyma México S.A. This is an open access article under the CC BY-NC-ND license (<http://creativecommons.org/licenses/by-nc-nd/4.0/>).

## Finding of gastric pneumatosis on a computed tomography scan as a sign of gastric ischemia secondary to probable thrombosis in a patient with chronic kidney disease: A case report<sup>☆</sup>

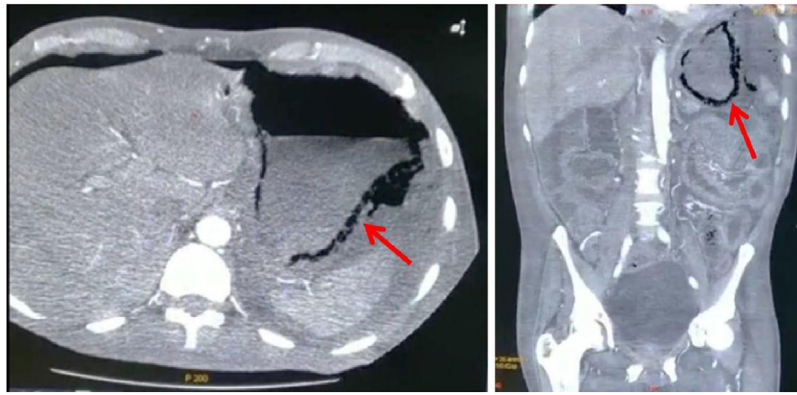


Reporte de caso: hallazgo de neumatosis gástrica en tomografía axial computarizada como signo de isquemia gástrica secundaria a probable trombosis en paciente con enfermedad renal crónica

The frequency of gastric ischemia is low due to the rich blood supply of the stomach. It can be caused by vascular insufficiency, thrombosis, vasculitis, etc<sup>1</sup>. Factors, such as advanced age, smoking, and diabetes, can reduce gastric and splenic circulation<sup>1,2</sup>. The most common symptoms are abdominal pain, bleeding, and altered mental status<sup>1</sup> and laboratory tests tend to report leukocytosis and elevated C-reactive protein and liver enzymes<sup>3</sup>. Pneumatosis is characterized by the presence of gas vesicles in the intestinal wall<sup>4</sup>. In a meta-analysis of studies conducted over the past 5 years, a frequency of just 500 cases was found, with 30% of cases reported in the United States and 1.14% in Latin America<sup>5</sup>. Its pathophysiology is unclear, albeit there are 2 important theories: *the mechanical theory* suggests that the increase in intraluminal pressure forces the entrance

<sup>☆</sup> Please cite this article as: González-Palacio CL, Venegas-Yáñez CE, Enríquez-Sánchez LB, Carrillo-Gorena MJ, Aguirre-Baca A. Reporte de caso: hallazgo de neumatosis gástrica en tomografía

axial computarizada como signo de isquemia gástrica secundaria a probable trombosis en paciente con enfermedad renal crónica. *Revista de Gastroenterología de México.* 2021;86:443–445.



**Figure 1** Abdominal computed tomography scan showing pneumatosis of the gastric wall (red arrow); axial view (left side) and coronal view (right side).

of air into the gastrointestinal wall through defects in the mucosa, and *the bacterial theory* states that it is the result of the accumulation of gas produced by bacteria after their translocation<sup>6</sup>. Its manifestations and imaging study results are generally not conclusive, making exploratory surgery necessary for making the diagnosis<sup>2</sup>. Pneumatosis of the gastric wall is suggestive of ischemia and implies compromised circulation, despite the rich vascular supply of the stomach. In addition, the distribution of gas becomes important, given that a bullous pattern is related to benign conditions, whereas a linear pattern is related to more dangerous entities<sup>4,5</sup>.

A 57-year-old man with diabetes and high blood pressure, who quit smoking, was admitted to the hospital due to changes in the color of the toes on his right foot, prolonged capillary refill time, local hypothermia, and necrotic zones with no signs of infection. Diabetic foot (PEDIS classification grade 4) and chronic kidney disease were diagnosed. During hospitalization, the patient presented with absence of metabolic control and he developed acidosis. Peritoneal dialysis was begun, with the percutaneous placement of a Tenckhoff catheter. Due to drainage of turbid fluid, antibiotic therapy with ceftriaxone and clindamycin was administered. The patient presented with abdominal pain, a positive rebound sign, reduced peristalsis, and hypotension. Given the suspicion of intestinal infection, the drug regimen was changed to meropenem, fungal prophylaxis, and metronidazole. A computed tomography scan identified emphysematous gastritis and free air in the cavity (Fig. 1). Laboratory tests were ordered (Table 1) and an exploratory laparotomy was performed. During the event, purulent fluid was drained from the abdominal cavity. Multiple adhesions were observed in the cardia and removed. Areas of necrosis were also identified from the pylorus to the esophagus. An orogastric tube was placed and the gastric content was aspirated, partially improving perfusion. The washout was continued with warm solutions. Due to the critical status of the patient that persisted with hypotension and hypoglycemia, the decision was made to end the surgical act for maximum benefit. However, the patient continued to present with shock and lack of metabolic control, and voluntary discharge by family request was granted.

The finding of emphysematous gastritis was conclusive for diagnosing gastric ischemia caused by celiac trunk throm-

**Table 1** Laboratory tests before and after the exploratory laparotomy.

Test	Preoperative	Postoperative
<i>Complete blood count</i>		
Hemoglobin (g/dl)	8.9	8.2
Hematocrit (%)	29.7	27.4
Leukocytes (K/ul)	11.4	8.93
Neutrophils (K/ul)	10.0	8.3
Platelets (K/ul)	274.0	293.00
<i>Blood chemistry</i>		
Uric acid (mg/dl)	–	6.0
Ureic nitrogen (mg/dl)	78.0	77.0
Creatinine (mg/dl)	5.5	5.5
Urea (mg/dl)	167.0	165.0
Albumin (g/dl)	1.7	1.8
<i>Serum electrolytes</i>		
Na <sup>+</sup> (mmol/l)	132.0	130
K <sup>+</sup> (mmol/l)	2.9	3.6
Cl <sup>-</sup> (mmol/l)	95.0	93.0

basis in our patient, who was diabetic and had high blood pressure. He also presented with grade 5 chronic kidney disease, which produces a hypercoagulable state. There are factors in intestinal necrosis that provide information that increases the probability of making the correct diagnosis and defining the management to be carried out and they include arterial hypertension, dyslipidemia, a history of myocardial ischemia or ischemia of the extremities, organ failure, leukocytosis, elevated serum lactate, alterations in intestinal wall thickness, and intestinal segment dilation. Those factors increase the probability of death, which reaches up to 40% when 3 of said factors are present<sup>2,4,7</sup>. Drucker et al. reported that pneumatosis can be associated with ischemia and it can be accompanied by the tomographic identification of air in the portal vein<sup>8</sup>, which is a datum that should be consciously looked for. Unfortunately, our patient did not present with it<sup>2,4</sup>, and the pneumatosis had a linear distribution that was not of much help in determining the management to follow, given that it presented in the stomach<sup>9</sup>. Treatment can be surgical or conservative, with the correction of any fluid and electrolyte imbalance.

Drucker et al. presented a case in which hydrating the patient and placing a nasogastric tube was the preferred treatment<sup>10</sup>, albeit surgical intervention can also be an option. In the study by Spektor et al., they found that gastric pneumatosis plus elevated serum creatinine and lactic acid levels were associated with higher mortality, and so those elements should be taken into account in the management decision<sup>3,9</sup>. Nevertheless, it is necessary to evaluate the status of each patient and be aware that the extension of the ischemia, risk factors, and tomographic findings play a role in deciding on the treatment to be followed<sup>2,3,9</sup>.

## Funding

There was no source of funding.

## Conflict of interests

The authors declare that they have no conflict of interest.

## References

1. Sharma A, Mukewar S, Chari ST, et al. Clinical features and outcomes of gastric ischemia. *Dig Dis Sci*. 2017;62:3550–6, <http://dx.doi.org/10.1007/s10620-017-4807-4>.
2. Ibrahim A, Edirimanne S. Portal venous gas and pneumatosis intestinalis: ominous findings with an idiopathic aetiology. *J Surg Case Rep*. 2019;2019:1–3, <http://dx.doi.org/10.1093/jscr/rjy352>.
3. Spektor M, Chernyak V, McCann TE, et al. Gastric pneumatosis: laboratory and imaging findings associated with mortality in adults. *Clin Radiol*. 2014;69:e445–9, <http://dx.doi.org/10.1016/j.crad.2014.07.007>.
4. Goyal R, Lee HK, Akerman M, et al. Clinical and imaging features indicative of clinically worrisome pneumatosis: key components to identifying proper medical intervention. *Emerg Radiol*. 2017;24:341–6, <http://dx.doi.org/10.1007/s10140-017-1484-8>.
5. Manrique-Mendoza AR, Echavarría-Cadena AM, Pérez-Becerra NM, et al. Neumatosis intestinal, un hallazgo

- intraoperatorio inusual. *Rev Fac Med*. 2017;65:687–91, <http://dx.doi.org/10.15446/revfacmed.v65n4.59471>.
6. Takase A, Akuzawa N, Naitoh H, et al. Pneumatosis intestinalis with a benign clinical course: a report of two cases. *BMC Res Notes*. 2017;10:319, <http://dx.doi.org/10.1186/s13104-017-2647-0>.
7. Nuzzo A, Maggiori L, Ronot M, et al. Predictive factors of intestinal necrosis in acute mesenteric ischemia: prospective study from an intestinal stroke center. *Am J Gastroenterol*. 2017;112:597–605, <http://dx.doi.org/10.1038/ajg.2017.38>.
8. Drucker NA, Marine MB, Rescorla FJ. Gastric pneumatosis: an unusual presentation of superior mesenteric artery syndrome. *J Pediatr Surg Case Rep*. 2018;36:25–7, <http://dx.doi.org/10.1016/j.epsc.2018.06.014>.
9. Treyaud M-O, Duran R, Zins M, et al. Clinical significance of pneumatosis intestinalis - correlation of MDCT-findings with treatment and outcome. *Eur Radiol*. 2017;27:70–9, <http://dx.doi.org/10.1007/s00330-016-4348-9>.
10. Chen H, Wu Q, Fang H, et al. Intestinal necrosis cannot be neglected in a patient with hepatic portal vein gas combined with appendicitis: a rare case report and literature review. *BMC Surg*. 2019;19:17, <http://dx.doi.org/10.1186/s12893-019-0478-8>.

C.L. González-Palacio<sup>a</sup>, C.E. Venegas-Yáñez<sup>a</sup>,  
L.B. Enríquez-Sánchez<sup>b,\*</sup>, M.J. Carrillo-Gorena<sup>b</sup>,  
A. Aguirre-Baca<sup>c</sup>

<sup>a</sup> *Departamento de Cirugía General, Hospital Central del Estado, Chihuahua, Mexico*

<sup>b</sup> *División Quirúrgica, Hospital Central del Estado, Chihuahua, Mexico*

<sup>c</sup> *Universidad Autónoma de Chihuahua, Facultad de Medicina y Ciencias Biomédicas, Chihuahua, Mexico*

\*Corresponding author at: Hospital Central del Estado de Chihuahua, Antonio Rosales, 3302 Col. Obrera. C.P. 31350, Chihuahua, Chih, Mexico. Tel: +52 1 614 218 5442.

*E-mail address:* [investigacionhcu@gmail.com](mailto:investigacionhcu@gmail.com)  
(L.B. Enríquez-Sánchez).

2255-534X/ © 2021 Asociación Mexicana de Gastroenterología. Published by Masson Doyma México S.A. This is an open access article under the CC BY-NC-ND license (<http://creativecommons.org/licenses/by-nc-nd/4.0/>).

## Small bowel volvulus after laparoscopic appendectomy<sup>☆</sup>



## Vólvulo de intestino delgado tras apendicectomía laparoscópica

Small bowel volvulus (SBV) is defined as the torsion of a small bowel loop around its mesentery axis. It may result in partial or complete obstruction. That condition after laparoscopic

appendectomy has rarely been described. The diagnosis of SBV may be suggested by an abdominal computed tomography (CT) scan that shows the “whirlpool sign”, which is caused by twisting of the small bowel, mesentery, and mesenteric vessels<sup>1</sup>.

A 19-year-old man with no past medical history was admitted to the emergency department on postoperative day 6, after an uneventful laparoscopic appendectomy for a suppurative appendix. The appendectomy was performed with a 3-trocar technique and the appendiceal stump and mesoappendix were secured with an EndoGIA<sup>TM</sup> stapler (Ethicon Endosurgery, Cincinnati, OH, USA), with no complications. The patient presented with severe diffuse abdominal pain, accompanied by nausea, with no vomiting. Physical examination revealed normal vital signs, mild diffuse abdominal tenderness, and reduced bowel sounds.

<sup>☆</sup> Please cite this article as: González-Urquijo M, Quevedo-Fernández E, Morales-Morales CA, Alejandro-Rodríguez H, Leyva-Alvizo A. Vólvulo de intestino delgado tras apendicectomía laparoscópica. *Revista de Gastroenterología de México*. 2021;86:445–448.