



REVISTA DE GASTROENTEROLOGÍA DE MÉXICO

www.elsevier.es/rgmx



CLINICAL IMAGE IN GASTROENTEROLOGY

Multiple biliary hamartomatosis: «Starry sky» image[☆]

Hamartomatosis biliar múltiple: «imagen en cielo estrellado»

M. Bravo-Acosta^{a,*}, J. Rosendo-Namías^b, D. Martínez-Méndez^c

^a Servicio de Medicina Interna, Hospital General Guasmo Sur, Guayaquil, Ecuador

^b Servicio de Medicina Interna y Cirugía, Hospital Provincial de Ovalle «Dr. Antonio Tirado Lanás», Ovalle, Chile

^c Malongo Clinic, Cabinda, Angola

Multiple biliary hamartomas (MBHs), or the von Meyenburg complexes, are cystic malformations of the small interlobular bile ducts that arise from the cranial portion of an endodermal diverticulum during embryologic development. Prevalence is under 1%, with few cases described, and they can be confused with other cystic liver tumors. MBHs are generally asymptomatic and benign but can be associated with cholangiocarcinoma, thus CA 19-9 determination and lesion follow-up are recommended.

A 49-year-old woman with an unremarkable medical history, was asymptomatic and had normal liver function tests. She presented with multiple small liver lesions, with low attenuation, as an incidental finding on the upper abdominal axial projection of a chest computed tomography (CT) scan (Fig. 1). Abdominal magnetic resonance imaging (MRI) and magnetic resonance cholangiopancreatography (MRCP) identified numerous round lesions, 2 × 2 mm to 15 × 12 mm in diameter, hypointense on T1, hyperintense on T2, not communicating with the biliary tree (Fig. 2a and b). The lesions were evenly dispersed in both liver lobes, with a starry sky appearance (Fig. 3). Given the clinical character-

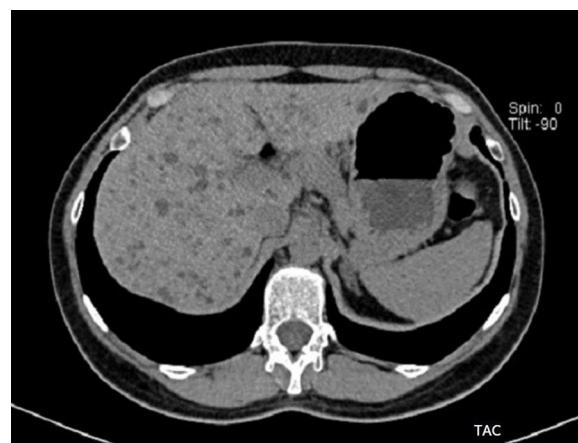


Figure 1 Computed tomography: Axial view of the upper abdomen showing multiple small, low-attenuation liver lesions.

istics and typical MR and MRCP images, the diagnosis of MBH was made. No histologic confirmation was requested.

Ethical considerations

The authors declare that they followed the protocols regarding the publication of patient data, guaranteeing anonymity, and that none of the images or text includes data that could identify the patient.

The authors declare that even though no personal data that could identify the patient were published in the present article, informed consent was obtained from the patient,

[☆] Please cite this article as: Bravo-Acosta M, Rosendo-Namías J, Martínez-Méndez D. Hamartomatosis biliar múltiple: «imagen en cielo estrellado». Revista de Gastroenterología de México. 2021;86:191–192.

* Corresponding author at: Médico especialista en Medicina Interna y Neumología, Servicio de Medicina Interna, Hospital General Guasmo Sur, Guayaquil, Ecuador.

E-mail address: mariolgabravo@gmail.com (M. Bravo-Acosta).

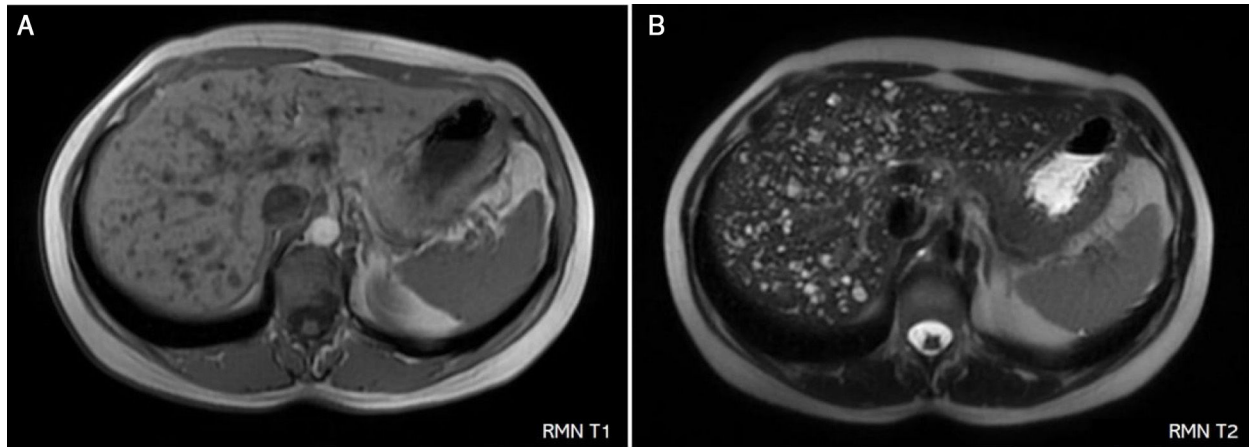


Figure 2 Abdominal magnetic resonance imaging: Numerous round lesions, hypointense on T1 (2a) and hyperintense on T2 (2b).

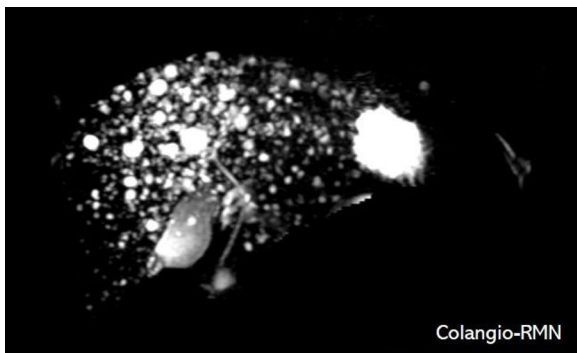


Figure 3 Magnetic resonance cholangiopancreatography: Multiple small lesions evenly dispersed in both liver lobes, with a "starry sky" appearance.

and the document is in the possession of the corresponding author.

Financial disclosure

No financial support was received in relation to this article.

Conflict of interest

The authors declare that there is no conflict of interest.