

should be carried out, given that primary sclerosing cholangitis is considered a rare extradigestive manifestation in Crohn's disease.

Ethical disclosures

The authors declare that no experiments were performed on humans or animals for this study.

The authors declare that they have treated all patient data with confidentiality and anonymity, following the protocols of their work center.

Informed consent was not requested for the publication of this case because the article contains no personal data that could identify the patient.

Financial disclosure

No financial support was received in relation to this study/article.

Conflict of interest

The authors declare that they have no conflict of interests.

References

- Xu-Ting Z, Jian-Guo H, Tao L, et al. Gastric Crohn's Disease : A Rare Cause of Intermittent Abdominal Pain and Vomiting. *Am J Med.* 2017;130:181–5.
- Torres J, Mehandru S, Colombel J, et al. Crohn's disease. *Lancet.* 2016;6736:1–15.
- Ingle S, Hinge C, Dakhure S, et al. Isolated gastric Crohn's disease. *World J Clin Cases.* 2013;1:71–3.
- Tremaine WJ. Gastroduodenal Crohn's disease: medical management. *Inflamm Bowel Dis.* 2003;9:127–8.
- Annunziata ML, Caviglia R, Papparella LG, et al. Upper Gastrointestinal Involvement of Crohn's Disease : A Prospective Study on the Role of Upper Endoscopy in the Diagnostic Work-Up. *Dig Dis Sci.* 2012;1618–23.
- van Hogezaand RA, Witte AM, Veenendaal RA, et al. Proximal Crohn's Disease : Review of the Clinicopathologic Features and Therapy. *Inflamm Bowel Dis.* 2001;7:328–37.
- Kefalas C. Gastroduodenal Crohn's disease. *BUMC Proc.* 2003;16:147–51.
- Mejía-Rivas M, Yamamoto-Furusho J, Remes-Troche JM, et al. Enfermedad de Crohn del tubo digestivo proximal. Una presentación rara de una enfermedad poco común en México. *Rev Gastroenterol Mex.* 2009;74:111–4.
- Betancur Salazar^a, G. Mosquera-Klinger^{b,*}

^a Universidad Pontificia Bolivariana, Medellín, Colombia

^b Unidad de Gastroenterología y Endoscopia Digestiva, Hospital Pablo Tobón Uribe, Medellín, Colombia

* Corresponding author at: calle 78B # 69-240, Hospital Pablo Tobón Uribe, Consultorio 149, número 4459000, Medellín, Colombia.

E-mail address: gami8203@yahoo.com

(G. Mosquera-Klinger).

2255-534X/ © 2019 Asociación Mexicana de Gastroenterología. Published by Masson Doyma México S.A. This is an open access article under the CC BY-NC-ND license (<http://creativecommons.org/licenses/by-nc-nd/4.0/>).

Acute diverticulitis of the hepatic flexure mimicking acute cholecystitis[☆]



Diverticulitis aguda del ángulo hepático simulando un cuadro de colecistitis aguda

We present herein the case of a 56-year-old man, with an unremarkable past medical history, who came to the emergency room complaining of abdominal pain of 3-day progression in the right hypochondrium. It began insidiously, with an intensity of 8/10, and was accompanied by abdominal bloating, hyporexia, and nausea. He did not present with vomiting, fever, or jaundice. The pain had no aggravating factors and partially improved with antispasmodics. Physical examination revealed reduced peristalsis, abdominal distension due to bloating, pain in the right hypochondrium upon palpation, and a positive Murphy's sign.

The patient's hemoglobin level was 12.4 g/dl, platelets 336,000 cells/mm³, leukocytes 16,400 cells/mm³, and unaltered liver function tests. An upper abdominal ultrasound study identified a distended gallbladder with biliary sludge and a 3 mm wall, a bile duct diameter of 5.5 mm, and the remaining parameters within normal limits. Because the pain continued, a computed axial tomography (CAT) scan with intravenous contrast medium was carried out (Fig. 1). Whether the CAT images were caused by colonic pathology or by gallbladder pathology could not be accurately determined. Initial management was conservative, with bowel rest, analgesics, and double-regimen antibiotic therapy with ciprofloxacin and metronidazole for 7 days. The patient improved and was released under oral treatment with the same antibiotics for another 7 days. Six weeks later, a control CAT scan was performed that showed complete resolution of the perivesicular and pericolonic inflammation. The patient was asymptomatic at one month, then at 12 months, after his original symptoms.

The present case is a rare variant of diverticular disease, given that the most commonly affected site is the sigmoid colon in white patients and the right colon in Asians.¹ Three main factors are known to cause diverticular disease: disordered intestinal motility, a low-fiber diet, and intestinal wall abnormalities.²

[☆] Please cite this article as: Gonzalez-Urquijo M, Baca-Arzaga A, Lozano-Balderas G. Diverticulitis aguda del ángulo hepático simulando un cuadro de colecistitis aguda. *Revista de Gastroenterología de México.* 2020;85:484–486.

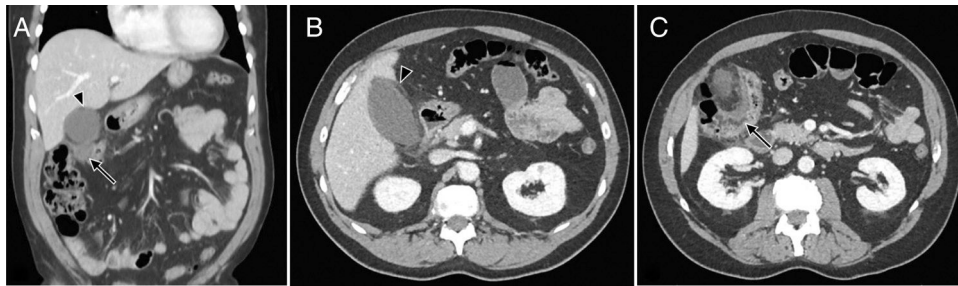

Figure 1 A. Coronal view, the presence of pericholecystic inflammatory changes (arrowhead) and a pericolonic phlegmon (arrow), B. Axial view, perivesicular inflammatory changes, fat stranding at that level, data that could suggest acute cholecystitis, C. Axial view, thickening of the colonic wall of the hepatic flexure and pericolonic fat stranding, with active diverticular disease.

Diverticular disease in the transverse colon or hepatic flexure, first described in 1944 by Thompson and Fox, is extremely infrequent.³ It accounts for only 5 to 10% of all diverticulitis in the large intestine. Inflammation or perforation of the diverticula in that zone is very rare, occurring in only 0.5-2.7% of cases.⁴ The most commonly related presumptive diagnosis in patients with diverticular disease of the right colon is acute appendicitis, with some published case reports.⁵ Even less frequent is a clinical picture similar to that of acute cholecystitis secondary to diverticulitis of the right colon or transverse colon, as in our patient, and we know of the report of only one such case.⁴ To confirm the diagnosis, computed tomography must show thickening of the colonic wall and an increase in the density or stranding of the pericolonic fat, as well as possible pericolonic abscesses and intramural and extraluminal air.⁶ The first 3 characteristics were observed in the CAT scan of our patient, which, added to the intramural air, resulted in the definitive diagnosis. Some studies indicate that diverticulitis of the right colon is more benign than that of the left colon. Surgical management is extremely rare and antibiotic therapy is the treatment of choice in such cases.⁷ Successful management has even been reported with bowel rest and hydration, with no need for antibiotic therapy.⁸ The majority of patients that have an episode of acute diverticulitis will not have a new episode throughout their lifetime and only around 20% of patients will have disease recurrence at 5 years.⁹ Specifically in diverticulitis of the right colon, Wegdam et al. reported 7% recurrence at 7 years of follow-up.⁷ Our patient recovered completely with conservative treatment, and at the time of writing this report, has not had a relapse of the disease.

The clinical diagnosis of acute diverticulitis is a challenge in cases such as the one presented herein. Even though it is uncommon, our case shows the importance of considering diverticulitis of the right colon or the transverse colon in the differential diagnoses for acute cholecystitis. In patients that present with abdominal pain in the right upper quadrant, but with symptoms that do not concur with hepatobiliary pathology, CAT imaging can be the first-line study for making the diagnosis. Likewise, that imaging method is very capable of showing the segmental thickness of the intestinal wall, stricture zones, and the complications of fistulas and abscesses. In addition, it possesses multi-plane reconstruction algorithms that enable better evaluation of the anatomic changes of the gastrointestinal tract and other abdominal organs.¹⁰

Finally, it is important to emphasize the adequate response to conservative management that has presented in other cases, as in our patient, preventing the morbidity and mortality of surgical management.

Ethical disclosures

Protection of human and animal subjects. The authors declare that no experiments were performed on humans or animals for this study.

Confidentiality of data. The authors declare that they have treated all patient data with confidentiality and anonymity, following the protocols of their work center.

Right to privacy and informed consent. The authors declare that no patient data appear in this article.

Right to privacy and informed consent. The authors have obtained the written informed consent of the patients or subjects mentioned in the article. The corresponding author is in possession of this document.

Financial disclosure

No specific grants were received from public sector agencies, the business sector, or non-profit organizations in relation to this study.

Conflict of interest

The authors declare that there is no conflict of interest.

References

1. Kim MR, Kye B-H, Kim HJ, et al. Treatment of right colonic diverticulitis: the role of nonoperative treatment. *J Korean Soc Coloproctol.* 2011;26:402-6.
2. Hayes C, Coombs P, Ptasznik R. Acute right upper quadrant diverticulitis: an unusual sonographic finding in a young adult patient. *Sonography.* 2015;2:61-4.
3. Thompson GF, Fox PF. Perforated solitary diverticulum of the transverse colon: case report. *Am J Surg.* 1944;66:280-3.
4. González Chávez AM, Garcia Vazquez A, Álvarez-Hernández DA, et al. Acute perforated transverse colon diverticulitis simulating acute cholecystitis: case report and literature review. *Int Surg J.* 2017;4:3756-9.
5. Radhi J, Ramsay J, Boutross-Tadross O. Diverticular disease of the right colon. *BMC Res Notes.* 2011;4:383.
6. Lee IK. Right colonic diverticulitis. *J Korean Soc Coloproctol.* 2010;26:241-5.

7. Wegdam JA, Andeweg CS, Vuuren TMAJ, et al. Disease course of right- and left-sided diverticulitis in a western population. *J Gastrointest Dig Syst.* 2016;6:6–11.
8. Oudenhoven LF, Koumans RK, Puylaert JB. Right colonic diverticulitis: US and CT findings-new insights about frequency and natural history. *Radiology.* 2014;208:611–8.
9. Stollman N, Smalley W, Hirano I. American Gastroenterological Association Institute guideline on the management of acute diverticulitis. *Gastroenterology.* 2015;149:1944–9.
10. Álvarez Rosell E, Ramírez Navarro SV, Paradela Ferrera C, et al. La tomografía computarizada en la evaluación de la afección inflamatoria intestinal. *Rev Haban Cienc Méd.* 2013;12:438–45.

M. Gonzalez-Urquijo, A. Baca-Arzaga, G. Lozano-Balderas*

Escuela de Medicina y Ciencias de la Salud, Tecnológico de Monterrey, Monterrey, Nuevo León, Mexico

* Corresponding author at: Dr. Ignacio Morones Prieto O 3000. 64710 Monterrey, Mexico. Tel.: 8180201379.

E-mail address: glozanob@gmail.com (G. Lozano-Balderas). 2255-534X/ © 2019 Asociación Mexicana de Gastroenterología. Published by Masson Doyma México S.A. This is an open access article under the CC BY-NC-ND license (<http://creativecommons.org/licenses/by-nc-nd/4.0/>).

Nonoperative management in a patient with moderate blunt liver trauma[☆]



Manejo no operatorio en un paciente con traumatismo hepático contuso de grado moderado

The liver parenchyma and its vascularization are fragile structures that are commonly injured in blunt abdominal trauma. Isolated liver injury management has undergone important modifications and is constantly evolving. While surgical examination remained the gold standard during the past century and beginnings of the present, the current tendency is nonoperative management or selective liver resections. Imaging study findings or the volume of the hemoperitoneum no longer determine the choice of management of those injuries,^{1,2} whereas hemodynamic stability,

eters that more reliably reflect the clinical status of the patient.³ Presented herein is the clinical case of a high-grade liver injury and its successful nonoperative management.

A 16-year-old male with an unremarkable past medical and surgical history suffered blunt abdominal trauma after a bicycle accident, in which the upper quadrants of the abdomen were injured by the handlebar. The patient did not lose consciousness. Upon arrival at the emergency department he was hemodynamically stable, and his physi-

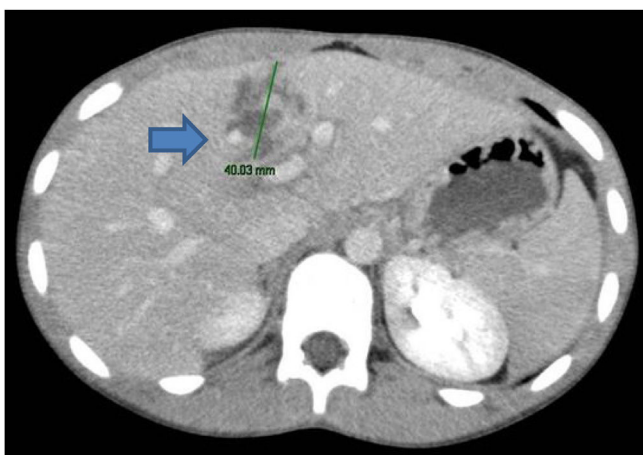

Figure 1 Axial view (CAT) showing the 4 cm laceration in the parenchyma of segment IVb.

coagulopathy grade, hypothermia, and acidosis are param-

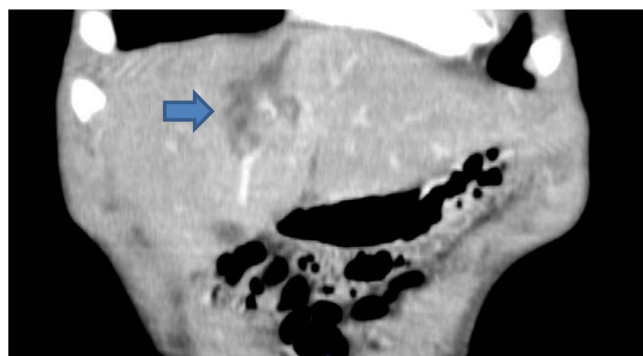


Figure 2 Coronal view (CAT) showing the laceration in segments IVa and IVb.

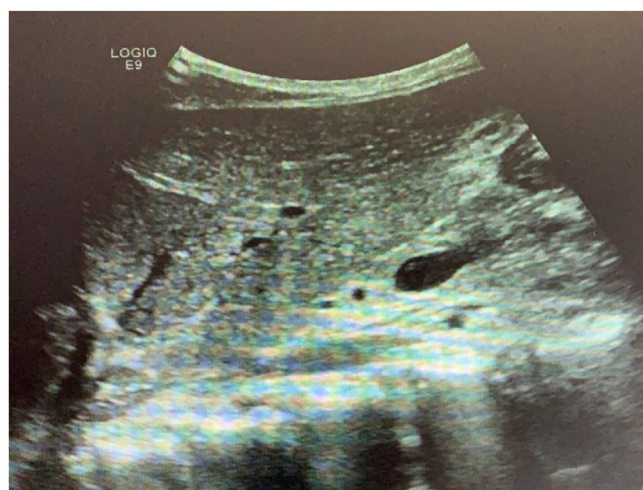

Figure 3 Control ultrasound image before hospital release.

ologic parameters were within the normal range. Physical

[☆] Please cite this article as: Pérez-Alonso A, Rodríguez-Martinón P, Caballero-Marcos L, Petrone P. Manejo no operatorio en un paciente con traumatismo hepático contuso de grado moderado. *Revista de Gastroenterología de México.* 2020;85:486–490.