

15. Brillantino A, Iacobellis F, Festa P, et al. Non-operative management of blunt liver trauma: safety, efficacy and complications of a standardized treatment protocol. *Bull Emerg Trauma*. 2019;7:49–54.
  16. Saltzherr TP, van der Vlies CH, van Lienden KP, et al. Improved outcomes in the non-operative management of liver injuries. *HPB (Oxford)*. 2011;13:350–5.
  17. Leppäniemi A. Nonoperative management of solid abdominal organ injuries: from past to present. *Scand J Surg*. 2019;108:95–100, <http://dx.doi.org/10.1177/1457496919833220>.
  18. Pachter HL, Knudson MM, Esrig B, et al. Status of nonoperative management of blunt hepatic injuries in 1995: a multicenter experience with 404 patients. *J Trauma*. 1996;40:31–8.
  19. van der Vlies CH, Hoekstra J, Ponsen KJ, et al. Impact of artery embolization on the success rate of nonoperative management for blunt injury. *Cardiovasc Intervent Radiol*. 2012;35:76–81.
  20. Croce MA, Fabian TC, Menke PG, et al. Nonoperative management of blunt hepatic trauma is the treatment of choice for hemodynamically stable patients. Results of a prospective trial. *Ann Surg*. 1995;221:744–55.
  21. Asensio JA, Roldán G, Petrone P, et al. Operative management and outcomes in 103 AAST-OIS grades IV and V complex hepatic injuries: trauma surgeons still need to operate, but angioembolization helps. *J Trauma*. 2003;54:647–53.
  22. Fodor M, Primavesi F, Morell-Hofert D, et al. Non-operative management of blunt hepatic and splenic injury: a time-trend and outcome analysis over a period of 17 years. *World J Emerg Surg*. 2019;14:29.
  23. Asensio JA, Petrone P, Roldán G, et al. Has evolution in awareness of guidelines for institution of damage control improved outcome in the management of the post-traumatic open abdomen? *Arch Surg*. 2004;139:209–14.
  24. Asensio JA, Verde JM, Petrone P, et al. Massive hepatic hemorrhage: initial steps in hemostasis. In: Ivatury RR, editor. *Operative Techniques for Severe Liver Injury*. New York: Springer; 2015. p. 41–56.
  25. Vyhnanek F, Denmark L, Duchác V. Current diagnostic and therapeutic approaches in liver injuries. *Acta Chir Orthop Traumatol Cech*. 2003;70:219–25. PMID: 14569858.
- A. Pérez-Alonso<sup>a</sup>, P. Rodríguez-Martinón<sup>b</sup>,  
L. Caballero-Marcos<sup>c</sup>, P. Petrone<sup>b,\*</sup>
- <sup>a</sup> *Unidad de Cirugía Hepatobiliopancreática, Complejo Hospitalario de Jaén, Departamento de Cirugía y sus Especialidades, Universidad de Granada, Jaén, Spain*  
<sup>b</sup> *Department of Surgery, NYU Langone Health, NYU Winthrop Hospital, Mineola, New York, United States*  
<sup>c</sup> *Servicio de Urgencias, Hospital de Alta Resolución de Alcalá La Real, Jaén, Spain*
- \*Corresponding author at: Director of Surgical Research, Program Director, International Research Fellowship, Department of Surgery - NYU Winthrop Hospital, Associate Professor of Surgery, NYU Long Island School of Medicine 222 Station Plaza North, Suite 300, Mineola, Long Island, New York 11501, United States.  
*E-mail addresses:* [patrizio.petrone@nyulangone.org](mailto:patrizio.petrone@nyulangone.org), [patrizio.petrone@gmail.com](mailto:patrizio.petrone@gmail.com) (P. Petrone).  
 2255-534X/ © 2020 Asociación Mexicana de Gastroenterología.  
 Published by Masson Doyma México S.A. This is an open access article under the CC BY-NC-ND license (<http://creativecommons.org/licenses/by-nc-nd/4.0/>).

## Video capsule endoscopy in the diagnosis of Peutz-Jeghers syndrome<sup>☆</sup>



### Videocápsula endoscópica en el diagnóstico del síndrome de Peutz-Jeghers

Video capsule endoscopy (VCE) is a diagnostic technique utilized in the majority of polyposis syndromes to detect lesions in the small bowel.<sup>1</sup>

We present herein the case of a 66-year-old man who sought medical attention for subocclusive symptoms presenting over the last few months, that alternated with periods of no symptoms. VCE was performed as soon as the patient presented with a low probability of obstruction, observing numerous polyps of different size and stage that extended from the antrum to the colon (Fig. 1A–C). The study was completed through colonoscopy, with the extirpa-

tion of several of the polyps. The histologic analysis stated hamartomatous polyps. The patient is currently in follow-up with endoscopic examinations and periodic polypectomies,<sup>2</sup> including resection of jejunal polyps with a double balloon enteroscope.

According to the literature, one of the indications for VCE is the diagnosis of small bowel polyposis syndromes, as in the present case. That diagnostic method has shown greater sensitivity than other imaging studies and a similar detection rate to that of double balloon enteroscopy, as well as a low complication rate. However, VCE has a series of disadvantages with respect to imaging studies, such as interobserver variability in its interpretation and its limitation for determining lesion size. In the present case, we wish to emphasize the role of VCE as a simple, efficacious, radiation-free diagnostic method, with a low complication rate, in the study of patients with gastrointestinal polyposis syndromes. Evaluation is later completed with more specific techniques, enabling the most accurate diagnosis possible.

<sup>☆</sup> Please cite this article as: García-Márquez J, Valenzuela-de Damas M, Caballero-Mateos AM. Videocápsula endoscópica en el diagnóstico del síndrome de Peutz-Jeghers. *Revista de Gastroenterología de México*. 2020;85:490–491.

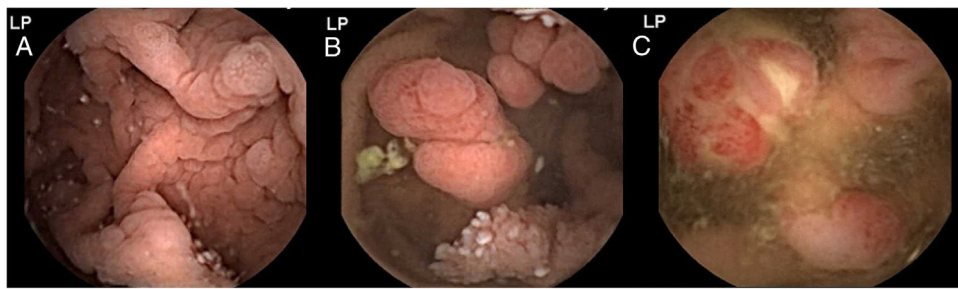


Fig. 1 A-C) Images from the VCE study showing numerous polyps of different size and stage in the antrum, jejunum, and colon, respectively.

## Ethical disclosures

The authors declare they have complied with all the ethical responsibilities regarding data protection, the right to privacy, and informed consent.

## Financial disclosure

No financial support was received from any source in relation to the present article.

## Conflict of interest

The authors declare that there is no conflict of interest.

## References

1. Beggs A, Latchford A, Vasen H, et al. Peutz-Jeghers syndrome: a systematic review and recommendations for management. *Gut*. 2010;59:975–86.

2. Tomas C, Soyer P, Dohan A, et al. Update on imaging of Peutz-Jeghers syndrome. *World J Gastroenterol*. 2014;20:10864–75.

J. García-Márquez<sup>a,\*</sup>,  
M. Valenzuela-de Damas<sup>b</sup>,  
A.M. Caballero-Mateos<sup>a</sup>

<sup>a</sup> Hospital Universitario San Cecilio, Granada, Spain

<sup>b</sup> Hospital Universitario Virgen Macarena, Sevilla, Spain

\*Corresponding author. Hospital Universitario San Cecilio, Avenida de la Investigación s/n, 18016, Granada, Spain. Phone: 618242443.

E-mail address: [joagarmar@hotmail.com](mailto:joagarmar@hotmail.com) (J. García-Márquez).

6 September 2019 31 October 2019

2255-534X/ © 2019 Asociación Mexicana de Gastroenterología.

Published by Masson Doyma México S.A. This is an open access article under the CC BY-NC-ND license (<http://creativecommons.org/licenses/by-nc-nd/4.0/>).

## Stricturing ulcerative colitis: a case of rapid disease progression<sup>☆</sup>



### Colitis ulcerosa con estenosis: un caso de progresión rápida de la enfermedad

Ulcerative colitis (UC) is considered an idiopathic disease of the large bowel that consists of chronic mucosal inflammation due to a complex interaction between genetic predisposition and environmental factors. Worldwide incidence is reported to have plateaued in North America (19.2 per 100,000 person-years) and Europe (24.3 per 100,000 person-years), whereas low incidence regions, specifically in developing countries, appear to have experienced an increase in inflammatory bowel disease (IBD) that is most likely due to industrialization.<sup>1</sup> Epidemiologic data on UC

are scarce in those countries, as they are in Mexico. In a recently published nationwide cohort study, encompassing more than 15 years (2000-2017), incidence was reported at 0.16 per 100,000 person-years and prevalence at 1.45 per 100,000 person-years for UC in Mexico, revealing a 5.3-fold increase.<sup>2</sup> The extent and clinical course of the disease can vary, ranging from rectal involvement to pancolitis in a continuous manner, and the disease is characterized by a relapsing and remitting course. The phenotype at diagnosis in patients with UC is generally split equally between proctitis, left-sided disease, and pancolitis. Both IBD subtypes, namely UC and Crohn's disease (CD), are chronic diseases consisting of chronic inflammation with subsequent constant tissue repair. CD presents with transmural disease with activation of mesenchymal cells and a subsequent stricturing disease course, whereas fibrosis and scar formation in long-standing UC is usually limited to the mucosa, including pseudopolyposis and bridging fibrosis.<sup>4</sup> An increased risk of colorectal cancer has been recognized for UC, in particular, with a cumulative incidence of 2% in 10 years, 8% in 20 years, and 18% in 30 years.<sup>5</sup> Those data highlight why neoplasia should be the primary suspicion when a colonic stricture is diagnosed. Nevertheless, in their original articles dating back to 1964, Edwards and Truelove reported benign stric-

<sup>☆</sup> Please cite this article as: Scharrer-Cabello SI, Baeza-Zapata AA, Herrera-Quñones G, Luna-Limón CG, Benavides-Salgado DE. Colitis ulcerosa con estenosis: un caso de progresión rápida de la enfermedad. *Revista de Gastroenterología de México*. 2020;85:491–493.