



REVISTA DE GASTROENTEROLOGÍA DE MÉXICO

www.elsevier.es/rgmx



CLINICAL IMAGE IN GASTROENTEROLOGY

Simultaneous detection of lower gastrointestinal bleeding and hepatic hemangioma in a scintigraphy study with red blood cells labeled with ^{99m}Tc -stannous pyrophosphate[☆]



Detección simultánea de hemorragia digestiva baja y hemangioma hepático en estudio gammagráfico con hematíes marcados con

E. Espinosa-Muñoz*, F.J. Ruíz-García, C. Puentes-Zarzuela

Unidad de Gestión Clínica de Medicina Nuclear, Hospital Regional Universitario de Málaga, Málaga, Spain

A 75-year-old woman, under study for signs and symptoms of microcytic hypochromic anemia of 3-year progression, was treated on several occasions with oral iron supplementation and blood transfusions. She presented with hemorrhoidal pathology and dark stools related to iron therapy. Her latest control laboratory work-up reported Hb 10 g/dl, MCV 72 f/l, iron 47 $\mu\text{g}/\text{dl}$, ferritin 250 ng/ml, vitamin B₁₂ 378 pg/ml, and folic acid 6 ng/ml. Upper gastrointestinal endoscopy revealed mild erythematous gastritis, with a large sliding hiatal hernia, and colonoscopy showed internal hemorrhoids and a spastic colon. There were no signs of active bleeding in either study. Due to the suspicion of occult bleeding, scintigraphy with red blood cell labeling with ^{99m}Tc -stannous pyrophosphate (Fig. 1A and B) and abdominal SPECT/CT

(Fig. 1C and D) were performed, identifying endoluminal radiotracer uptake at the distal end of the ascending colon consistent with low output bleeding. In addition, a rounded and well-delineated area of increased uptake in liver segment V that corresponded to a hemangioma was identified. The abdominal CT scan with iv contrast medium (Fig. 2) revealed the typical centripetally progressive enhancement pattern, supporting the diagnosis of hepatic hemangioma, with no signs of alterations in the intestinal segments. The patient was treated with 100 mg of trivalent iron for 2 weeks. The upper gastrointestinal endoscopy, barium transit, and colonoscopy were repeated and showed no significant alterations. The patient is currently asymptomatic, with stable Hb values in the control laboratory tests.

[☆] Please cite this article as: Espinosa-Muñoz E, Ruíz-García FJ, Puentes-Zarzuela C. Detección simultánea de hemorragia digestiva baja y hemangioma hepático en estudio gammagráfico con hematíes marcados con ^{99m}Tc -pirofosfato de estaño. Revista de Gastroenterología de México 2020;85:90–91.

* Corresponding author. Hospital Regional Universitario de Málaga, Avenida Carlos Haya, s/n 29010 Málaga, Spain. Tel.: 951291199. E-mail address: elenaespinosamunoz@gmail.com (E. Espinosa-Muñoz).

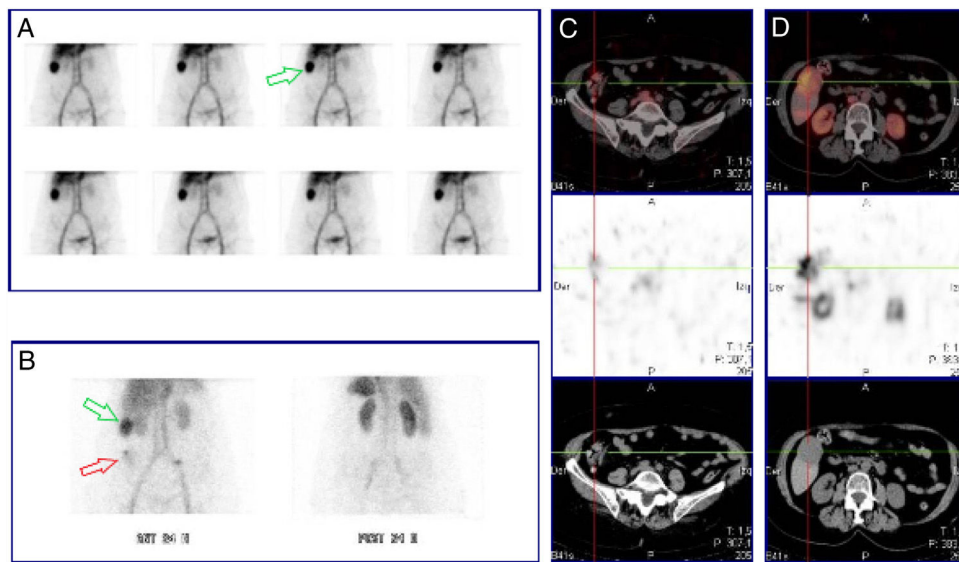


Figure 1 Scintigram with red blood cells labeled with ^{99m}Tc -stannous pyrophosphate, dynamic images during the course of one hour: physiologic distribution of the radiotracer, with no signs of bleeding foci. Morphologic nodular area of increased uptake in the right hypochondrium (green arrow) (A). Late images at 24h post-injection: area of increased uptake persists at the level of the right hypochondrium (green arrow). Newly appearing low intensity and diffuse uptake in the right iliac fossa (red arrow) (B). Abdominal SPECT/CT at 24h post-injection: endoluminal radiotracer uptake at the distal end of the ascending colon, increasing its activity over time, consistent with low output bleeding (C). Nodular image with increased uptake in liver segment V, indicative of a fixed vascular structure (hemangioma) (D).

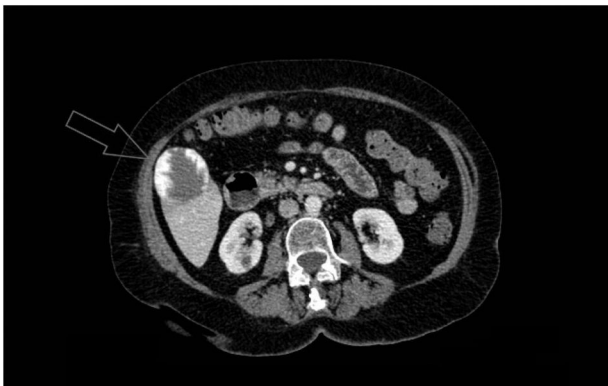


Figure 2 Axial view of the abdominal CT scan with iv contrast medium: focal lesion with peripheral nodular enhancement (approximately 5.1×4.6 cm) located in liver segment V, consistent with an exophytic hemangioma.

Ethical disclosures

Protection of human and animal subjects. The authors declare that no experiments were performed on humans or animals for this study.

Confidentiality of data. The authors declare that they have followed the protocols of their work center on the publication of patient data.

Right to privacy and informed consent. The authors have obtained the written informed consent of the patient to publish her data or subjects mentioned in the article, preserving absolute patient confidentiality and anonymity.

Authorship

All the authors have read and approved the manuscript and declare that the requisites for authorship have been met:

Concept and design of the manuscript: Elena Espinosa Muñoz.

Data collection: Elena Espinosa Muñoz.

Data analysis and interpretation: Elena Espinosa Muñoz, Francisco Javier Ruíz García.

Drafting, revision, and approval of the manuscript: Elena Espinosa Muñoz, Francisco Javier Ruíz García, and Carmen Puentes Zarzuela.

Financial disclosure

No specific grants were received from public sector agencies, the business sector, or non-profit organizations in relation to this study.

Conflict of interest

The authors declare that there is no conflict of interest.