

Conflict of interest

The authors declare that there is no conflict of interest.

References

1. European Food Safety Authority (EFSA) and European Centre for Disease Prevention and Control (ECDC). EU Summary Report on antimicrobial resistance in zoonotic and indicator bacteria from humans, animals and food in 2014. *EFSA J.* 2016;14:4380.
2. Osler W. The Gulstonian lectures, on malignant endocarditis. *Br Med J.* 1885;1:467–70.
3. Maeda H, Umezawa H, Goshima M, et al. Primary infected abdominal aortic aneurysm: surgical procedures, early mortality rates, and a survey of the prevalence of infectious organisms over a 30-year period. *Surg Today.* 2011;41:346–51.
4. Brown SL, Busuttill RW, Baker JD, et al. Bacteriologic and surgical determinants of survival in patients with mycotic aneurysms. *J Vasc Surg.* 1984;1:541–7.
5. Choi SJ, Lee JS, Cheong MH, et al. F-18 FDG PET/CT in the management of infected abdominal aortic aneurysm due to *Salmonella*. *Clin Nucl Med.* 2008;33:492–5.
6. Spacek M, Stadler P, Belohlávek O, et al. Contribution to FDG-PET/CT diagnostics and post-operative monitoring of patients with mycotic aneurysm of the thoracic aorta. *Acta Chir Belg.* 2010;110:106–8.
7. Davison JM, Montilla-Soler JL, Broussard E, et al. F-18 FDG PET-CT imaging of a mycotic aneurysm. *Clin Nucl Med.* 2005;30:483–7.
8. Sörelius K, Mani K, Björck M, et al. Endovascular treatment of mycotic aortic aneurysms: a European multicentre study. *Circulation.* 2014;130:2136–42.
9. Heinola I, Sörelius K, Wyss TR, et al. Open repair of mycotic abdominal aortic aneurysms with biological grafts: an international multicentre study. *J Am Heart Assoc.* 2018;7:e008104.
10. Forbes TL, Harding GE. Endovascular repair of *Salmonella*-infected abdominal aortic aneurysms: a word of caution. *J Vasc Surg.* 2006;44:198–200.

I. García-Fernández-Bravo^{a,*}, A. González-Munera^a,
L. Ordieres-Ortega^a, D. Ruiz Chiriboga^b
y M. González-Leyte^c

^a Servicio de Medicina Interna, Hospital General Universitario Gregorio Marañón, Madrid, España

^b Servicio de Angiología y Cirugía Vascul, Hospital General Universitario Gregorio Marañón, Madrid, España

^c Unidad de Radiología Vascul, Servicio de Radiodiagnóstico, Hospital General Universitario Gregorio Marañón, Madrid, España

* Corresponding author. Calle Bravo Murillo 53. Código postal: 28003, Madrid, Spain.

E-mail address: irenegfb@gmail.com

(I. García-Fernández-Bravo).

2255-534X/

© 2019 Asociación Mexicana de Gastroenterología. Published by Masson Doyma México S.A. This is an open access article under the CC BY-NC-ND license (<http://creativecommons.org/licenses/by-nc-nd/4.0/>).

Rectal tuberculosis: An uncommon clinical presentation and differential diagnosis with Crohn's disease[☆]



Tuberculosis rectal: presentación clínica infrecuente y diagnóstico diferencial con enfermedad de Crohn

Tuberculosis (TB) is an infectious disease caused by *Mycobacterium tuberculosis* and its most frequent location is the lung. In order of frequency, extrapulmonary TB can affect the lymph nodes, the genitourinary tract, the osteoarticular system, the meninges, and the digestive tract. Digestive involvement can present at any segment of the gastrointestinal tract, and most frequently affects the ileocecal region.^{1–3}

The clinical and endoscopic presentations of intestinal TB can be similar to those of other diseases, such as neoplasias and Crohn's disease (CD). Therefore, a high level of suspicion is required, as well as the performance of microbiologic

studies, to opportunely confirm the diagnosis. The differential diagnosis with CD can be difficult, especially in areas of endemic infection and in immunosuppressed patients, but it is important to make it, given that in the case of an erroneous diagnosis of CD, beginning immunosuppressant treatment could exacerbate the TB.^{1–4}

In Latin America, the incidence of TB in 2015 was 22 cases per 100,000 inhabitants. In Mexico, the figures were 17 cases per 100,000 inhabitants, signifying that the disease continues to be a public health problem. In Chile, the reported incidence of TB in 2014 was 12.3 cases per 100,000 inhabitants and 21.3% of the new cases were extrapulmonary TB. Coinfection due to HIV is one of the main risk factors for the development of the disease.^{5,6}

The clinical manifestation of TB depends on the intestinal segment involved and abdominal pain is described in 85% of the patients, weight loss in 66%, fever in 35–50%, and diarrhea in 20% of the cases. Cases with clinical pictures of bowel obstruction and massive gastrointestinal bleeding secondary to TB are reported in the literature.^{2,3,7}

TB affecting the rectum is rare, even in areas of high prevalence of the disease, such as Asia and Africa. Its clinical presentation can be rectal bleeding or diarrhea. Endoscopic study usually reveals a concentric stricture, suggesting the differential diagnosis with neoplasia and requiring endoscopic biopsy. Surgical resection for making the diagnosis has been reported in some cases.^{1–4,8}

[☆] Please cite this article as: Gompertz M, Carreño L, Gil La Rotta LC. Tuberculosis rectal: presentación clínica infrecuente y diagnóstico diferencial con enfermedad de Crohn. *Rev Gastroenterol Méx.* 2019;84:524–526.

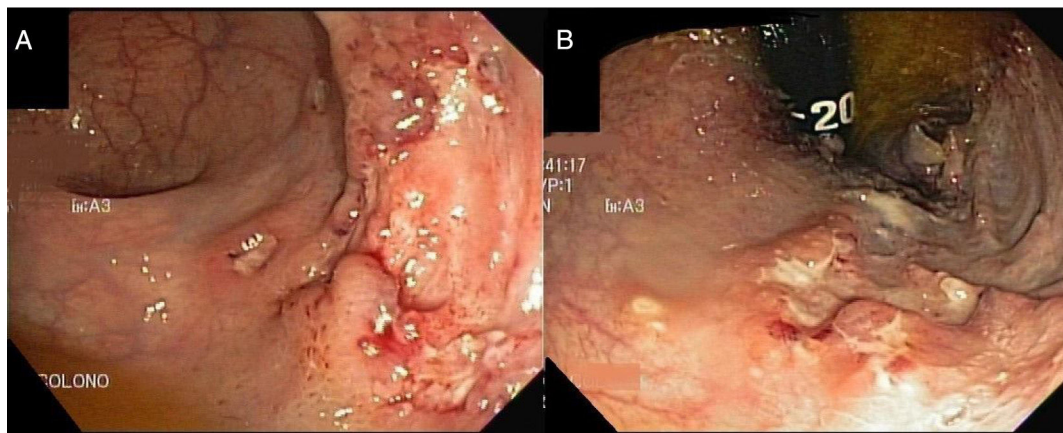


Figure 1 Colonoscopy: ulcerated rectal lesion with irregular edges. A) Frontal view of the rectal ulcer. B) Posterior view of the rectal ulcer.

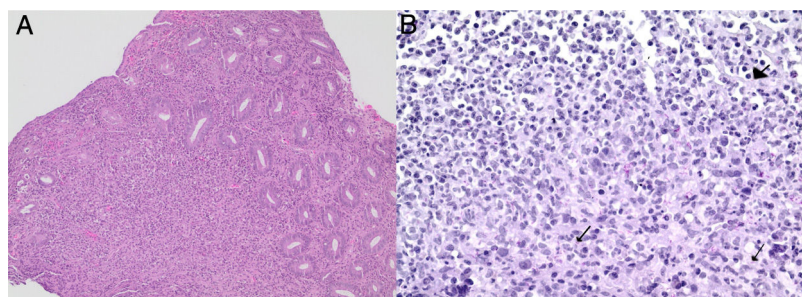


Figure 2 Histopathologic study of the ulcerated lesion. A) Mixed inflammatory infiltrate with hematoxylin and eosin stain ($\times 100$). B) Areas of granulomatous tissue with acid-alcohol resistant bacilli in the rectum ($\times 400$). Arrows point to the Koch bacilli.

The techniques for identifying the presence of *M. tuberculosis* in tissue biopsies include the Ziehl-Neelsen (ZN) acid-alcohol resistant stain, which has low sensitivity and specificity; tissue culture, which requires 3 to 8 weeks to develop and identify the mycobacterium; and the real time polymerase chain reaction (RT-PCR) techniques. Molecular diagnosis through RT-PCR enables the detection of *M. tuberculosis* complex DNA in tissue from endoscopic biopsy, resulting in a rapid diagnosis with good sensitivity (70%) and high specificity (90–95%).^{2,9,10}

We present herein the case of a 55-year-old man, with no pathologic history, that presented with symptoms of 7-month progression, characterized by episodes of rectal bleeding, as well as fatigue, anorexia, unquantified weight loss, and a sensation of fever. Laboratory tests showed normal hemoglobin, low C-reactive protein, and albumin concentration of 4.2 g/dl. Colonoscopy with ileoscopy revealed a depressed lesion in the rectum. The conclusion of the histopathologic study of the rectal lesion was active, erosive, chronic rectitis, with a granulomatous process, and negative ZN stain. CD was suggested and therapy with 5-aminosalicylates was begun. The patient's symptoms described above persisted and he sought medical attention at our hospital center. A chest, abdominal, and pelvic CAT scan was ordered that revealed a diffuse, bilateral, pulmonary nodular pattern, concentric parietal thickening of the rectum with perirectal adenopathies, nodular thickening of the major omentum, mild ascites, and numerous abdominopelvic adenopathies that suggested the diagnosis

of granulomatous disease. A possible neoplastic origin could not be ruled out. A new colonoscopy was performed that showed lesion-free mucosa of the ileum and colon. Several 5–6 mm fibrin-covered ulcers, as well as a large ulcerated lesion with irregular edges and a center with fibrinoid exudate, were seen in the rectum (Fig. 1).

The tissue sample was sent for PCR study for *M. tuberculosis* and the result was positive. The histopathologic study revealed a diffuse, accentuated infiltrate composed of histiocytes, lymphocytes, and scant neutrophils with cryptic abscesses; glands with reduced mucus secretion and reactive atypia with no neoplasia; and the ZN stain showed the presence of acid-alcohol resistant bacilli in the rectum (Fig. 2). The diagnosis was rectal tuberculosis. HIV testing was ordered, and the result was positive. Anti-tuberculosis and antiretroviral therapies were begun, and the patient had clinical improvement.

Our case was that of a patient with a nonspecific clinical picture, who after endoscopic and microbiologic study, was diagnosed with a rectal lesion secondary to TB. There are few reports in the literature on rectal TB, and given that the disease can simulate other pathologies, it is important to consider it within the differential diagnosis, especially in immunosuppressed patients and in countries with a higher incidence of the disease. The suitability of PCR techniques for the detection of *M. tuberculosis* makes it a useful diagnostic tool, given the low sensitivity of the ZN stain in the histopathologic study. In the case of our patient, both studies demonstrated the presence of *M. tuberculosis*,

enabling confirmation of the diagnosis and commencement of adequate treatment. In patients clinically suspected of presenting with TB or with suggestive endoscopic lesions, a possible recommendation is the performance of a PCR study for *M. tuberculosis* in intestinal tissue because it favors rapid diagnosis and has a high diagnostic yield.

Ethical considerations

The study was approved by the scientific ethics committee of the *Hospital Clínico Universidad de Chile* and the patient gave his written statement of informed consent. The authors declare that the present article contains no personal information that would enable patient identification.

Financial disclosure

No financial support was received in relation to this article.

Conflict of interest

The authors declare that there is no conflict of interest.

References

- Seo H, Lee S, So H, et al. Temporal trends in the misdiagnosis rates between Crohn's disease and intestinal tuberculosis. *World J Gastroenterol*. 2017;23:6306–14.
- Almadi MA, Ghosh S, Aljebreen AM. Differentiating intestinal tuberculosis from Crohn's disease: a diagnostic challenge. *Am J Gastroenterol*. 2009;104:1003–12.
- Huang X, Liao WD, Yu C, et al. Differences in clinical features of Crohn's disease and intestinal tuberculosis. *World J Gastroenterol*. 2015;21:3650–6.
- Jung Y, Hwangbo Y, Yoon SM, et al. Predictive factors for differentiating between Crohn's disease and intestinal tuberculosis in Koreans. *Am J Gastroenterol*. 2016;111:1156–64.
- Pan American Health Organization. Health in the Americas+, 2017 edition. Summary: Regional outlook and country profiles. Washington, D.C.: OPS; 2017.
- Ministerio de Salud, Gobierno de Chile. Tuberculosis: Informe de Situación Chile 2014. Programa Nacional de Control y Eliminación de la Tuberculosis. Santiago: Departamento de Enfermedades Transmisibles. División de Prevención y Control de Enfermedades; junio de 2015. p. 5 [accessed 1 Aug 2018]. Available from: www.minsal.cl/sites/default/files/Informe_tbc_2014.pdf
- González-Puga C, Palomeque-Jiménez A, García-Saura PL, et al. Colonic tuberculosis mimicking Crohn's disease: an exceptional cause of massive surgical rectal bleeding. *Med Mal Infect*. 2015;45:44–6.
- Singh J, Puri AS, Sachdeva S, et al. Rectal tuberculosis after infliximab therapy despite negative screening for latent tuberculosis in a patient with ulcerative colitis. *Intest Res*. 2016;14:183–6.
- Babafemi EO, Cherian BP, Banting L, et al. Effectiveness of real-time polymerase chain reaction assay for the detection of *Mycobacterium tuberculosis* in pathological samples: a systematic review and meta-analysis. *Syst Rev*. 2017;6:215–31.
- Perez-Risco D, Rodríguez-Temporal D, Valledor-Sanchez I, et al. Evaluation of the Xpert MTB/RIF ultra assay for direct detection of *Mycobacterium tuberculosis* complex in smear-negative extrapulmonary samples. *J Clin Microbiol*. 2018;56:e00659–718.

M. Gompertz^a, L. Carreño^b, L.C. Gil La Rotta^{a,*}

^a Sección de Gastroenterología, Departamento de Medicina Interna, Hospital Clínico Universidad de Chile, Santiago, Chile

^b Departamento de Anatomía Patológica, Hospital Clínico Universidad de Chile, Santiago, Chile

* Corresponding author at: Sección Gastroenterología, Hospital Clínico Universidad de Chile, Santos Dumont 999, Independencia, Santiago 8380456, Chile. Tel.: +56229788350. E-mail address: drlcgill@yahoo.com (L.C. Gil La Rotta).

2255-534X/

© 2019 Asociación Mexicana de Gastroenterología. Published by Masson Doyma México S.A. This is an open access article under the CC BY-NC-ND license (<http://creativecommons.org/licenses/by-nc-nd/4.0/>).

What do we know about detectable viremia at the end of hepatitis C virus treatment and the subsequent sustained virologic response?[☆]



¿Qué sabemos acerca de la carga viral detectable al final del tratamiento de virus de hepatitis C con respuesta viral subsecuente?

The treatment of hepatitis C virus (HCV) infection with regimens based on second generation direct-acting antivirals

(DAAs) has been associated with high rates of sustained virologic response (SVR) and few secondary effects (1%). However, there is little information about the impact of detectable viral load on the SVR at the end of treatment with DAAs.¹ Thus, we refer to the case of a 49-year-old Mexican man that had a history of failed treatment in 2006 with pegylated interferon and ribavirin for 48 weeks. The liver biopsy taken at that time reported grade 2 fibrosis (METAVIR F2). In 2016, the patient received 12 weeks of paritaprevir/ritonavir/ombitasvir/dasabuvir (3 D), with complete adherence, and no significant adverse events. Viral load at the end of treatment was detectable (Abbott Real Time PCR assay [ART]), with SVR 3 months later (Table 1).

Previous analyses have reported a 5–7% detectable viral load at the end of treatment with SVR after different DAA regimens.^{1–4} We found 6 reports in relation to that interesting phenomenon, which are summarized in Table 1. To explain the viremia at the end of treatment, some authors suggest a mechanism involving viral kinetics, in which

[☆] Please cite this article as: Toapanta-Yanchapaxi L, Páez-Zayas VM, Cuevas-Castillejos JE, Lizárraga-Gómez E, García-Juárez I. ¿Qué sabemos acerca de la carga viral detectable al final del tratamiento de virus de hepatitis C con respuesta viral subsecuente? *Rev Gastroenterol Méx*. 2019;84:526–528.