

(fig. 2A and B). Non-Hodgkin's lymphoma was originally reported, for which immunohistochemical staining was carried out. The tumor cells stained positive for CD138 (plasmatic cell membrane marker), CD79a (immature B-cell marker), MUM1 in the nuclei of the tumor cells, and Ki-67 (90%), establishing a high proliferation rate of neoplastic cells (fig. 2C-F). The complete immunohistochemistry panel included: positive Epstein-Barr encoding region (EBER) performed through *in situ* hybridization; positive, focal, and weak Bcl-6; and negative ALK-1, HHV-8, CD20, CD3, Bcl-2, CD5, and CD56. The report's conclusion was plasmablastic lymphoma.

The clinical course was aggressive, with persistence of the septic focus (*Pseudomonas aeruginosa* was isolated) and bleeding recurrence. The patient died 30 days after hospital admission due to hypovolemic and septic shock. The diagnosis was made *post mortem* and it was not possible to look for HIV infection.

Financial disclosure

No financial support was received in relation to this article.

Conflict of interest

The authors declare that there is no conflict of interest.

References

1. Doolabh N, Anthony T, Simmang C, et al. Primary colonic lymphoma. *J Surg Oncol*. 2000;74:257–62.

- Fan CW, Changchien CR, Wang JY, et al. Primary colorectal lymphoma. *Dis Colon Rectum*. 2000;43:1277–82.
- Delecluse HJ, Anagnostopoulos I, Dallenbach F, et al. Plasmablastic lymphomas of the oral cavity: a new entity associated with the human immunodeficiency virus infection. *Blood*. 1997;89:1413–20.
- Campo E, Swerdlow SH, Harris NL, et al. The 2008 WHO classification of lymphoid neoplasms and beyond: Evolving concepts and practical applications. *Blood*. 2011;117:5019–32.
- Koizumi Y, Uehira T, Ota Y, et al. Clinical and pathological aspects of human immunodeficiency virus-associated plasmablastic lymphoma: Analysis of 24 cases. *Int J Hematol*. 2016;104:669–81.
- Castillo JJ, Bibas M, Miranda RN. The biology and treatment of plasmablastic lymphoma. *Blood*. 2015;125:2323–30.

A. Pérez-Mendoza^{a,*}, A.M. Zárate-Guzmán^a,
I.B. Lázaro-Pacheco^a, J.J. Navarrete-Pérez^b

^a Departamento de Endoscopia Gastrointestinal, Hospital General de México, Mexico City, Mexico

^b Departamento de Patología, Hospital General de México, Mexico City, Mexico

* Corresponding author. Dr. Balmis 148, Colonia Doctores, Delegación Cuauhtémoc, Mexico City. C.P. 06760, Mexico. Mobile phone: (+52) 5542296275
E-mail address: dr.ariel.perez@hotmail.com
(A. Pérez-Mendoza).

2255-534X/

© 2019 Asociación Mexicana de Gastroenterología. Published by Masson Doyma México S.A. This is an open access article under the CC BY-NC-ND license (<http://creativecommons.org/licenses/by-nc-nd/4.0/>).

Mid-gastrointestinal bleeding secondary to a gastrointestinal stromal tumor of the jejunum: A case report[☆]



Hemorragia digestiva media secundaria a tumor estromal gastrointestinal de yeyuno: reporte de caso

Gastrointestinal stromal tumors (GISTs) are considered the most common mesenchymal neoplasias of the digestive tract, with a current incidence of 10 to 20 cases per million inhabitants, according to the latest case series.¹

A 66-year-old woman with an unremarkable past medical history, had disease onset one month prior, presenting with intermittent colicky abdominal pain of mild intensity, associated with sporadic events of scant-quantity melena, for which she sought medical attention with a private-

sector physician. She was diagnosed with gastric ulcer and *Helicobacter pylori* infection and had partial improvement with the prescribed treatment. Two days before hospital admission, abdominal pain reappeared with the same characteristics, but was persistent and more intense. She also had numerous episodes of vomiting of the food content of the stomach. On the day of admission, she presented with 6 episodes of hematochezia, associated with fainting sensation. Clinical examination revealed hemodynamic instability, for which she was given intravenous resuscitation with crystalloids, with partial response. The patient also presented with skin and mucosal pallor and abdominal pain upon deep palpation at the level of the mesogastrium. The findings in the rest of the physical examination were normal. The patient's hemoglobin level was in the severe normocytic-normochromic anemia range (Hb: 6.5 mg/dl), and so she underwent transfusion with 3 units of red blood cells. Later control showed Hb at 8.5 mg/dl. Conventional endoscopic studies were normal. Abdominal tomography scan identified a contrast-enhanced lesion with irregular edges and a 5-6 cm diameter, with hypodense areas in its interior. The lesion was dependent on the small bowel, with no signs of metastasis (fig. 1A). The patient continued to present with daily episodes of hematochezia and melena during her hospitalization. Because our hospital does not offer capsule endoscopy or enteroscopy, the patient underwent exploratory laparoscopy that revealed a multi-

[☆] Please cite this article as: Aliaga Ramos JJ, Espinoza Ríos J, Pinto Valdivia JL, Salas Dueñas Y, Chancafe Morgan R. Hemorragia digestiva media secundaria a tumor estromal gastrointestinal de yeyuno: reporte de caso. *Revista de Gastroenterología de México*. 2019;84:520–522.

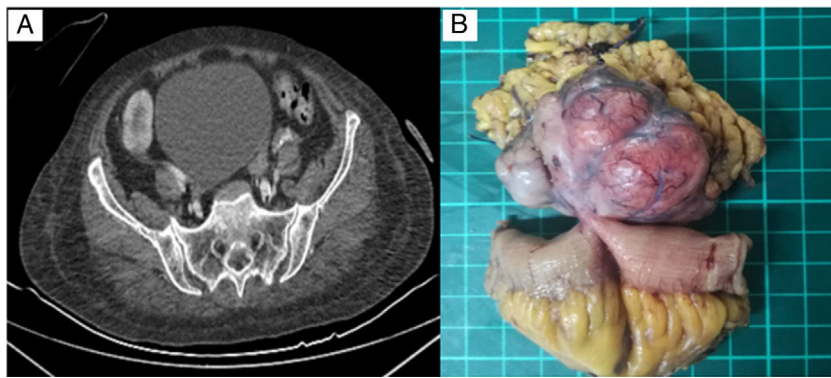


Figure 1 A) Contrast-enhanced lesion with hypodense areas in its interior. B) Multilobulated tumor dependent on the intestinal wall.

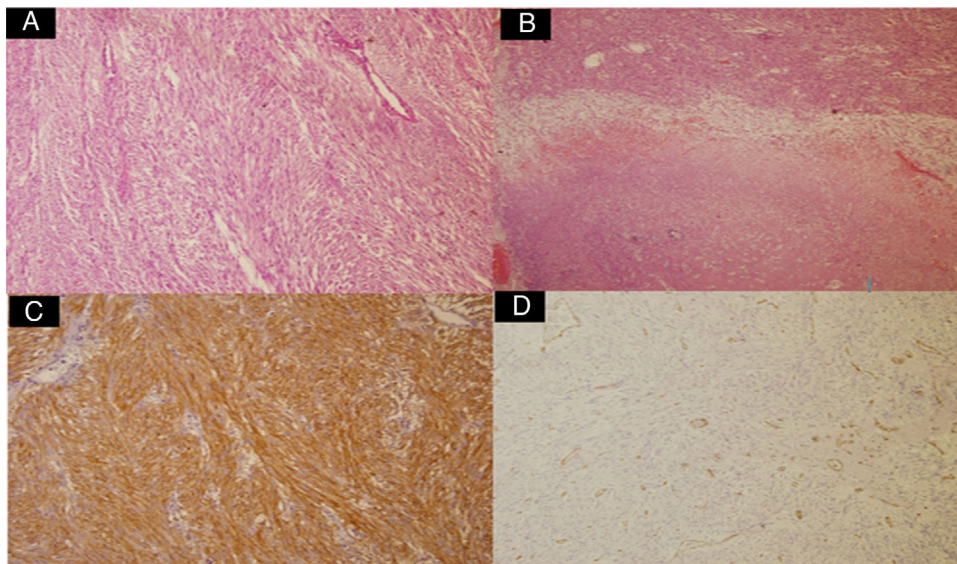


Figure 2 A) Proliferation of fusiform cells (H&E x10). B) Presence of necrotic foci (H&E x10) Immunohistochemistry positive for CD117. D) Immunohistochemistry negative for CD34.

lobulated and pedunculated mass with a 5-6 cm diameter located 2 m from the ileocecal valve and 1.7 m from the angle of Treitz (fig. 1B). The jejunal tumor was resected and end-to-end anastomosis was performed.

Microscopic examination identified a proliferation of fusiform cells that compromised the muscularis propria and subserosa, without involving the mucosa (fig. 2A). There was necrosis in 5% of the tumor sample and a low mitotic index (<5 mitosis/ 5 mm^2) (fig. 2B). Immunohistochemistry staining was positive for CD117 and DOG-1 and negative for CD34 (figs. 2C and D).

Bleeding ceased after treatment and no new decreases in hemoglobin were observed. The patient remained asymptomatic and was released from the hospital.

The diagnostic and therapeutic approach to GISTs when mid-gastrointestinal active bleeding is present is controversial.¹ Leclaire et al.² found a diagnostic yield of capsule endoscopy of 67% in severe active mid-gastrointestinal bleeding. The cause was tumor in 9% of those cases. They considered that method the diagnostic tool with the best posterior therapeutic impact. However,

other authors suggest beginning with deep enteroscopy, given that it offers immediate diagnostic-therapeutic measures. Heine et al.³ reported 73% diagnostic sensitivity with double-balloon enteroscopy, without previous capsule endoscopy, and endoscopic treatment was performed in 55% of those patients, showing the high complementariness of both studies, even in that clinical context.

Abdominal tomography has a role in both the diagnosis of GIST and post-treatment follow-up, given that positivity results in immediate therapeutic conduct.⁴ Based on the tomographic criteria of Choi, Blanco et al.⁵ found complete response in 31 patients with GIST under treatment and disease progression in 16.1%, demonstrating the great usefulness of abdominal tomography in the follow-up of that group of patients. Our patient presented with a lesion identified through tomography, for which surgery was rapidly performed.

Financial disclosure

No financial support was received in relation to this article.

Conflict of interest

The authors declare that there is no conflict of interest.

References

1. Gerson L, Fidler J, Cave D, et al. ACG Clinical Guideline: Diagnosis and Management of Small Bowel Bleeding. *Am J Gastroenterol*. 2015;110:1265–87.
2. Leclaire S, Iwanicki-Caron I, Di-Fiore A, et al. Yield and impact of emergency capsule enteroscopy in severe obscure-overt gastrointestinal bleeding. *Endoscopy*. 2012;44:337–42.
3. Heine G, Hadithi M, Groenen M, et al. Double balloon enteroscopy: Indications, diagnostic yield and complications in a series of 275 patients suspected of small bowel disease. *Endoscopy*. 2006;38:42–8.
4. Casali PG, Abecassis N, Bauer S, et al., ESMO Guidelines Committee and EURACAN. Gastrointestinal stromal tumours: ESMO-EURACAN Clinical Practice Guidelines for diagnosis, treatment and follow-up. *Ann Oncol*. 2018;29 Suppl 4:68–78.

5. Blanco E, Conde B, Cacho A, et al. Tumores del estroma gastrointestinal: evaluación por tomografía mediante los criterios de Choi. *An Radiol Mex*. 2014;13:181–7.

J.J. Aliaga Ramos^{a,*}, J. Espinoza Ríos^a,
J.L. Pinto Valdivia^a, Y. Salas Dueñas^b, R. Chancafe Morgan^b

^a Servicio de Gastroenterología, Hospital Nacional Cayetano Heredia, Lima, Peru

^b Servicio de Anatomía Patológica, Hospital Nacional Cayetano Heredia, Lima, Peru

* Corresponding author. Calle Walter Stubbs 229, Lima, Peru, Tel.: +961-100-593

E-mail address: arjosue3000@gmail.com (J.J.A. Ramos).

23 August 2018 26 November 2018

2255-534X/

© 2018 Asociación Mexicana de Gastroenterología. Published by Masson Doyma México S.A. This is an open access article under the CC BY-NC-ND license (<http://creativecommons.org/licenses/by-nc-nd/4.0/>).

Thrombosis of an infrarenal aortic aneurysm secondary to *Salmonella enteritidis* infection[☆]



Trombosis de aneurisma aórtico infrarrenal secundario a infección por *Salmonella enteritidis*

Acute gastroenteritis after egg ingestion is the most frequent manifestation of *Salmonella enteritidis* (*S. enteritidis*) infection. However, invasive pathology, such as the formation of aortic aneurysms due to invasion of the endothelium, is rare.

We present herein a case of acute gastroenteritis due to *S. enteritidis* complicated by the formation of a previously unknown infrarenal aortic aneurysm, in turn, associated with complete arterial thrombosis of the aneurysm, with the consequent acute arterial ischemia. To the best of our knowledge, the present case of arterial thrombosis associated with an aneurysm infected by *Salmonella* is the first to be described in the literature.

A 57-year-old man had a history of mild chronic obstructive pulmonary disease (COPD) and was under treatment with glycopyrronium bromide.

He sought medical attention at the emergency service due to paresthesia and the inability to walk of 48-h progression. In the days beforehand, he had presented with symptoms of acute gastroenteritis after eating eggs, that

included vomiting, greenish diarrhea with up to 18 bowel movements daily, fever of 38 °C, and general malaise.

Upon his arrival at the emergency service, the patient presented with blood pressure of 181/118 mmHg, heart rate of 118 bpm, and temperature of 35.4 °C. Physical examination revealed peripheral hypoperfusion in both lower limbs, with *livedo reticularis* up to the pelvis. Laboratory test results showed hemoglobin 15 mg/dL, leukocytes $5.9\text{--}10.70 \times 10^3/\text{L}$, creatinine 2.45 mg/dL, creatine kinase 20,000 U/L, sodium 140 mEq/L, potassium 5.5 mEq/L, pH 7.15, pCO₂ 44 mm Hg, pO₂ 98 mm Hg, and lactic acid 10.1 mg/dL.

With the suspicion of acute arterial ischemia, a contrast-enhanced abdominal computed tomography (CT) scan was carried out that showed dilation of the aneurysm and complete thrombosis of the infrarenal abdominal aorta (Fig. 1). Anticoagulation with low-molecular-weight heparin was begun and emergency right axillofemoral bypass was performed (Fig. 2). Immediate postoperative progression was good. Empiric antibiotic therapy was started with meropenem and vancomycin. Multi-sensitive serogroup D *Salmonella* was isolated in blood cultures and the antibiotic was downscaled to 4 weeks of treatment with ceftriaxone 2 g daily.

Daily fever peaks persisted despite the antibiotic therapy. Infection of the vascular stent was suspected and so a positron emission tomography (PET-CT) scan and a scintigram with analogous leukocytes labeled with HMPAO-Tc99m were carried out, through which infection at the level of the bypass was ruled out.

Acute gastroenteritis due to *Salmonella* spp. is the most frequent manifestation of infection caused by that Gram-negative bacillus. Invasive disease due to *S. enteritidis* is 6 times more frequent than other causes of bacterial gastroenteritis and is more frequent in persons above 60 years of age and in children.¹

As in the case presented herein, the formation of mycotic or infected aneurysms is a rare manifestation of systemic

[☆] Please cite this article as: García-Fernández-Bravo I, González-Munera A, Ordieres-Ortega L, González-Leyte M. Trombosis de aneurisma aórtico infrarrenal secundario a infección por *Salmonella enteritidis*. *Revista de Gastroenterología de México*. 2019;84:522–524. <https://doi.org/10.1016/j.rgmx.2018.12.002>.