




# REVISTA DE GASTROENTEROLOGÍA DE MÉXICO

[www.elsevier.es/rgmx](http://www.elsevier.es/rgmx)



## CLINICAL IMAGE IN GASTROENTEROLOGY

### Pneumatosis cystoides intestinalis: A rare benign cause of chronic pain and bloating with pneumoperitoneum ☆



### Neumatosis quística intestinal: una causa rara y benigna de dolor y distensión abdominal crónicos con neumoperitoneo

J.E. Cuevas-Castillejos\*, M.A. Valdovinos-Díaz

*Departamento de Gastroenterología, Instituto Nacional de Ciencias Médicas y Nutrición «Salvador Zubirán», Mexico City, Mexico*

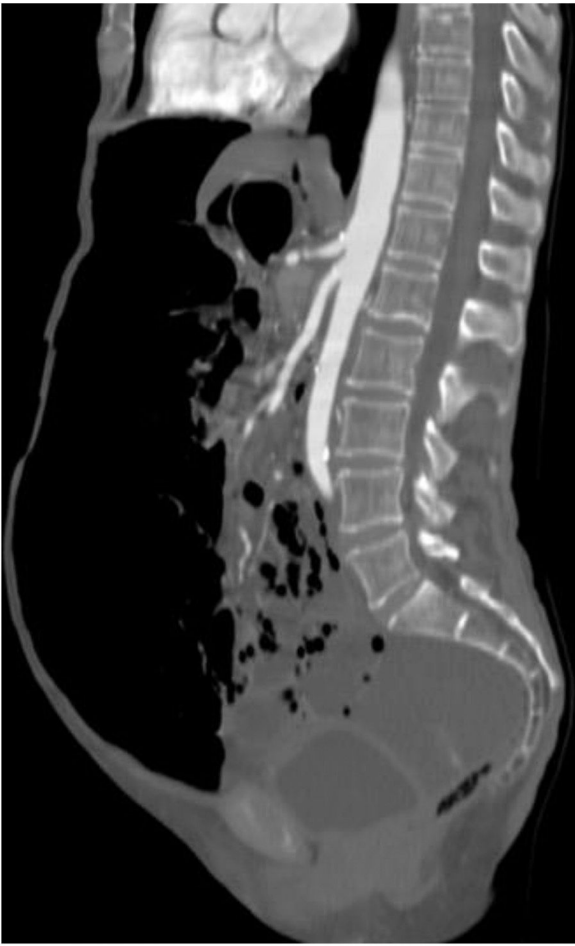A previously healthy 65-year-old woman presented with symptoms of colicky abdominal pain and intense bloating, nausea and vomiting, and 8 kg weight loss within the past 12 months. Her vital signs were stable, and she had no signs of peritoneal irritation. Abdominal angiotomography identified diffuse pneumatosis intestinalis with a predominantly cystic pattern, as well as abundant intraperitoneal free air, free fluid in the pelvic cavity, and no alterations in the mesenteric vasculature (figs. 1-3). Her laboratory test results ruled out gastrointestinal, infectious, oncologic, rheumatologic, pulmonary, and pharmacologic causes that would explain the tomographic findings. The patient received treatment

based on metronidazole, probiotics, and prucalopride, and presented with partial symptom improvement, but no remission of the radiologic findings after 6 months of follow-up. The present case illustrates the fact that not all patients with pneumatosis intestinalis or pneumoperitoneum should be managed surgically. Pneumatosis cystoides intestinalis is a rare radiologic finding of unknown etiology. The differential diagnosis includes numerous causes, particularly intestinal ischemia. Treatment consists of antibiotics, prokinetics, hyperbaric oxygen, or endoscopic lesion resection, with varying results. Its clinical progression tends to be chronic and benign.

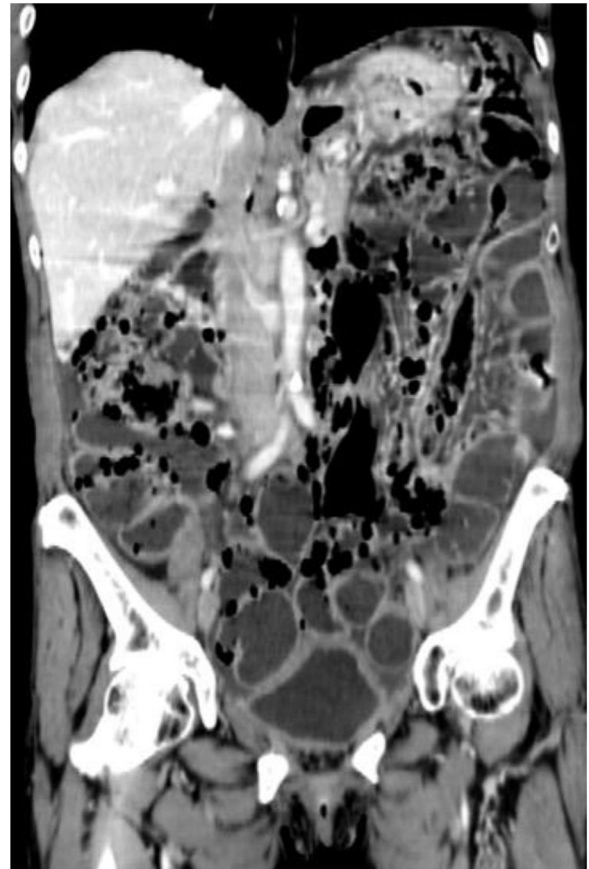
☆ Please cite this article as: Cuevas-Castillejos JE, Valdovinos-Díaz MA. Neumatosis quística intestinal: una causa rara y benigna de dolor y distensión abdominal crónicos con neumoperitoneo. *Revista de Gastroenterología de México*. 2019;84:402–404.

\* Corresponding author. Departamento de Gastroenterología, Instituto Nacional de Ciencias Médicas y Nutrición «Salvador Zubirán», Vasco de Quiroga 15, Belisario Domínguez Sección XVI, Tlalpan, Mexico City, Mexico, C.P. 14080. Phone: +52 (55) 54870900, Ext.: 2708

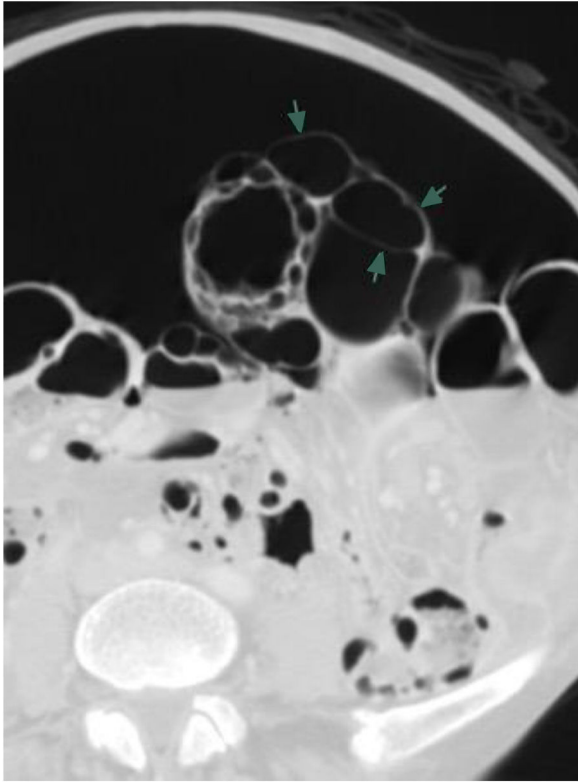
E-mail address: [elihucuevas@gmail.com](mailto:elihucuevas@gmail.com)  
(J.E. Cuevas-Castillejos).



**Figure 1** Abdominal tomography scan with sagittal reconstruction showing abundant pneumoperitoneum, pneumatosis intestinalis, and free fluid in the pelvic cavity.



**Figure 2** Abdominal tomography scan with coronal reconstruction showing diffuse pneumatosis intestinalis with a predominantly cystic pattern.



**Figure 3** Axial view of the abdominal tomography scan showing abundant pneumoperitoneum and pneumatosis intestinalis with a cystic pattern (arrows).

### Financial disclosure

No specific grants were received from public sector agencies, the business sector, or non-profit organizations in relation to this article.

### Conflict of interest

The authors declare that there is no conflict of interest.