



REVISTA DE GASTROENTEROLOGÍA DE MÉXICO

www.elsevier.es/rgmx



CLINICAL IMAGE IN GASTROENTEROLOGY

Colouterine fistula: A rare complication of colonic diverticulitis[☆]



Fístula colo-uterina. Una complicación rara en diverticulitis aguda

G.R. Guevara-Morales^{a,*}, R. Maldonado-Barrón^b

^a Departamento de Cirugía General, Hospital Regional de Veracruz, Instituto de Seguridad y Servicios Sociales de los Trabajadores del Estado (ISSSTE), Veracruz, Veracruz, Mexico

^b Servicio de Coloproctología, Hospital Regional de Veracruz, Instituto de Seguridad y Servicios Sociales de los Trabajadores del Estado (ISSSTE), Veracruz, Veracruz, Mexico

Colouterine fistula is a rare complication of acute diverticulitis of the colon. It is estimated to present in less than 2-3% of all diverticulitis-associated fistulas. We present herein a 67-year-old woman that was admitted to the emergency service due to abdominal pain, fever, and increased volume in the hypogastrium, with no signs of peritoneal irritation. A CAT scan identified complicated diverticulitis with the presence of a colouterine fistula (fig. 1A-C). Transvaginal drainage was unsuccessful and so the patient underwent laparotomy, with *en bloc* resection of the sigmoid colon, the uterus, and the uterine appendages. The histopathologic study of the specimen reported the presence of a fistula, whose tract measured 3.5 cm.

Ethical disclosures

Protection of human and animal subjects. The authors declare that no experiments were performed on humans or animals for this study.

Confidentiality of data. The authors declare that they have followed the protocols of their work center on the publication of patient data.

Right to privacy and informed consent. The authors declare that no patient data appear in this article.

[☆] Please cite this article as: Guevara-Morales GR, Maldonado-Barrón R. Fístula colo-uterina. Una complicación rara en diverticulitis aguda. Revista de Gastroenterología de México. 2019;84:104–105.

* Corresponding author. Av. Díaz Mirón esquina Sayula sin número Fraccionamiento Moderno, Veracruz, Veracruz, Mexico, C.P. 91918. Phone: (229) 927 92 29

E-mail address: grobertoguevara@gmail.com (G.R. Guevara-Morales).

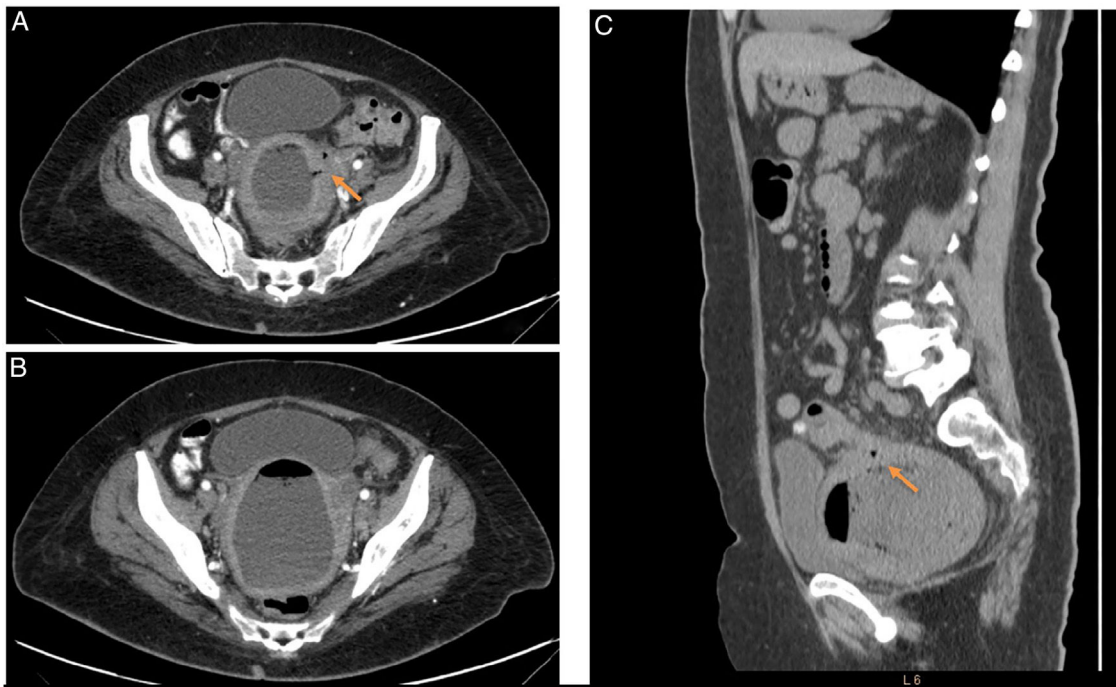


Figure 1 A) Axial view of a non-contrast-enhanced CAT scan showing adhesions that involve the sigmoid colon, uterus, and its left appendages, as well as a colouterine fistula (orange arrow). B) Axial view of a non-contrast-enhanced CAT scan showing a filled uterus secondary to fluid and gas in the endometrial cavity. C) Sagittal view of a CAT scan showing the colouterine fistula (orange arrow) and uterus displacing the bladder.

Financial disclosure

No financial support was received in relation to this article.
The authors used their own resources.

Conflict of interest

The authors declare that there is no conflict of interest.