

**Figure 3** Biopsies of the rectum. A. H-E stain x100 in which no ganglion cells are observed. B. IHC x100 with CD117 showing a reduced number of interstitial cells of Cajal. C. IHC x100 positive for S100 in the nerve plexuses.

There are few reports on this disease in stages after infancy in the national and international literature.<sup>1,3-6</sup>

It is important to consider the presence of this rare pathologic process in young adult patients with treatment-refractory chronic constipation, in whom other more common diseases have been ruled out through easily accessed studies, such as imaging or anorectal physiology studies.

### Financial disclosure

No financial support was received in relation to this study/article.

### Conflict of interest

The authors declare that there is no conflict of interest.

### References

1. Prieto E, Medina JL, Casillas R, et al. Enfermedad de Hirschsprung: un caso de constipación en el adulto. *Cirujano General*. 2008;30:231-3.
2. De Manueles J, de la Rubia L. Enfermedad de Hirschsprung. *Rev Col Gastroenterol*. 2016;31:47-54.
3. Burlando E, Bernhardt R, Barraud C, et al. Enfermedad de Hirschsprung del adulto. Corrección quirúrgica. *Rev Argent Resid Cir*. 2009;13:79-81.

4. Fortea C, Martínez D, Rivadulla I, et al. Hirschsprung's disease in adults. *Rev Esp Enferm Dig*. 2001;3:150-1.
5. Icaza M, Takahashi Monroy T, Uribe Uribe N, et al. Enfermedad de Hirschsprung en el adulto. *Rev Gastroenterol Mex*. 2000;65:171-4.
6. Lombana J. Surgery in adult Hirschsprung's disease. *Rev Col Gastroenterol*. 2007;22:231-7.

E. Alcocer-Sánchez<sup>a</sup>, N. Pérez y López<sup>b,\*</sup>, J. Fernández-Álvarez<sup>c</sup>, A. Zárate-Osorno<sup>d</sup>

<sup>a</sup> *Coloproctology Service, Hospital Español de México, Mexico City, Mexico*

<sup>b</sup> *Motility Laboratory, Gastroenterology Service, Hospital Juárez de México, Mexico City, Mexico*

<sup>c</sup> *General Surgery Service, Hospital Español de México, Mexico City, Mexico*

<sup>d</sup> *Pathology service, Hospital Español de México, Mexico City, Mexico*

\* Corresponding author. Av. Ejército Nacional 617-402. Col. Granada. Del. Miguel Hidalgo. Mexico City, Mexico. CP 11520. Tel.: +52504827 / 5520670809.

E-mail address: [sonelle74@hotmail.com](mailto:sonelle74@hotmail.com) (N. Pérez y López). 2255-534X/

© 2018 Published by Masson Doyma México S.A. on behalf of Asociación Mexicana de Gastroenterología. This is an open access article under the CC BY-NC-ND license (<http://creativecommons.org/licenses/by-nc-nd/4.0/>).

## Primary lymphoma of the appendix: A case report and review of the literature<sup>☆</sup>



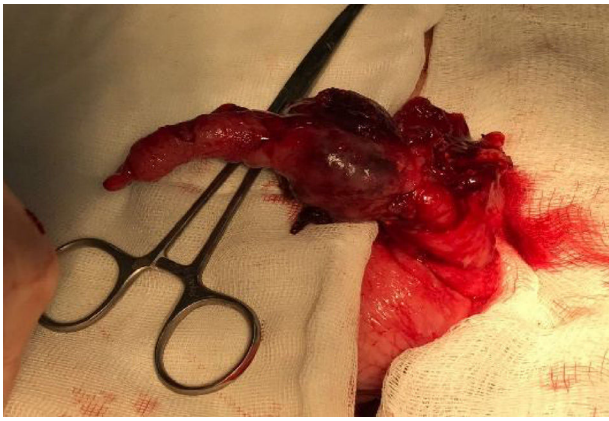
### Linfoma primario de apéndice: reporte de un caso y revisión de la literatura

Primary lymphoma of the appendix is an extremely rare entity that accounts for approximately 0.015% of the lym-

phomas of the gastrointestinal tract. There are very few published reports of the pathology. Burkitt's lymphoma is more frequent in children, whereas the majority of cases in adults correspond to large B-cell non-Hodgkin lymphoma.<sup>1-4</sup>

The majority of articles found in the international literature correspond to case reports. In the case series by Marcelo Zamorano et al., from a total of 7626 appendectomy specimens, there were only 25 appendiceal tumors and just 2 of them were primary lymphomas.<sup>5</sup> In another case series that included 5307 appendectomy specimens, Daniel Esmer et al. found a total of 31 cases (0.58%) of appendiceal tumor, none of which corresponded to appendiceal lymphoma.<sup>4</sup> A total of 1060 appendectomy specimens were reviewed over a 10-year period at the Kamineni Hospitals in India and only one case of appendiceal lymphoma was found,<sup>1</sup> illustrating the rareness of the pathology.

<sup>☆</sup> Please cite this article as: García-Norzagaray JC, Villalobos-López JA, Flores-Nájera H, Valle Leal JG, García Torres CD. Linfoma primario de apéndice: reporte de un caso y revisión de la literatura. *Revista de Gastroenterología de México*. 2019;84:254-257.



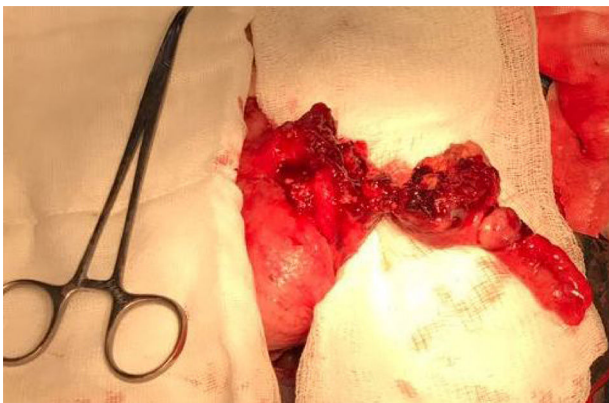**Figure 1** Appendiceal tumor.

We present herein the case of a 40-year-old woman with unremarkable past history/comorbidities. She arrived at the emergency department with 10-day progression of abdominal pain that began insidiously and gradually became more intense in the right iliac fossa, accompanied by anorexia, nausea, vomiting, and undetermined fever. Physical examination revealed a mass in the right lower quadrant that measured approximately 10 cm in diameter. It was semisolid, with poorly-defined borders, and was painful upon superficial palpation.

Laboratory work-up results were: hemoglobin 10.4 g/dl, hematocrit 33.3%, platelets 332,000, leukocytes 12,400, neutrophils 77%, glucose 100 mg/dl, uric acid 3.9 mg/dl, cholesterol 124 mg/dl, triglycerides 67 mg/dl, creatinine 0.64 mg/dl, urea 23.5 mg/dl, ureic nitrogen 11 mg/dl, PT 18.4 seconds, INR 1.45, and PTT 42.2 seconds.

No preoperative imaging studies were carried out, given that symptoms were highly suggestive of acute appendicitis.

Exploratory laparotomy revealed a tumor that was dependent on the cecal appendix at its middle and distal third, measuring approximately 5 x 3 cm. It had an irregular appearance and was friable and bloody (figs. 1 and 2). Appendectomy was performed with primary closure employing the modified Pouchet technique. The patient was released on the following day with no complications.



**Figure 2** Appendiceal tumor with infiltration into the cecum.

At the check-up 2 weeks after surgery, the patient's general condition was good, with no postoperative complications.

The histopathologic report stated large B-cell non-Hodgkin lymphoma. A postoperative CAT scan showed no tumor activity at another level and immunohistochemistry was positive for CD20, MUM-1, and CD 138 and positive for Ki67 in 70% of the specimen (fig. 3). The patient was referred to the medical oncology service and received CHOP chemotherapy plus 8 cycles of rituximab and complementary radiotherapy.

In the majority of cases, appendiceal lymphomas, like all tumors of the appendix, present with symptoms of acute appendicitis.<sup>1,6</sup> Other less frequent symptoms are anorexia, weight loss, gastrointestinal bleeding, and intussusception.<sup>6</sup>

Appendiceal tumor is generally an intraoperative diagnosis. When suspected preoperatively, CAT is a useful study that can reveal a diffuse enlargement of the appendix, maintaining its vermiform shape with thickening of the wall and periappendiceal tissue, which can signify periappendiceal inflammation or lymphomatous infiltration. There can also be an increase in the focal size of the appendix.<sup>7-9</sup> However, all those findings are not specific for appendiceal lymphoma, given that they can also be found in other neoplasias, and even in a true case of acute appendicitis. Thus, histopathologic study is essential for diagnosis.

When lymphoma of the appendix is diagnosed, its presence at another level must be ruled out through imaging studies, as well as through immunohistochemistry that is positive for CD20, CD5, CD10, and Bel6. In addition, it aids in ruling out more common neoplasias, such as neuroendocrine carcinoma and poorly differentiated adenocarcinoma.<sup>9</sup>

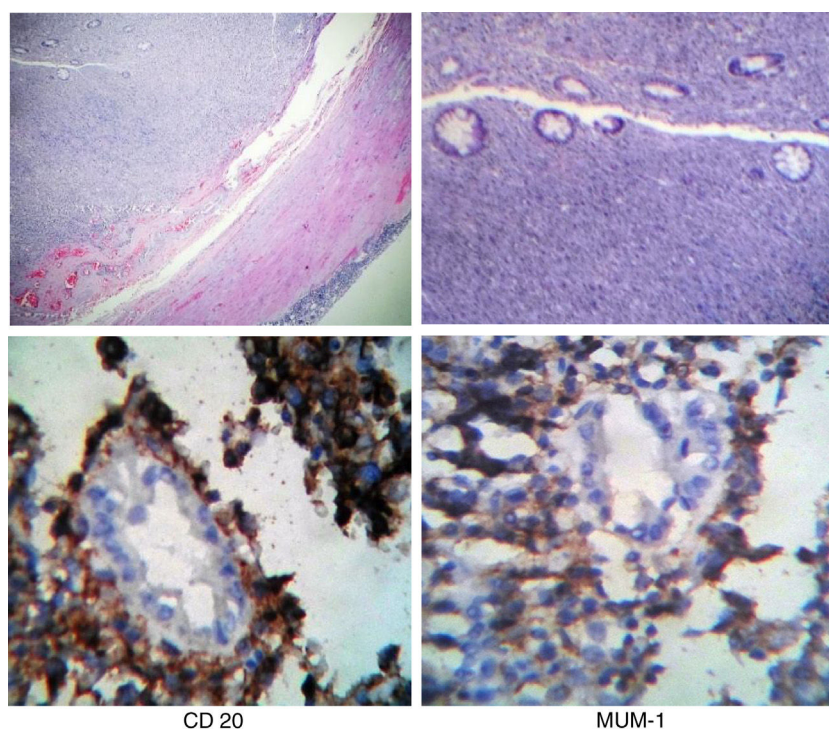
Immunocompromised patients, especially those with HIV, can present with atypically located lymphoma, and therefore it is necessary to perform ELISA and Western Blot tests for ruling out another possible diagnosis.<sup>10</sup>

The surgical conduct to follow regarding appendiceal tumors is a subject of debate.<sup>11</sup> Some authors state that right hemicolectomy with lymph node extirpation is necessary in cases of appendiceal tumors larger than 2 cm, tumors infiltrating the mesoappendix, when the cecum is compromised, or when there is a high mitotic index,<sup>12</sup> whereas others believe that simple appendectomy with stump closure should be performed, holding off definitive treatment until there is a histopathologic result.<sup>13</sup>

In our case, appendectomy was performed, and postoperative chemotherapy was applied, once we had the histopathologic result of primary lymphoma of the appendix. Medical treatment should be carried out according to clinical stage and histologic type.

Diagnosis of primary lymphoma of the appendix is usually made through postoperative histopathologic study and therefore its routine performance is indispensable in all cases of extirpated cecal appendix.<sup>5</sup>

Primary lymphoma of the appendix is an extremely rare pathology. It is diagnosed once the presence of lymphoma in another location has been ruled out. Its presentation in the majority of cases is in the context of acute appendicitis, which is why it is diagnosed postoperatively through histopathologic study.<sup>9</sup> Approximately 2 to 6% of patients with acute appendicitis have a palpable mass, described as a phlegmon or abscess, of which 6 to 12% correspond to



**Figure 3** Histologic sections of the appendiceal neoplastic lesion formed by neoplastic lymphocytes (H&E and immunohistochemistry).

an appendiceal tumor,<sup>14</sup> as occurred in our patient. There is still controversy about the surgical treatment of tumor of the appendix. We decided to perform simple appendectomy and wait for the histopathologic result to determine the definitive treatment. That appears to be a good alternative for managing a well-defined appendiceal tumor that is an intraoperative finding and no accurate histopathologic diagnosis has been made.

### Ethical disclosures

**Protection of human and animal subjects.** The authors declare that no experiments were performed on humans or animals for this study.

**Confidentiality of data.** The authors declare that they have followed the protocols of their work center on the publication of patient data.

**Right to privacy and informed consent.** The authors have obtained the written informed consent of the patients or subjects mentioned in the article. The corresponding author is in possession of this document.

### Financial disclosure

No financial support was received in relation to this article.

### Conflict of interest

The authors declare that there is no conflict of interest.

### References

1. Radha S, Afroz T, Satyanarayana G. Primary marginal zone B-cell lymphoma of appendix. *Indian J Pathol Microbiol.* 2008;51:392–4.
2. Ghasmei M, Abedian Kenari S. A primary diffuse large B-cell lymphoma of appendix. *Iran Red Crescent Med J.* 2010;12:575–8.
3. Fu TY, Wang JS, Tseng HH. Primary appendiceal lymphoma presenting as perforated acute appendicitis. *J Chin Med Assoc.* 2004;67:629–32.
4. Katz DS, Stein LB, Mazzie JP. Recurrent non-Hodgkin's lymphoma of the appendix. *Am J Roentgenol.* 2002;179:1443–5.
5. Zamorano M, Quiroz M, Drolett N, et al. Neoplasias malignas primarias del apéndice cecal: estudio comparativo entre 2 hospitales regionales. *Rev Chil Cir.* 2014;66:543–8.
6. Stewart R, Mirakhor M. Primary malignant lymphoma of the appendix. *Ulster Med J.* 1986;55:187–9.
7. Pickhardt PJ, Levy AD, Rormann CA, et al. Primary neoplasms of the appendix: Radiologic spectrum of disease with pathologic correlation. *Radiographics.* 2003;23:645–62.
8. Pickhardt PJ, Levy AD, Rormann CA, et al. Non-Hodgkin's lymphoma of the appendix: Clinical and CT findings with pathologic correlation. *Am J Roentgenol.* 2001;178:1123–7.
9. Murguía Perez M, Serrano Rufino M, Bolaños Aguilar M, et al. Linfoma primario del apéndice cecal con presentación clínica de apendicitis aguda. *Rev Esp Patol.* 2013;46:101–5.
10. Tadele M, Yancovitz S. Diffuse large B-cell lymphoma presenting as acute appendicitis in patients with acquired immunodeficiency syndrome. *Infect Dis Clin Pract.* 2007;15:411–4.
11. Fornaro R, Frascio M, Sticchi C, et al. Appendectomy or right hemicolectomy in the treatment of appendiceal carcinoid tumors. *Tumori.* 2007;93:587–90.
12. Galano R, Casaus A, Rodríguez Z. Adenocarcinoma primario del apéndice cecal. *Rev Cubana Cir.* 1998;37:120–5.

13. Eaden S, Quaedvlieg PF, Taal BG, et al. Classification of low-grade neuroendocrine tumours of the midgut and unknown origin. *Hum Pathol.* 2003;33:1126–32.
14. Buckius MT, McGrath B, Monk J, et al. Changing epidemiology of acute appendicitis in the United States: Study period 1993–2008. *J Surg Res.* 2012;175:185–90.

J.C. García-Norzagaray<sup>a</sup>, J.A. Villalobos-López<sup>a</sup>,  
H. Flores-Nájera<sup>a</sup>, J.G. Valle Leal<sup>b,\*</sup>, C.D. García Torres<sup>c</sup>

<sup>a</sup> *Departamento de Cirugía General, Hospital General Regional Número 1, Instituto Mexicano del Seguro Social, Ciudad Obregón, Sonora, Mexico*

<sup>b</sup> *Departamento de Educación e Investigación, Hospital General Regional Número 1, Instituto Mexicano del Seguro Social, Ciudad Obregón, Sonora, Mexico*

<sup>c</sup> *Departamento de Patología, Hospital General Regional Número 1, Instituto Mexicano del Seguro Social, Ciudad Obregón, Sonora, Mexico*

\*Corresponding author. Hospital General Regional Número 1, Instituto Mexicano del Seguro Social (IMSS), Avenida Guerrero y calle Sahuaripa, Ciudad Obregón, Sonora, Zona, postal 85038; Tel.: +52(644) 4134590; Extension: 31351; Cell phone: +52(644) 1270367, Mexico

E-mail address: [valle.jaime1@hotmail.com](mailto:valle.jaime1@hotmail.com) (J.G. Valle Leal). 2255-534X/

© 2018 Published by Masson Doyma México S.A. on behalf of Asociación Mexicana de Gastroenterología. This is an open access article under the CC BY-NC-ND license (<http://creativecommons.org/licenses/by-nc-nd/4.0/>).

## Congenital agastria as an isolated malformation<sup>☆</sup>



### Agastria congénita como una malformación aislada

Congenital agastria is an extremely rare condition<sup>1</sup> that is frequently associated with other gastrointestinal and extra-gastrointestinal tract malformations.<sup>2–4</sup> We present herein the case of a female patient with congenital agastria, with no other associated malformation.

A female infant of 2 months of age was the product of a second pregnancy of 34-week gestation. She was delivered by cesarean section, weighed 2,000 g (-3.1 SD, p0) and measured 43 cm in height (-3.3 SD, p0), corrected for gestational age. The infant had a history of necrotizing enterocolitis at one month of life and was referred to the Gastroenterology and Nutrition Service of the *Instituto Nacional de Pediatría* for vomiting and oral diet intolerance. She was managed with prokinetics and exclusion of cow-milk protein, with no improvement. Upon admission, physical examination showed no alterations, with weight of 2.490 kg (-5.37 SD, p0) and height of 44 cm (-6.42 SD, p0). Contrast-enhanced esophagogastroduodenoscopy revealed dilation of the body of the esophagus and a tubular gastric chamber (fig. 1a). Abdominal ultrasound showed esophageal dilation (transverse diameter: 15 mm) and reduced gastric capacity (10 ml). Congenital microgastria was suspected. Dilation of the esophageal body was observed in the esophagogastroduodenoscopy, with an absence of epithelial change in the esophagogastric junction and the folds of the gastric corpus. An atrophic and pale mucosal remnant was also observed that was first interpreted as the antral region (fig. 1b). Biopsies of the site were taken that reported

superficial esophageal epithelium with hydropic degeneration, supporting the diagnosis of congenital agastria. Echocardiogram, transfontenellar, abdominal, and kidney ultrasound studies, kidney function tests, and x-rays of the spine and extremities were performed to rule out the coexistence of other congenital malformations. A diet based on formula with initial continuous infusion was begun and was adequately tolerated. Once the patient achieved a certain weight recovery, she underwent the creation of a Hunt-Lawrence pouch at 3 months of age. During the intermediate postoperative period, the patient presented with abdominal sepsis. *K. pneumoniae* BLEE and *E. faecalis* were isolated and the infant was given broad-spectrum antibiotic therapy. At present, she is 6 months old and is adequately tolerating oral diet and gaining weight in accordance with her corrected gestational age: weight: 5.83 (-0.78 SD, p22), height: 62.2 (0.05 SD, p52).

Congenital agastria is the result of an alteration in the embryogenesis of the stomach. The process begins at the 5th week of fetal life, with the appearance of the gastric primordium (located at the distal part of the anterior intestine), which will later give rise to the stomach. Depending on the time at which that process is interrupted, either complete absence of the stomach or the formation of a small, tubular gastric remnant with minimal functional capacity (microgastria) will be produced.<sup>1</sup> The clinical data that those patients commonly present with are postprandial vomiting, gastroesophageal reflux, aspiration pneumonia, and malnutrition. Symptoms vary depending on the phase at which the development of the stomach was detained.<sup>2</sup>

As previously mentioned, those disorders often are accompanied by other gastrointestinal (esophageal atresia, intestinal malrotation, asplenia, imperforate anus), cardiac, renal, and skeletal abnormalities. Therefore, the initial approach must include the identification of those anomalies.<sup>2–4</sup>

Diagnosis is suspected through esophagogastroduodenoscopy that commonly reveals a tubular gastric remnant in the midsagittal position, as well as esophageal dilation. However, it is important that biopsies be taken at esophagogastroduodenoscopy, given that the differential diagnosis between agastria and microgastria cannot be made through

<sup>☆</sup> Please cite this article as: Cuadros-Mendoza CA, Martínez-Soto MC, Zarate-Mondragón FE, Cervantes-Bustamante R, Ramírez-Mayans JA. Agastria congénita como una malformación aislada. *Revista de Gastroenterología de México.* 2019;84:257–259.