



REVISTA DE GASTROENTEROLOGÍA DE MÉXICO

www.elsevier.es/rgmx



ORIGINAL ARTICLE

Safety and efficacy of small bowel polypectomy using a balloon-assisted enteroscope in pediatric patients with Peutz-Jeghers syndrome[☆]



G. Blanco-Velasco^{a,*}, O.V. Hernández-Mondragón^a, J.M. Blancas-Valencia^a,
V. Paz-Flores^a, D. Fuentes-Hernández^a, P. Rodríguez-González^b, B. González-Ortíz^b

^a Servicio de Endoscopia, Hospital de Especialidades, Centro Médico Nacional Siglo XXI, Instituto Mexicano del Seguro Social, Mexico City, Mexico

^b Servicio de Gastroenterología, Hospital de Pediatría, Centro Médico Nacional Siglo XXI, Instituto Mexicano del Seguro Social, Mexico City, Mexico

Received 14 March 2017; accepted 13 July 2017

Available online 4 April 2018

KEYWORDS

Peutz-Jeghers;
Enteroscopy;
Polypectomy;
Children

Abstract

Introduction and aims: Peutz-Jeghers syndrome is an autosomal dominant inherited pathology characterized by gastrointestinal hamartomatous polyps, predominantly in the small bowel, and pigmented mucocutaneous lesions. Guidelines suggest polypectomy with a balloon-assisted enteroscope when polyps are larger than 10 mm. Complications in adults can be as high as 6.8%, but there is little information on pediatric populations. Our aim was to describe the safety and efficacy of polypectomy in a group of pediatric patients with Peutz-Jeghers syndrome using balloon-assisted enteroscopy.

Materials and methods: A retrospective study was conducted at the *Hospital de Especialidades del Centro Médico Nacional Siglo XXI* on pediatric patients with Peutz-Jeghers syndrome that required balloon-assisted enteroscopy and polypectomy within the time frame of January 2010 and December 2015. Patients that underwent polypectomy with a push enteroscope were excluded from the study.

Results: A total of 35 polypectomies were performed on 4 patients (female/male: 3/1). The mean age of the patients was 13.7 years (range:11-16). Twelve enteroscopies were carried out, 8 of which were antegrade. A single-balloon enteroscope was used in 7 procedures and a double-balloon enteroscope in 5. The mean size of the polyps was 1.6 cm (range: 1-4 cm). A major complication (acute pancreatitis) presented in only one case (8.3%). No other major complications associated with the procedures were observed.

[☆] Please cite this article as: Blanco-Velasco G, Hernández-Mondragón OV, Blancas-Valencia JM, Paz-Flores V, Fuentes-Hernández D, Rodríguez-González P, et al. Seguridad y eficacia de la polipectomía en intestino delgado utilizando enteroscopia asistido por balones en pacientes pediátricos con síndrome de Peutz-Jeghers. *Revista de Gastroenterología de México*. 2018;83:234–237.

* Corresponding author. Avenida Cuauhtémoc 330, Colonia Doctores, Delegación Cuauhtémoc, C.P. 06720, Mexico City, Mexico. Phones: +5523077204 and 56276900 ext. 21317 and 21318.

E-mail address: gerardoblancov@hotmail.com (G. Blanco-Velasco).

PALABRAS CLAVE

Peutz-Jeghers;
 Enteroscopia;
 Polipectomía;
 Niños

Conclusion: Balloon-assisted enteroscopy with polypectomy in children is a safe and effective procedure, with complications similar to those reported in adults.

© 2018 Published by Masson Doyma México S.A. on behalf of Asociación Mexicana de Gastroenterología. This is an open access article under the CC BY-NC-ND license (<http://creativecommons.org/licenses/by-nc-nd/4.0/>).

Seguridad y eficacia de la polipectomía en intestino delgado utilizando enteroscopia asistido por balones en pacientes pediátricos con síndrome de Peutz-Jeghers

Resumen

Introducción y objetivos: El síndrome de Peutz-Jeghers (SPJ) es una enfermedad hereditaria, autosómica dominante caracterizada por la presencia de pólipos hamartomatosos en el tubo digestivo de predominio en el intestino delgado y que se acompañan de lesiones mucocutáneas pigmentadas. Algunas guías proponen la realización de polipectomía con enteroscopia asistido por balones (EAB) cuando los pólipos sean mayores de 10 mm. Las complicaciones en población adulta puede ser tan altas como 6.8%, sin embargo, en población pediátrica hay poca información. Nuestro objetivo es describir la seguridad y eficacia de la polipectomía en un grupo de pacientes pediátricos con SPJ tratados con EAB.

Material y métodos: Es un estudio retrospectivo realizado en el Hospital de Especialidades del Centro Médico Nacional Siglo XXI entre enero del 2010 y diciembre del 2015. Se incluyó a todos los pacientes pediátricos con SPJ que requirieron EAB y polipectomía. Se excluyeron las polipectomías realizadas con enteroscopia de empuje.

Resultados: Se realizaron un total de 35 polipectomías en 4 pacientes (femenino/masculino: 3/1). La edad media de los pacientes fue 13.7 (11-16) años. Se llevaron a cabo 12 enteroscopias, 8 de ellas anterógradas. El enteroscopia monobalón se utilizó en 7 procedimientos y el doble-balón en 5. El tamaño promedio de los pólipos fue de 1.6 cm (1-4 cm). Se presentó una complicación mayor (pancreatitis aguda) en un solo caso (8.3%). No se observaron otras complicaciones mayores.

Conclusión: El uso de EAB con polipectomía en niños es un procedimiento seguro y efectivo con complicaciones similares a las reportadas en adultos.

© 2018 Publicado por Masson Doyma México S.A. en nombre de Asociación Mexicana de Gastroenterología. Este es un artículo Open Access bajo la licencia CC BY-NC-ND (<http://creativecommons.org/licenses/by-nc-nd/4.0/>).

Introduction and aims

Peutz-Jeghers syndrome (PJS) is an autosomal dominant inherited pathology characterized by gastrointestinal hamartomatous polyps, predominantly in the small bowel, and pigmented mucocutaneous lesions.¹ The mean age of presentation of polyps is between 11 and 13 years and approximately 50% of patients will present with some type of symptom before 20 years of age. The most common symptoms in PJS are anemia, rectal bleeding, abdominal pain, obstruction, or intussusception.² The current American Society of Gastrointestinal Endoscopy and the European Society of Gastrointestinal Endoscopy guidelines recommend polypectomy with enteroscopy in adult patients with polyps larger than 10 mm, previously observed through radiologic methods or capsule endoscopy.^{3,4} Enteroscopy for intestinal polyp resection in adult patients with PJS has been reported to be successful and safe,⁵ but there is little information on the efficacy and safety of small bowel polypectomy through enteroscopy in children with PJS. The aim of the present study was to report on the experience in this respect at a tertiary care hospital center.

Materials and methods

A retrospective, descriptive, and observational study was carried out in which the data were reviewed of all patients with PJS that underwent balloon-assisted enteroscopy (BAE) with either a single balloon (SBE) or a double balloon (DBE) at the Endoscopy Service of the *Hospital de Especialidades del Centro Médico Nacional Siglo XXI* of the *Instituto Mexicano del Seguro Social*, within the time frame of January 2010 and December 2015. All the patients with PJS under 18 years of age that underwent small bowel polypectomy for polyps larger than 1 cm using SBE or DBE were included in the study, and all the patients that had push enteroscopy or intraoperative enteroscopy were excluded. The polypectomy technique consisted of submucosal injection of adrenaline diluted with saline solution (1:20,000) to raise the polyps and then resect them with a polypectomy loop, using the cut and clot method (fig. 1). Hemoclips were placed when there was bleeding after the cut. Minor complications were defined as those that were not life-threatening for the patient and that did not warrant hospital surveillance. Major complications were those

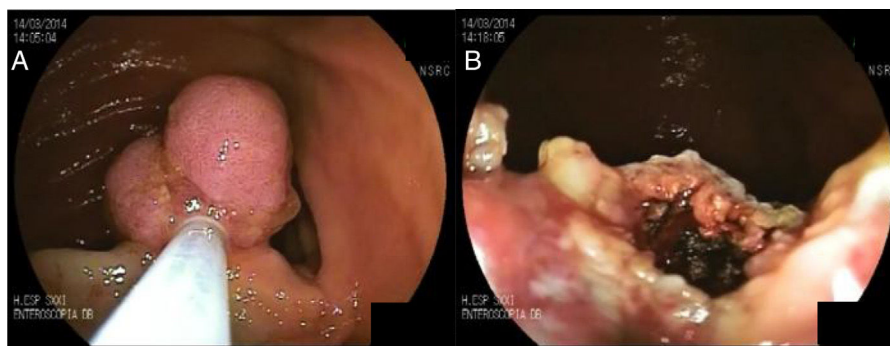


Figure 1 A) Polyp in the small bowel before resection and B) after resection.

Table 1 Characteristics, results, and complications of the enteroscopies.

No.	Sex	Age	Insertion route	Type of enteroscope	Resected polyps	Size (cm)	Major complications
1	F	13	Anal	SBE	5	1 – 4	No
2	F	13	Oral	SBE	3	1 – 3	No
3	F	12	Oral	SBE	1	1.5	No
4	F	13	Anal	SBE	5	1 – 4	No
5	F	13	Oral	SBE	3	1 – 3	No
6	F	16	Oral	DBE	1	2	Acute pancreatitis
7	F	13	Oral	DBE	4	1	No
8	F	15	Oral	SBE	3	1 – 2	No
9	F	16	Anal	DBE	1	1	No
10	F	15	Oral	DBE	4	1 – 4	No
11	F	15	Oral	DBE	4	1	No
12	M	11	Anal	DBE	1	1	No

F: female; M: male; SBE: single-balloon enteroscope; DBE: double-balloon enteroscope

that put the patient's life at risk and that required hospitalization.

For the statistical analysis, the means of the variables and their ranges (minimum and maximum) were calculated.

Results

A total of 35 polypectomies in 12 enteroscopies were performed on 4 patients, three of whom were girls. The mean age of the patients was 13.7 years (range: 11-16 years). Eight antegrade enteroscopies and 4 retrograde enteroscopies were carried out. SBE was utilized in 7 procedures and DBE in 5. A mean of 2.9 polyps were resected per enteroscopy (range: 1-5 polyps) and the mean size of the polyps was 1.6 cm (range: 1-4 cm). One patient required the placement of 2 hemoclips secondary to bleeding after polypectomy during the same enteroscopy. The only major complication registered was in one female patient that underwent polyp resection through antegrade DBE. She presented with acute pancreatitis secondary to the procedure, demonstrated through laboratory studies, and needed 4 days of hospitalization. No other major complications were demonstrated in the other procedures (Table 1).

Discussion and conclusions

Different studies have shown that the resection of intestinal polyps larger than 1 cm is safe in adults with PJS. In addition, that procedure significantly reduces the number of future surgeries required. Endoscopic treatment should always be initially attempted, given that the effectiveness of polypectomy through enteroscopy is considerably reduced when there has been a previous surgery.^{6,7} Complications ranging from 0 to 6.8% have been reported in small bowel polypectomy that include bleeding, acute pancreatitis, and perforation. The last two are the most common, at 2.7 and 5%, respectively.⁶⁻⁸ There is little information on the safety and efficacy of polypectomy through enteroscopy in the pediatric population with PJS. One article describes 52 polypectomies in 14 patients utilizing DBE, with no major complications.⁹ In another study, the authors report on endoscopic polypectomies with DBE in 46 cases, in which the only complication was post-polypectomy bleeding in 4 patients (7.1%), with a directly proportional association between bleeding and polyp size.¹⁰

In our study, there was a case of acute pancreatitis after enteroscopy as the only major complication (8.1%), but it was associated with the enteroscopy and not the polypectomy. The incidence of pancreatitis after enteroscopy in the general population can range from 0.3¹¹ to 12.5%.¹² There are several theories as to the cause and they include

pancreatic compression from a loop caused by the enteroscope,¹³ ischemia secondary to mechanical torsion of the pancreatic vasculature due to excessive rectifications,¹⁴ or, the most widely accepted, maintaining the inflated balloon near the Ampulla of Vater, causing inflammation of the papillae and pancreatic reflux.¹⁵ Even though most of the studies have reported pancreatitis in antero-gradе enteroscopies, it has also been seen in retrograde procedures.¹⁶ There is little evidence on the safety of enteroscopy in the pediatric population. Nishimura et al. presented a case series of 92 enteroscopies in which there were no major complications related to the procedure.¹⁷ Few cases of pancreatitis after enteroscopy have been described in the pediatric population. The only case series reporting pancreatitis in children is that by Yokoyama et al. in which there were 3 cases in 257 enteroscopies performed. All cases of pancreatitis were in the patients that had the antero-gradе procedure,¹⁰ as was the case in our study.

In conclusion, small bowel polypectomy with BAE in pediatric patients with PJS was a safe and efficacious procedure. The complications that presented in our case series were similar to those reported in adult populations. Pancreatitis after enteroscopy in children is a complication that has not been reported often, but then there are few case series conducted on the pediatric population. The greatest limitation of our study was the number of patients. More case series with a larger number of patients are needed to confirm the safety of those procedures in the pediatric population.

Ethical disclosures

Protection of human and animal subjects. The authors declare that no experiments were performed on humans or animals for this study.

Confidentiality of data. The authors declare that no patient data appear in this article.

Right to privacy and informed consent. The authors declare that no patient data appear in this article.

Financial disclosure

No financial support was received in relation to this study.

Conflict of interest

The authors declare that there is no conflict of interest.

References

1. Kopacova M, Tacheci I, Rejchrt S, et al. Peutz-Jeghers syndrome: Diagnostic and therapeutic approach. *World J Gastroenterol.* 2009;15:5397–408.
2. Gammon A, Jaspersen K, Kohlmann W, et al. Hamartomatous polyposis syndromes. *Best Pract Res Clin Gastroenterol.* 2009;23:219–31.
3. Khashab MA, Pasha SF, Muthusamy VR, et al. The role of deep enteroscopy in the management of small-bowel disorders. *Gastrointest Endosc.* 2015;82:600–7.
4. Pennazio M, Spada C, Eliakim R, et al. Small-bowel capsule endoscopy and device-assisted enteroscopy for diagnosis and treatment of small-bowel disorders: European Society of Gastrointestinal Endoscopy (ESGE) Clinical Guide. *Endoscopy.* 2015;47:352–76.
5. Beggs AD, Latchford AR, Vasen HF, et al. Peutz-Jeghers syndrome: A systematic review and recommendations for management. *Gut.* 2010;59:975–86.
6. Gao H, Van Lier MG, Poley JW. Endoscopic therapy of small-bowel polyps by double-balloon enteroscopy in patients with Peutz-Jeghers syndrome. *Gastrointest Endosc.* 2010;71:768–73.
7. Ohmiya N, Nakamura M, Takenaka H, et al. Management of small-bowel polyps in Peutz-Jeghers syndrome by using enteroclysis, double-balloon enteroscopy, and videocapsule endoscopy. *Gastrointest Endosc.* 2010;72:1209–16.
8. Sakamoto H, Yamamoto H, Hayashi Y, et al. Nonsurgical management of small-bowel polyps in Peutz-Jeghers syndrome with extensive polypectomy by using double-balloon enteroscopy. *Gastrointest Endosc.* 2011;74:328–33.
9. Urs AN, Martinelli M, Rao P, et al. Diagnostic and therapeutic utility of double-balloon enteroscopy in children. *JPGN.* 2014;58:204–12.
10. Yokoyama K, Yano T, Kumagai H, et al. Double-balloon enteroscopy for pediatric patients: Evaluation of safety and efficacy in 257 cases. *JPGN.* 2016;63:34–40.
11. Kopacova M, Tacheci I, Rejchrt S, et al. Double-balloon enteroscopy and acute pancreatitis. *World J Gastroenterol.* 2010;16:2331–40.
12. Pata C, Akyüz U, Erzin Y, et al. Post-procedure elevated amylase and lipase levels after double-balloon enteroscopy: Relations with double-balloon technique. *Dis Sci.* 2010;55:1982–8.
13. Heine GD, Hadithi M, Groenen MJ, et al. Double-balloon enteroscopy: Indications, diagnostic yield, and complications in a series of 275 patients with suspected small-bowel disease. *Endoscopy.* 2006;38:42–8.
14. Sunada K, Yamamoto H. Double-balloon enteroscopy: Past, present, and future. *J Gastroenterol.* 2009;44:1–12.
15. Latorre R, López-Albors O, Soria F, et al. Effect of the manipulation of the duodenal papilla during double balloon enteroscopy. *World J Gastroenterol.* 2016;22:4330–7.
16. Gerson LB, Tokar J, Chiorean M, et al. Complications associated with double balloon enteroscopy at nine US centers. *Clin Gastroenterol Hepatol.* 2009;7:1177–82.
17. Nishimura N, Yamamoto H, Yano T, et al. Safety and efficacy of double-balloon enteroscopy in pediatric patients. *Gastrointest Endosc.* 2010;71:287–94.