



CLINICAL IMAGE IN GASTROENTEROLOGY

## Annular pancreas. An unusual intraoperative finding<sup>☆</sup>



### Páncreas anular. Un hallazgo transoperatorio poco común

Z. Botello-Hernández\*, R.A. Fuentes-Reyes, O. Chapa-Azuela

Hepatopancreatobiliary Surgery Service, Hospital General de México «Dr. Eduardo Liceaga», Mexico City, Mexico

A 57-year-old man with an unremarkable past medical history complained of moderately intense localized pain in the epigastrium after eating solid foods, and later after drinking liquids. The accompanying nausea and vomiting caused important fluid and electrolyte imbalance, for which he was hospitalized. Laboratory tests and imaging studies were ordered and chronic cholecystitis with gallstones was diagnosed through ultrasound imaging (USG). A lesion infiltrating into the first portion of the duodenum and an ulcer were identified at endoscopy and at esophagogastroduodenography (EGD) (fig. 1). A computed axial tomography scan showed gas in the gallbladder and thickening of the gastric antrum and the duodenal bulb walls (figs. 2 and 3). Tumor markers were in the normal range. The patient underwent exploratory laparotomy that revealed chronic inflammation of the gall bladder, cholecystoduodenal fistula with loss of the normal anatomic arrangement, and annular pancreas (figs. 4 and 5) that did not compromise the integrity or permeability of the duodenum. Cholecystectomy was performed, the fistula was dismantled, and primary closure of the duodenum was carried out. The patient progressed favorably and is currently under follow-up at the hepatopancreatobiliary surgery clinic.

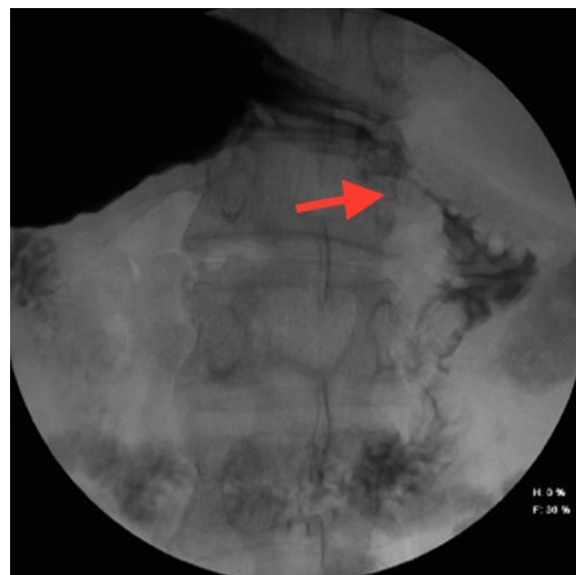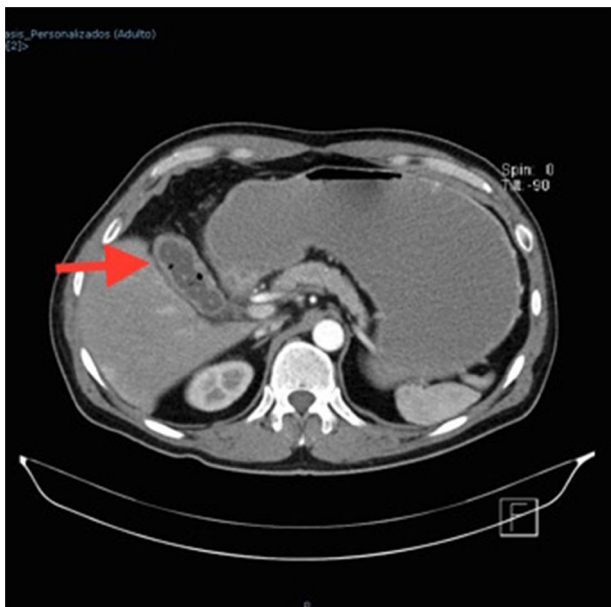


Figure 1 Esophagogastroduodenoscopy image showing the ulcerated lesion in the first part of the duodenum.

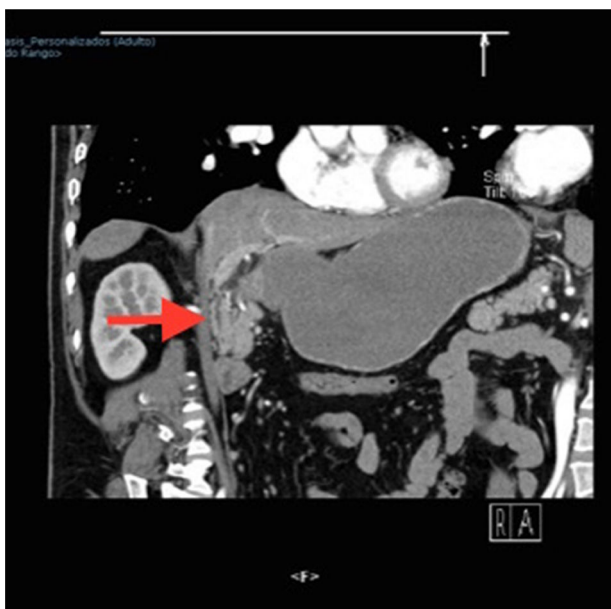<sup>☆</sup> Please cite this article as: Botello-Hernández Z, Fuentes-Reyes RA, Chapa-Azuela O. Páncreas anular. Un hallazgo transoperatorio poco común. Revista de Gastroenterología de México. 2018;83:64–65.

\* Corresponding author. Hospital General de México «Dr. Eduardo Liceaga», Dr. Balmis n.º 148, Colonia Doctores, Delegación Cuauhtémoc, C.P. 06726 Mexico City, Mexico. Tel.: +2789200, extension 0030/55 5075 5775.

E-mail address: [zazilbohz@yahoo.com.mx](mailto:zazilbohz@yahoo.com.mx)  
(Z. Botello-Hernández).



**Figure 2** Contrast-enhanced abdominal CAT scan. The arrow points to gas and stones inside the gallbladder.

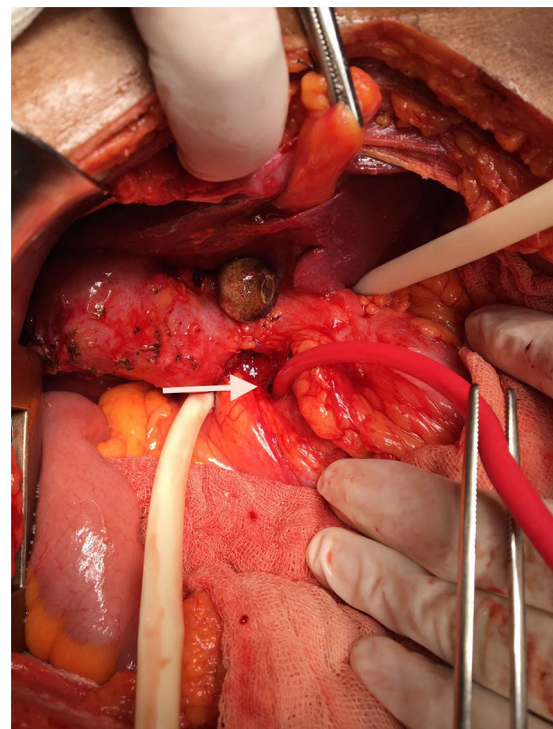


**Figure 3** Contrast-enhanced abdominal CAT scan showing the thickening of the gastric antrum and the duodenal bulb walls.

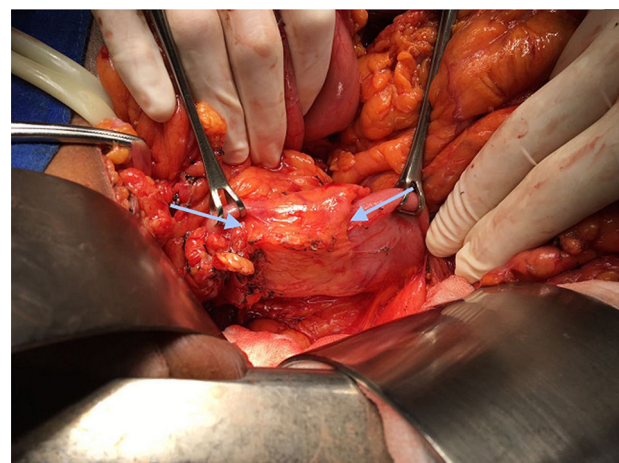
### Ethical disclosures

**Protection of human and animal subjects.** The authors declare that no experiments were performed on humans or animals for this study.

**Confidentiality of data.** The authors declare that no patient data appear in this article.



**Figure 4** Cholecystoduodenal fistula. The arrow indicates the communication with the duodenum.



**Figure 5** Annular pancreas, shown between the two arrows.

**Right to privacy and informed consent.** The authors declare that no patient data appear in this article.

### Conflict of interest

The authors declare that there is no conflict of interest.