

7. Whiley RA, Beighton D. Emended descriptions and recognition of *Streptococcus constellatus*, *Streptococcus intermedius*, and *Streptococcus anginosus* as distinct species. *Int J Syst Bacteriol.* 1991;41:1-5.

A. Soto-Sánchez\*, M. Hernández-Barroso,  
G. Hernández-Hernández, L. Gamba-Michel,  
M. Barrera-Gómez

*Servicio de Cirugía General y del Aparato Digestivo,  
Hospital Universitario Nuestra Señora de Candelaria, Santa  
Cruz de Tenerife, Tenerife, Spain*

\*Corresponding author. Servicio de Cirugía General y del Aparato Digestivo, Hospital Universitario Nuestra Señora de Candelaria, Carretera del Rosario 145, 38010 Santa Cruz de Tenerife, Tenerife, Spain. Tel.: +639826675.

E-mail address: [sotosanchezana@hotmail.com](mailto:sotosanchezana@hotmail.com)  
(A. Soto-Sánchez).

2255-534X/

© 2017 Asociación Mexicana de Gastroenterología. Published by Masson Doyma México S.A. This is an open access article under the CC BY-NC-ND license (<http://creativecommons.org/licenses/by-nc-nd/4.0/>).

## Upper gastrointestinal bleeding secondary to vigorous physical exercise<sup>☆</sup>



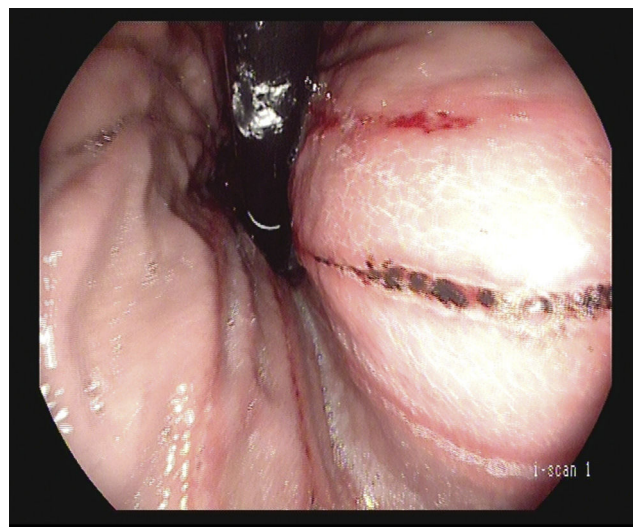
### Hemorragia digestiva alta secundaria a ejercicio físico intenso

The appearance of digestive symptoms in athletes is relatively frequent, and according to published case series, varies from 30-81%. Gastroesophageal reflux, nausea, vomiting, diarrhea, or transitory abdominal pain linked to exercise are the most frequent manifestations. Since the 1980s, numerous observational studies have shown that intense exercise can cause iron-deficiency anemia due to the appearance of gastritis, gastroduodenal ulcers, or erosions in the small bowel and colon. Depending on the degree of exercise, 7 to 85% of athletes can present with a positive fecal occult blood test upon finishing their training. Marked gastrointestinal bleeding is much less frequent and only anecdotal cases are found in the literature.<sup>1,2</sup> The first and only death due to gastrointestinal bleeding in a jogger was reported in 1982.<sup>3</sup>

A 30-year-old man with an unremarkable personal and family history came to the emergency department complaining of 3 bowel movements consistent with melena within the past 24 h. He stated that he had not taken any drug or gastrotoxic agent, no nutritional supplement, and no tobacco, alcohol, or other toxic substance. When asked about his usual physical activity, the patient said he rode a bicycle 4-5 times a week for approximately 45 min. When questioned about his activity in the morning before coming to the emergency department, he stated that 6 h before presenting with melena he had finished a 5-h bicycle ride at a much greater speed than usual. Physical examination revealed a heart rate of 105 bpm and the rest of his vital signs were normal. The laboratory work-up showed urea of 56 mg/dl (normal: 15-45 mg/dl) and hemoglobin of 12.7 g/dl (normal: 13-17.5 g/dl). The remaining results were normal. An emergency upper gastrointestinal endoscopy was

performed that identified 10 linear ulcers in the gastric body of approximately 10-15 mm in length and 2 mm in width, following the direction of the gastric folds. The ulcers had irregular edges and were covered with hematin (Forrest IIc) and fibrin (Forrest III) (fig. 1). Two biopsies were taken from the antrum, two from the gastric body, and one from each of the two largest ulcers. The patient remained under surveillance for 24 h, presented with no other episodes of melena, and was released under treatment with omeprazole 20 mg/12 h for 8 weeks. The results of the gastric biopsies were negative for *H. pylori* and there were no foci of dysplasia or metaplasia. Only some alterations consistent with the base of an ulcer and a mild, nonspecific, acute inflammatory infiltrate were documented. Upper gastrointestinal endoscopy was repeated at 12 weeks, confirming the endoscopic and histologic cure of the lesions. During follow-up, two 13C-labelled urea tests were carried out (with no previous PPI or antibiotic ingestion) to detect *H. pylori*, and were negative. The laboratory work-up was extended to include PTH and gastrin determination, and both were normal. Abdominal ultrasound had no significant findings. One year after the initial episode the patient is asymptomatic.

In 2001, Choi et al. conducted one of the most demonstrative studies, despite its small sample size,



**Figure 1** Retroflexed view of linear ulcers with hematin on their surface, Forrest IIc.

<sup>☆</sup> Please cite this article as: Rodríguez de Santiago E, Aguilera Castro L, García García de Paredes A, Ferre Aracil C, Martín de Argila de Prados C. Hemorragia digestiva alta secundaria a ejercicio físico intenso. *Revista de Gastroenterología de México.* 2018;83:350-351.

on upper gastrointestinal lesions secondary to vigorous physical activity. Theirs was a prospective study that included 16 long-distance runners (20 km) that underwent endoscopy, laboratory tests, and fecal occult blood testing. At endoscopy after the race, all the participants had developed gastritis, 6 presented with esophagitis, and one patient had a new gastric ulcer.<sup>4</sup> It is postulated that the reduction of splanchnic flow during exercise, the activation of the sympathetic nervous system, and the inhibition of the parasympathetic nervous system are the main pathophysiological mechanisms implicated in the damage of the gastrointestinal mucosa.<sup>1,2</sup> Clausen JP.<sup>5</sup> demonstrated that during maximum intensity exercise, the splanchnic flow can be reduced by up to 80%.<sup>1</sup> NSAID use, frequent in this population, has also been suggested as a cofactor, which would help explain the high prevalence of these types of lesions.<sup>2</sup>

On the other hand, there are epidemiologic studies that suggest that moderate physical activity could be a protective factor for the development of peptic ulcer and gastrointestinal bleeding. The 2 most representative studies in this regard were conducted by Pahor M. et al.<sup>6</sup> and Cheng Y. et al.<sup>7</sup>. Pahor et al. designed a prospective cohort study with 8,205 elderly patients (> 68 years of age) and a 3-year follow-up. The multivariate analysis showed that the subjects with greater physical activity had a relative risk of 0.7 (95% CI: 0.5-0.9), compared with the more sedentary subjects. In 2000, Cheng et al. analyzed the incidence of peptic ulcer in 11,413 patients, with respect to physical activity.<sup>7</sup> In their study, men with greater physical activity had a lower risk for duodenal ulcer. The observational nature of the two studies and the existence of confusion factors not included in the analysis, for example, economic status and its association with given patterns of consumerism or the heterogeneity in measuring the physical activity, limited the conclusions that the authors could make.

The use of anti-H2 drugs has not shown efficacy in the prevention of gastrointestinal blood loss in these patients.<sup>8</sup> Regarding PPIs, there is only one blinded and randomized clinical trial with pantoprazole 20 mg/24 h/3 days on 37 persons that competed in an ultra-marathon (246 km). Pantoprazole significantly reduced the rate of positive fecal occult blood tests (difference of risk: 0.86; 95% CI: 0.45-0.96),<sup>9</sup> but no clinically significant events were detected in any of the groups. Due to the sparsity of data on the pharmacologic prevention of these types of lesions, recommendations cannot be established, beyond moderation in physical activity and avoiding the use of NSAIDs.

In our patient, we can assume that there was a causal relation between intense physical exercise and the gastrointestinal bleeding, because he did not ingest gastrotoxic drugs, the temporal relation between the physical activity and the presentation of symptoms was 6 h, three tests for *H. pylori* were negative, there were no clinical and laboratory data suggesting an alternative etiology, and he has had no new episodes during the one-year follow-up, since moderating his physical activity.

This case illustrates an infrequent cause of gastrointestinal bleeding and underlines the importance of a thorough and directed anamnesis in patients with gastrointestinal bleeding of unknown origin.

## Conflict of interest

The authors declare that there is no conflict of interest.

## References

1. Waterman JJ, Kapur R. Upper gastrointestinal issues in athletes. *Curr Sports Med Rep.* 2012;11:99-104.
2. Peters HP, de Vries WR, van Berge-Henegouwen GP, et al. Potential benefits and hazards of physical activity and exercise on the gastrointestinal tract. *Gut.* 2001;48:435-9.
3. Thompson PD, Funk EJ, Carleton RA, et al. Incidence of death during jogging in Rhode Island from 1975 through 1980. *JAMA.* 1982;247:2535-8.
4. Choi SC, Choi SJ, Kim JA, et al. The role of gastrointestinal endoscopy in long-distance runners with gastrointestinal symptoms. *Eur J Gastroenterol Hepatol.* 2001;13:1089-94.
5. Clausen JP. Effect of physical training on cardiovascular adjustments to exercise in man. *Physiol Rev.* 1977;57:779-815.
6. Pahor M, Guralnik JM, Salive ME, et al. Physical activity and risk of severe gastrointestinal hemorrhage in older persons. *JAMA.* 1994;272:595-9.
7. Cheng Y, Macera CA, Davis DR, et al. Does physical activity reduce the risk of developing peptic ulcers. *Br J Sports Med.* 2000;34:116-21.
8. Moses FM, Baska RS, Peura DA, et al. Effect of cimetidine on marathon-associated gastrointestinal symptoms and bleeding. *Dig Dis Sci.* 1991;36:1390-4.
9. Thalmann M, Sodeck GH, Kavouras S, et al. Proton pump inhibition prevents gastrointestinal bleeding in ultramarathon runners: A randomised, double blinded, placebo controlled study. *Br J Sports Med.* 2006;40:359-62, discussion 362.

E. Rodríguez de Santiago<sup>a,\*</sup>, L. Aguilera Castro<sup>a</sup>,  
A. García García de Paredes<sup>a</sup>, C. Ferre Aracil<sup>a</sup>,  
C. Martín de Argila de Prados<sup>a,b</sup>

<sup>a</sup> *Servicio de Gastroenterología y Hepatología, Hospital Universitario Ramón y Cajal, Madrid, Spain*

<sup>b</sup> *IRICYS, Universidad de Alcalá, Alcalá de Henares, Madrid, Spain*

\*Corresponding author at: Hospital Universitario Ramón y Cajal, Gastroenterología y Hepatología, Ctra. de Colmenar Viejo km 9100, 28034 Madrid, Spain. Telephone: +0034651913608.

*E-mail address:* [e.rodriiguez\\_de\\_santiago@hotmail.com](mailto:e.rodriiguez_de_santiago@hotmail.com)

(E. Rodríguez de Santiago).

2255-534X/

© 2017 Asociación Mexicana de Gastroenterología. Published by Masson Doyma México S.A. This is an open access article under the CC BY-NC-ND license (<http://creativecommons.org/licenses/by-nc-nd/4.0/>).