



CLINICAL IMAGE IN GASTROENTEROLOGY

Acute intestinal bleeding after endoscopic polypectomy: Super-selective endovascular embolization in a clinically unstable patient[☆]



Hemorragia intestinal aguda después de polipectomía endoscópica: embolización superselectiva en un paciente clínicamente inestable

U.G. Rossi^{a,*}, G. Rubis-Passoni^b, P. Torcia^a, M. Cariati^a

^a *Interventional Radiology and Radiology Unit, Department of Diagnostic Sciences ASST Santi Paolo y Carlo-Hospital San Carlo Borromeo, Milan, Italy*

^b *Interventional Endoscopy and Diagnostic Unit, Department of Gastroenterology ASST Santi Paolo and Carlo-Hospital San Carlo Borromeo, Milan, Italy*

A 70-year-old man underwent endoscopy that revealed an adenomatous polyp in the ascending colon (fig. 1). It was removed in the same session through the placement of four endoscopic clips (fig. 2). Six hours after the endoscopic polypectomy, the patient presented with severe intermittent lower intestinal bleeding with an initial hemodynamically unstable status: heart rate > 80 bpm and systolic blood pressure <100 mmHg. After multidisciplinary agreement, the patient underwent urgent selective digital subtraction angiography of the superior mesenteric artery that showed the presence of active bleeding in the ascending colon in the area of the previous endoscopic polypectomy (fig. 3A). Super-selective transarterial embolization of the active bleeding was performed with success (fig. 3 B and C). Lower intestinal bleeding disappeared and the patient was hemodynamically stable immediately after the transarterial embolization. The patient did not need a bowel resection.

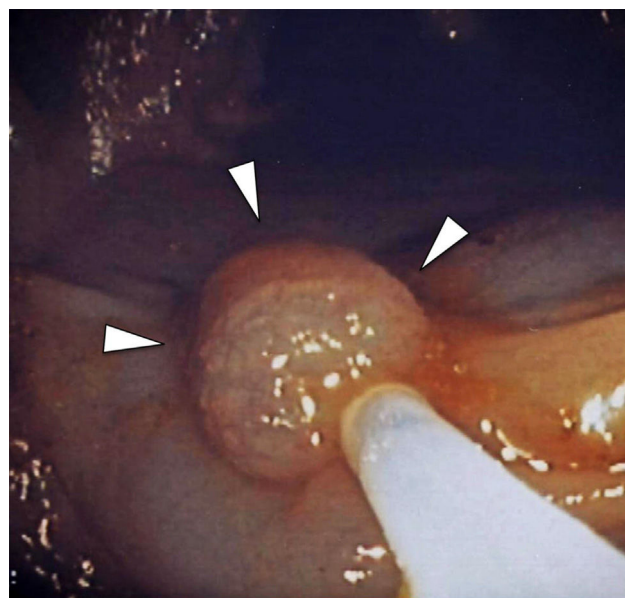


Figure 1 Ascending colon endoscopy showing an adenomatous polyp (arrowheads).

Lower intestinal bleeding after endoscopic polypectomy can be seen up to 2 weeks after the procedure. However, acute post-polypectomy bleeding is due to: insufficient

[☆] Please cite this article as: Rossi UG, Rubis-Passoni G, Torcia P, Cariati M. Hemorragia intestinal aguda después de polipectomía endoscópica: embolización superselectiva en un paciente clínicamente inestable. *Revista de Gastroenterología de México*. 2017;82:341–343.

* Corresponding author. Unidad de Radiología y Radiología Intervencionista, Departamento de Ciencias Diagnósticas, ASST Santi Paolo y Carlo-Hospital San Carlo Borromeo, Via Pio II 3, 20153 Milan, Italy. Tel.: +39 02 40222465; fax: +39 02 40222465.

E-mail address: urossi76@hotmail.com (U.G. Rossi).

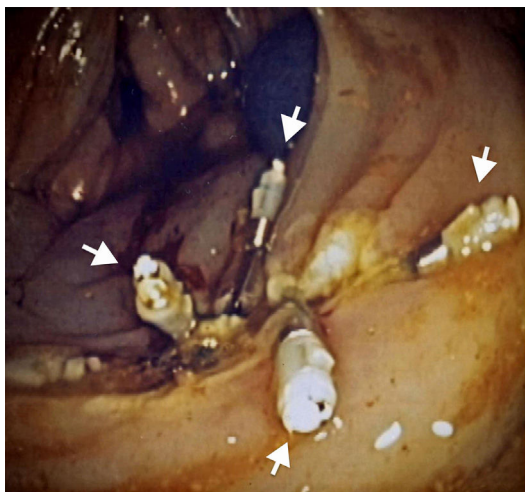


Figure 2 Final endoscopic control after polypectomy with the placement of four endoscopic clips (arrows).

hemostasis of the vessels, or sloughing of the surface coagulum¹. Despite advances in medical management, acute lower intestinal bleeding after endoscopic polypectomy remains a major complication with high morbidity and mortality. Interventional endoscopy and angiography are the fastest and least invasive therapies for controlling this major complication^{2,3}. Nevertheless, endovascular embolization is the preferred therapy when there is massive hemorrhage or in clinically unstable patients³.

Ethical disclosures

Protection of human and animal subjects. The authors declare that no experiments were performed on humans or animals for this study.

Confidentiality of data. The authors declare that no patient data appear in this article.

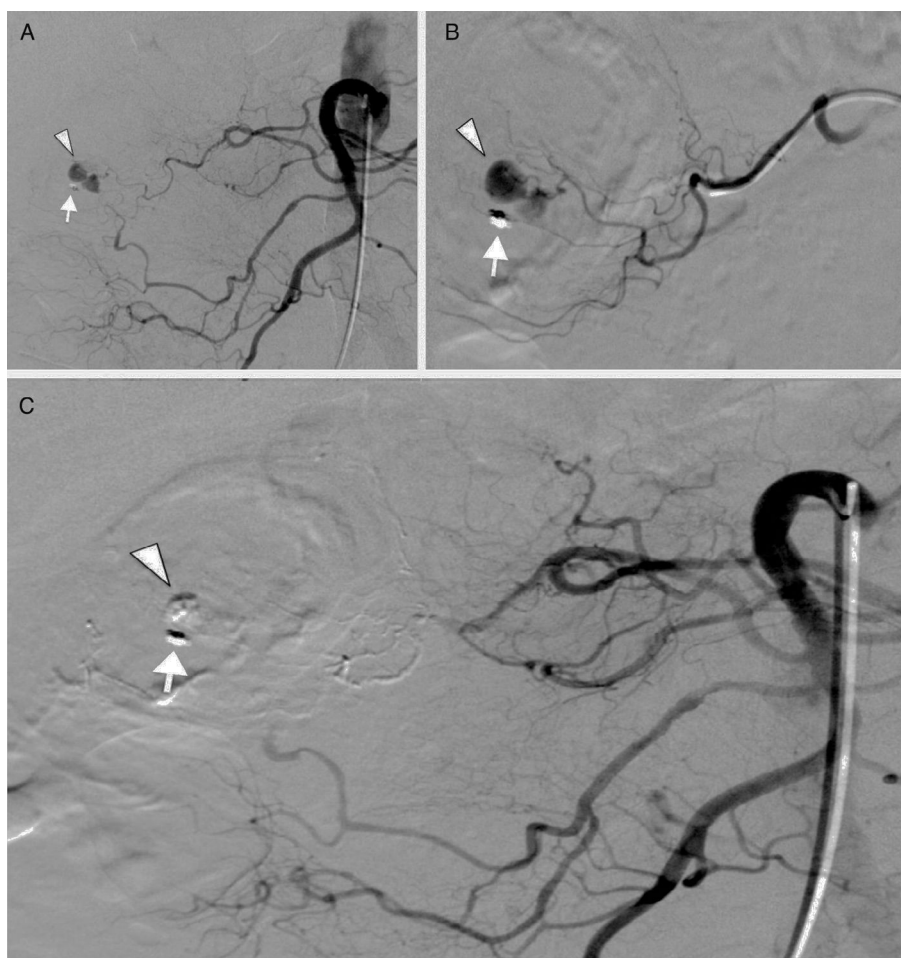


Figure 3 A) Selective digital subtraction angiography of the superior mesenteric artery that shows the presence of contrast extravasation (arrowhead) from the *vasa recta* of a distal arcade of the right colic artery, next to the only remaining endoscopic clip (arrow). B) Super-selective catheterization of the distal arcades of the right colic artery with contrast extravasation from the *vasa recta* (arrowhead) near the endoscopic clip (arrow). C) Final selective digital subtraction angiography of the superior mesenteric artery that shows the complete exclusion of the *vasa recta* of a distal arcade of the right colic artery embolized by n-butyl cyanoacrylate with the absence of contrast extravasation (arrowhead) near the endoscopic clip (arrow).

Right to privacy and informed consent. The authors declare that no patient data appear in this article.

Financial disclosure

No financial support was received in relation to this article.

Conflict of interest

The authors declare that there is no conflict of interest.

References

1. Weldon DT, Burke SJ, Sun S, et al. Interventional management of lower gastrointestinal bleeding. *Eur Radiol.* 2008;18:857–67.
2. Busch OR, van Delden OM, Gouma DJ. Therapeutic options for endoscopic haemostatic failures: The place of the surgeon and radiologist in gastrointestinal tract bleeding. *Best Pract Res Clin Gastroenterol.* 2008;22:341–54.
3. Cappell MS, Abdullah M. Management of gastrointestinal bleeding induced by gastrointestinal endoscopy. *Gastroenterol Clin North Am.* 2000;29:125–67.