



REVISTA DE GASTROENTEROLOGÍA DE MÉXICO

www.elsevier.es/rgmx



CLINICAL IMAGE IN GASTROENTEROLOGY

Rectal foreign body[☆]

Cuerpo extraño rectal

U.G. Rossi^{*}, S. Squarza, M. Cariati



Interventionist Radiology and Radiology Unit, Department of Diagnostic Science, ASST Santi Paolo y Carlo, San Carlo Borromeo Hospital, Milan, Italy

A 55-year-old man came to our emergency department due to acute abdominal pain. During the anamnesis, he stated having a foreign body—a vibrator—in his rectum. Abdominal examination revealed the presence of a mass at the level of the lower abdominal quadrants with no peritoneal signs. Digital rectal examination confirmed the presence of a foreign body. A conventional abdominal x-ray (Figure 1A) and an abdominal computed tomography scan (Figure 1B) demonstrated the presence of a vibrator in the rectosigmoid colon, and it was consequently extracted using a forceps and gentle traction. The post-removal sigmoidoscopy revealed no colorectal injuries.

It is common that patients that arrive at the emergency department with a foreign body in the rectum present with this situation due to transanal insertion of the object as a sexual practice. Rectal foreign bodies are more common in men than in women,^{1,2} and include such objects as vibrators, bottles, vegetables, fruits, cylindrical objects, and balls. These emergency department patients generally invent unusual stories to explain the presence of the object inside the rectum. Radiologic imaging is crucial for identifying rectal foreign bodies and determining the most appropriate treatment option.^{3,4}

[☆] Please cite this article as: Rossi UG, Squarza S, Cariati M. Cuerpo extraño rectal. Revista de Gastroenterología de México. 2017;82:255–256.

^{*} Corresponding author. Interventionist Radiology and Radiology Unit, Department of Diagnostic Science, ASST Santi Paolo y Carlo, San Carlo Borromeo Hospital, Via Pio II 3, 20153 Milan, Italy. Tel.: +39 02 40222465; fax: +39 02 40222465.

E-mail address: urossi76@hotmail.com (U.G. Rossi).

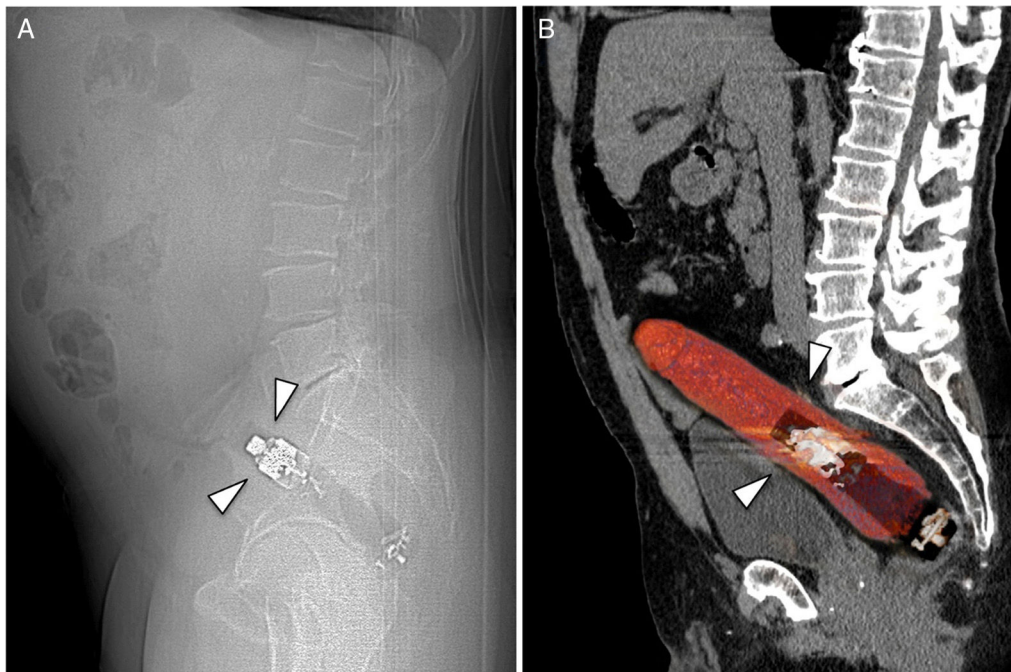


Figure 1 (A). Lateral view of a conventional abdominal x-ray that demonstrates the presence of a foreign body with a metal component, inserted into the rectum (arrowheads). (B). Sagittal reconstruction of an abdominal computed tomography scan that confirmed the presence of the foreign body with metal and plastic components, situated inside the rectum (arrowheads).

Ethical disclosures

Protection of human and animal subjects. The authors declare that the procedures followed were in accordance with the regulations of the relevant clinical research ethics committee and with those of the Code of Ethics of the World Medical Association (Declaration of Helsinki).

Confidentiality of data. The authors declare that no patient data appear in this article.

Right to privacy and informed consent. The authors declare that no patient data appear in this article.

Conflict of interest

The authors declare that there is no conflict of interest.

References

1. Akhtar MA, Arora PK. Case of unusual foreign body in the rectum. *Saudi J Gastroenterol.* 2009;15:131–2.
2. Odagiri H, Yasunaga H, Matsui H, et al. Difference in outcomes of rectal foreign bodies between males and females: A retrospective analysis of a national inpatient database in Japan. *Digestion.* 2015;92:165–70.
3. Cologne KG, Ault GT. Rectal foreign bodies: What is the current standard? *Clin Colon Rectal Surg.* 2012;25:214–8.
4. Hunter TB, Taljanovic MS. Foreign bodies. *Radiographics.* 2003;23:731–57.