

OTSC® system for the treatment of gastrointestinal perforations

Sistema de clip-OTSC® para el tratamiento de las perforaciones gastrointestinales

Gastrointestinal perforations are rare, but severe, complications in endoscopic procedures and they have traditionally been treated through surgery. Endoscopic perforation treatment has been achieved through the use of clips. However, all clips have limitations with respect to the amount of tissue they can hold together, the number of clips that can be used, and their usefulness in inflamed tissue. The Over-The-Scope-Clip (OTSC®) system (Over-The-Scope-Clip®, Tübingen, Germany) is a recently developed device in which the clip is mounted on the endoscope. This clip grabs large quantities of tissue and closes the lesion until it heals.^{1,2} We present herein the cases of 5 patients with iatrogenic gastrointestinal perforation treated with the OTSC® system. Three of the patients were women and 2 were men and they were between 52-80 years of age. Diagnoses were cholangiocarcinoma (n=1), rectal cancer (n=1), and pancreatic tumor (n=3). The perforations resulted from colonoscopy (n=1) and endoscopic ultrasound (n=4) and were located at the rectosigmoid junction (n=1), gastric antrum (n=1), duodenal bulb (n=2), and the posterior wall of the stomach (n=1). They had a diameter of 5 mm (n=1) and 10 mm (n=4). An 11-mm type "t" OTSC® was placed in all the cases. Adequate OTSC® placement in the 4 patients with upper gastrointestinal perforation was confirmed through the instillation of contrast medium under fluoroscopic control. The patient with duodenal perforation underwent surgery due to the persistence of abdominal pain. During that surgery hermetic closure of the perforation was confirmed, but the OTSC® was removed and replaced with a double suture line. In the patient with the perforation at the rectosigmoid junction, tissue friability secondary to radiotherapy caused a small tear at one end of the OTSC® and closure was completed by the placement of a hemostatic clip. In addition, the patient presented with massive pneumoperitoneum that was managed through a percutaneous, 14-gauge needle puncture. The 5 patients began oral liquid diet 3 days after the perforation and were released from the hospital between 5-8 days after the incident.

The OTSC® system has been shown to be effective in the treatment of gastric, duodenal, and colonic perforations after endoscopy.²⁻⁴ Treatment was successful in our patients because perforation size was 10 mm or smaller (Figures 1 and 2). Perforations up to 15 mm can be closed using the OTSC® system^{1,5} and larger defects can be closed using 2 OTSC®s or one OTSC® and a hemostatic clip, as was the case in our patient with the perforation at the rectosigmoid junction.^{1,6}

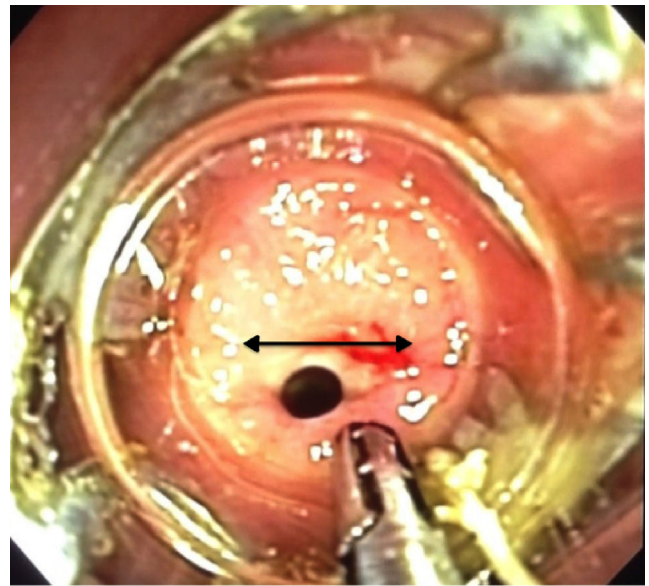


Figure 1 5-mm perforation (arrow shows the length).

In a study that included 48 patients with perforation, the etiology in 75% (n=36) of the cases was iatrogenic. The most common location was the stomach (n=13, 27.1%), followed by the esophagus (n=10, 20.8%), duodenum (n=9, 18.8%), colon (n=8, 16.7%), rectum (n=4, 8.3%), and jejunum/ileum (n=4, 8.3%). The OTSC® was placed immediately after the perforation in 89.6% (n=43) of the cases. In 40 patients that were analyzed, technical success was achieved in 97.5% (n=39) and long-term clinical success in 90% (n=36).⁷

The OTSC® system is an alternative to the surgical treatment of iatrogenic gastrointestinal perforations. Complications and the mortality rate related to its use are unknown. Surgical treatment should be considered when the OTSC® fails, the perforation is recognized late (> 24 h), or the patient shows signs of a systemic inflammatory response.⁸

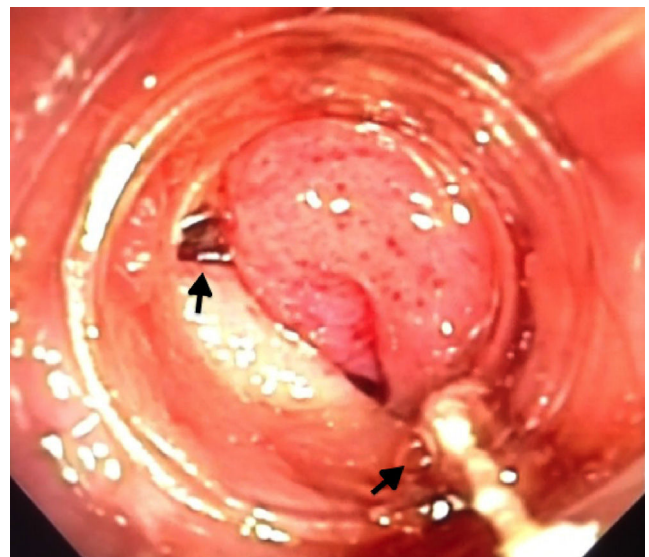

Figure 2 Placed clip (arrows show the ends of the clip).

☆ Please cite this article as: Alonso-Lárraga JO, Hernández Guerrero A, Ramírez-Solís ME, de la Mora Levy JG. Sistema de clip-OTSC® para el tratamiento de las perforaciones gastrointestinales. *Revista de Gastroenterología de México*. 2017;82:266-267.

Financial disclosure

No financial support was received in relation to this article.

Conflict of interest

The authors declare that there is no conflict of interest.

References

- Schurr MO, Hartmann C, Ho CN, et al. An Over-the-scope clip (OTSC) system for closure of iatrogenic colon perforations: Results of an experimental survival study in pigs. *Endoscopy*. 2008;40:584–8.
- Kirschniak A, Kratt T, Stüker D, et al. A new endoscopic over-the-scope clip system for treatment of lesions and bleeding in the GI tract: First clinical experiences. *Gastrointest Endosc*. 2007;66:162–7.
- Kim HS, Lee DK, Jeong YS, et al. Successful endoscopic management of a perforated gastric dysplastic lesion after endoscopic mucosal resection. *Gastrointest Endosc*. 2000;51:613–5.
- Baron TH, Gostout CJ, Herman L. Hemoclip repair of a sphincterotomy-induced duodenal perforation. *Gastrointest Endosc*. 2000;52:566–8.
- Parodi A, Repici A, Pedroni A, et al. Endoscopic management of GI perforations with a new over-the scope clip device. *Gastrointest Endosc*. 2010;72:881–6.

- Díez-Redondo P, Blanco JI, Lorenzo-Pelayo S, et al. A novel system for endoscopic closure of iatrogenic colon perforation using Ovesco® clip and omental patch. *Rev Esp Enferm Dig*. 2012;104:550–2.
- Haito-Chavez Y, Law JK, Kratt T, et al. International Multi-center experience with an-over-the-scope clipping device for endoscopic management of GI defects. *Gastrointest Endosc*. 2014;80:610–22.
- Yılmaz B, Unlu O, Roach E, et al. Endoscopic clips for the closure of acute iatrogenic perforations: Where do we stand? *Digestive Endoscopy*. 2015;27:641–8.

J.O. Alonso-Lárraga*, A. Hernández Guerrero, M.E. Ramírez-Solís, J.G. de la Mora Levy

Departamento de Endoscopia Gastrointestinal, Instituto Nacional de Cancerología, SSA, Mexico City, Mexico

*Corresponding author. Instituto Nacional de Cancerología, Av. San Fernando N.º 22, Colonia sección XVI, Delegación Tlalpan, CP 14800 Mexico City, Mexico. Tel.: +55,5628-0400 extension 52021.

E-mail address: joctavialonso@yahoo.com.mx (J.O. Alonso-Lárraga).

2255-534X/

© 2016 Asociación Mexicana de Gastroenterología. Published by Masson Doyma México S.A. This is an open access article under the CC BY-NC-ND license (<http://creativecommons.org/licenses/by-nc-nd/4.0/>).

Polypoid nodular scar after endoscopic submucosal dissection in the gastric antrum[☆]



Cicatriz nodular polipoide en el antro gástrico después de la disección endoscópica de la submucosa

Current guidelines consider endoscopic submucosal dissection (ESD) to be the treatment of choice for most patients with superficial gastric neoplasms with no risk, or very low risk, for lymph node metastasis.¹ It enables en bloc resection of tumors larger than 2 cm and reliable histologic assessment of the resected specimen to determine the potential curability of the endoscopic resection. In general, the expected scenario after successful ESD is a consolidated and homogeneous scar without any residual tumor, infiltration, or polypoid formation. Interestingly, we have been observing the development of anomalous and bizarre postoperative scars with a relatively large and protruded polypoid nodular neof ormation in a subset of patients after curative ESD, particularly for lesions located in the antrum.

The aim of this report was to describe an aberrant polypoid nodular scar (PNS) in a patient after curative ESD and to discuss the theoretical reason for its occurrence.

A 53-year-old man was referred to us from another institution. He had a superficially elevated 4-cm lesion with a nodular component and central depression, located in the greater curvature of the antrum (fig. 1A). The preoperative biopsy was consistent with adenoma with low-grade dysplasia. We suspected high-grade dysplasia due to the large size of the lesion and proposed endoscopic en bloc resection by means of ESD. The procedure was carried out under general anesthesia utilizing a single-channel gastro-scope (EG-450RD5, Fujifilm Co., Japan) with the water-jet function and a 3.2 mm working channel. A transparent 4-mm straight cap was attached to the tip of the endoscope (Elastic Touch®, Top Corporation, Japan). Careful assessment of the tumor borders was carried out with white-light and Flexible Spectral Imaging Color Enhancement (FICE) and the markings were placed 5 mm beyond the edges of the tumor. Submucosal (SM) injection was carried out with 0.4% hyaluronic acid (Muco-up®, Johnsons & Johnsons, Japan). ESD was performed with a 2.5 mm ball-tipped Flush-Knife (DK2618J-B25, Fujifilm Co., Japan) connected to an electrosurgical generator (VIO® 200D, ERBE Co., Turbigen, Germany) and a water-jet infusion pump (JW-2, Fujifilm Co., Japan). After SM injection with a standard 25-gauge injector needle (Interject, M00518111, Boston Scientific, USA), a circumferential mucosal incision was made outside of the markings (Endocut 1, Effect 2, Duration 3, Interval 2). SM dissection was undertaken in the forced coagulation mode (Effect 3, 45 watts), using the cap to expose

[☆] Please cite this article as: Arantes V, Uedo N, Salgado Pedrosa M. Cicatriz nodular polipoide en el antro gástrico después de la disección endoscópica de la submucosa. *Revista de Gastroenterología de México*. 2017;82:267–269.