

Fully covered metal stents for the treatment of leaks after esophago gastric oncologic surgery[☆]



Prótesis metálicas totalmente cubiertas para el tratamiento de las fugas después de cirugía oncológica esófago-gástrica

Anastomotic leaks present in 8.3 to 5.9% of patients after esophagectomy and gastrectomy, respectively.¹ Saliva and gastric juice leakage into the mediastinum is responsible for 30-40% of postoperative deaths.¹ The use of self-expanding metal stents has been reported to aid in cicatrization and reduce mortality.² The aim of this report was to present our experience in 7 cases of postoperative leakage after esophago gastric oncologic surgery treated through fully covered self-expanding metal stents (FCSEMSs).

Between January 2013 and October 2014, 7 patients with postoperative leakage were treated (Table 1). Four were men and 3 were women and their ages ranged

from 30 to 64 years. The etiologic diagnosis was cancer of the gastroesophageal junction in 2 patients, gastric adenocarcinoma in 4, and esophageal adenocarcinoma in one patient. All the patients were candidates for surgical resection. Esophagojejunal anastomosis was the surgical reconstruction performed in 5 patients and esophago gastric anastomosis was performed in 2. During the endoscopic check-up, the approximate anastomotic defect percentage was calculated as follows: $\frac{1}{4}$ of the circumference = 25%, $\frac{1}{2}$ = 50%, and $\frac{3}{4}$ = 75%. The endoscopic study revealed defects at the level of the anastomosis of < 25 to 70% of the circumference (Fig. 1). The time lapse between the surgery and diagnosis of the leak was from 4 to 20 days and it varied from 5 to 40 days between the surgery and stent placement. A FCSEMS (SX-ELLA Stent Esophageal HV, Czech Republic) with an 85 mm length and distal, mid, and proximal diameters of 25, 20, and 24 mm, respectively, was placed in all the cases under sedation and fluoroscopic control (Fig. 1). It was a silicone-covered nitinol stent. Six of the 7 patients had immediate occlusion of the leak after contrast medium instillation under fluoroscopic control (Fig. 1). Leakage output stopped within 24 h after stent placement in 6 patients

Table 1 Patient characteristics and results.

Patients	1	2	3	4	5	6	7
Age	64	59	49	54	49	30	56
Sex	Man	Man	Woman	Man	Woman	Woman	Man
Tumor	GEJ cancer	EAC	GAC	GEJ cancer	GAC	GAC	GAC
Type of anastomosis	EJA	EGA	EJA	EGA	EYA	EYA	EYA
Percentage of dehiscence of the anastomosis	25%	50%	70%	<25%	25%	25%	50%
PO day of leak diagnosis	9	8	5	16	20	4	8
PO day of stent placement	14	40	20	18	32	5	21
Commencement 2 of oral diet (after stent)		1	1	-----	3	-----	3
Days with stent	31	30	33	40	28	2	27
Pre-stent treatment	Antibiotic	EN Antibiotic	PN Antibiotic	PN Antibiotic	PN Antibiotic	Antibiotic	PN Antibiotic
Result	Cure	Cure	Cure	Cure	Cure	QR-Death	Cure

EAC: esophageal adenocarcinoma; EGA: esophago gastric anastomosis; EJA: esophagojejunal anastomosis; EN: enteral nutrition; GAC: gastric adenocarcinoma; GEJ: gastroesophageal junction; PN: parenteral nutrition; PO: postoperative; QR: surgical reintervention

[☆] Please cite this article as: Alonso-Lárraga JO, de la Mora Levy JG, Hernández Guerrero A, Rodarte-Shade M, Ramírez-Solís ME. Prótesis metálicas totalmente cubiertas para el tratamiento de las fugas después de cirugía oncológica esófago-gástrica. *Revista de Gastroenterología de México*. 2017;82:100-102.

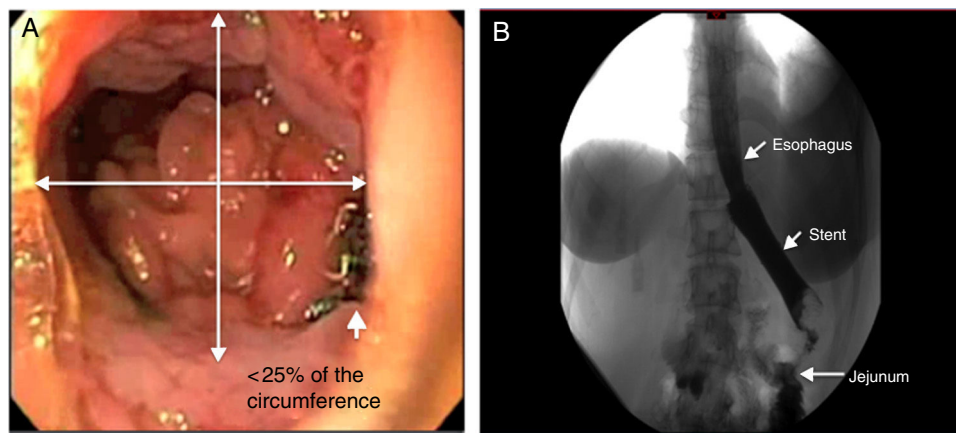


Figure 1 A) The endoscopic image shows the leakage site. B) The x-ray shows the esophageal stent with no contrast agent leakage.

and was confirmed clinically and through a barium swallow (Fig. 1). Oral diet was begun 1-3 days after stent placement in 5 patients, one patient received parenteral nutrition due to a swallowing disorder secondary to a cerebral hemorrhage, and one patient had surgical reintervention without beginning the oral diet. The FCSEMSs were removed using conventional biopsy forceps, putting pressure on the stent loop. The stents were easily removed with no complications 27-40 days after placement in 6 patients. Endoscopic check-up and barium swallow showed no evidence of leakage after stent removal. There was one case of partial stent displacement, but it continued to cover the leakage site. Granulation tissue was found in the same patient at the distal end of the stent. The stent covering was undamaged at the time of extraction in 6 of the 7 patients. We had no stent-related complications or deaths.

Important considerations in the treatments of leaks include their etiology, size, and the clinical condition of the patient. Different studies have shown the feasibility of placing self-expanding metal stents in patients with anastomotic leakage that would otherwise require a surgical intervention.²⁻⁴ In our cases, clinical success reached 85.7%, coinciding with other studies that have reported success rates of 48-100%, with no difference between the result and the type of stent used.⁵⁻⁹ Studies in animals suggest that stent placement for 30 days is sufficient for tissue cicatrization.¹⁰ In our patients, the stents were in place for 27-40 days, a length of time similar to that of a previous study.¹⁰ With respect to the precise time for stent placement, some authors favor placement within 24 h of leak diagnosis to limit contamination of the cavity and promote cicatrization.^{1,10} However, there have also been reports stating that late placement can result in closure of the anastomotic leak.^{1,6} In our short experience, the stents were removed 5 to 32 days after surgery and cicatrization was achieved in 6 of the 7 patients. One report suggests that to be successful, the leaks should be smaller than 70% of the circumference of the anastomosis and there should be no ischemia.¹ Our findings were similar, except in one patient with 25% dehiscence of the anastomosis. In that case the leak became larger after stent placement, which was

documented through tomography, and the patient underwent surgical reintervention.

FCSEMS placement appears to be a feasible and less invasive option in patients with postoperative leaks after esophagogastric oncologic surgery. We used a stent with a larger distal diameter and a proximal ring designed to prevent migration. Such characteristics can be useful in patients with postoperative leaks. It is important to consider surgical reintervention when there are unsatisfactory results.

Financial disclosure

No financial support was received in relation to this study/article.

Conflict of interest

The authors declare that there is no conflict of interest.

References

1. Moyes LH, MacKay CK, Forshaw MJ. The use of self-expanding plastic stents in the management of oesophageal leaks and spontaneous oesophageal perforations. *Diagn Ther Endosc.* 2011;2011:418103.
2. Tuebergen D, Rijcken E, Menningen R, et al. Treatment of thoracic esophageal anastomotic leaks and esophageal perforations with endoluminal stents: Efficacy and current limitations. *J Gastrointest Surg.* 2008;12:1168-76.
3. Karbowski M, Schembre D, Kozarek R, et al. Polyflex self-expanding removable plastic stents: Assessment of treatment efficacy and safety in a variety of benign and malignant conditions of the esophagus. *Surg Endosc.* 2008;22:1326-33.
4. Blackmon SH, Santora R, Schwarz P, et al. Utility of removable esophageal covered self-expanding metal stent for leak and fistula management. *Ann Thorac Surg.* 2010;89:931-7.

5. Freeman RK, Ascoti AJ, Wozniak TC. Postoperative esophageal leak management with the Polyflex esophageal stent. *J Thorac Cardiovasc Surg.* 2007;133:333–8.
6. Hunerbein M, Stroszczyński C, Moesta KT, et al. Treatment of thoracic anastomotic leaks after esophagectomy with self-expanding plastic stents. *Ann Surg.* 2004;240:801–7.
7. Kauer WK, Stein HJ, Dittler HJ, et al. Stent implantation as a treatment option in patients with thoracic anastomotic leaks after esophagectomy. *Surg Endosc.* 2008;22:50–3.
8. Langer FB, Wenzl E, Prager G, et al. Management of postoperative esophageal leaks with the Polyflex self-expanding covered plastic stent. *Ann Thorac Surg.* 2005;79:398–403.
9. Fischer A, Thomusch O, Benz S, et al. Nonoperative treatment of 15 benign esophageal perforations with self-expandable covered metal stents. *Ann Thorac Surg.* 2006;81:467–742.
10. Donatelli G, Dhumane P, Perreta S, et al. Endoscopic placement of fully covered self expanding metal stents for management of post-operative foregut leaks. *J Minim Access Surg.* 2012;8:118–24.

J.O. Alonso-Lárraga*, J.G. de la Mora Levy, A. Hernández Guerrero, M. Rodarte-Shade, M.E. Ramírez-Solís

Gastrointestinal Endoscopy Service, Instituto Nacional de Cancerología, SSA, Mexico City, Mexico

* Corresponding author. Instituto Nacional de Cancerología, Av. San Fernando No. 22, Colonia sección XVI, Delegación Tlalpan CP 14800, Mexico City, Mexico. Tel.: +55 5628-0400, ext.: 52021.

E-mail address: joctavioalonso@yahoo.com.mx (J.O. Alonso-Lárraga).

2255-534X/

© 2016 Asociación Mexicana de Gastroenterología. Published by Masson Doyma México S.A. This is an open access article under the CC BY-NC-ND license (<http://creativecommons.org/licenses/by-nc-nd/4.0/>).