



CLINICAL IMAGE IN GASTROENTEROLOGY

Acute gastric dilation after trauma[☆]



Dilatación gástrica aguda posterior a traumatismo

S. Rodríguez-Jacobo^{a,*}, J.S. Jacobo-Karam^b, G. Valencia-Pérez^c

^a Universidad Digital del Estado de México (UDEM), Durango, Mexico

^b Hospital General 450, Secretaría de Salud Durango, Durango, Mexico

^c Hospital General, Secretaría de Salud Durango, Durango, Mexico

Received 14 April 2015; accepted 12 June 2015

A 65-year-old woman had a past history of diabetes mellitus of 14-year progression, high blood pressure since 2006, and diabetic neuropathy. For the last year, she presented with postprandial fullness and burping that improved with metoclopramide. On June 26, 2012, the patient became dizzy and fell, resulting in trauma to the left hypochondrium and the last costal arcs. She began to have intense pain at that site and limited respiratory movements. Chest x-ray was normal (fig. 1). She received diclofenac but did not improve. A rib fracture was suspected and blockade was performed. The pain persisted and 2 days later she presented with predominantly left upper abdominal bloating, increased pain, and abundant burping, and so she went to the emergency department. Physical examination revealed BP 125/80, HR 88/min, left basal hypoventilation, asymmetric abdomen with important distension in the epigastrium and left hypochondrium. She had pain upon palpation and tympanism, negative decompression, and peristalsis was present. Laboratory work-up reported: Hb 11.6 g/dl, leukocytes 8400/mm³, glucose 193 mg/dl, platelets, serum urea and creatinine, electrolytes, amylase, lipase, and CPK were normal. ECG was normal. Plain abdominal x-ray (PAX)

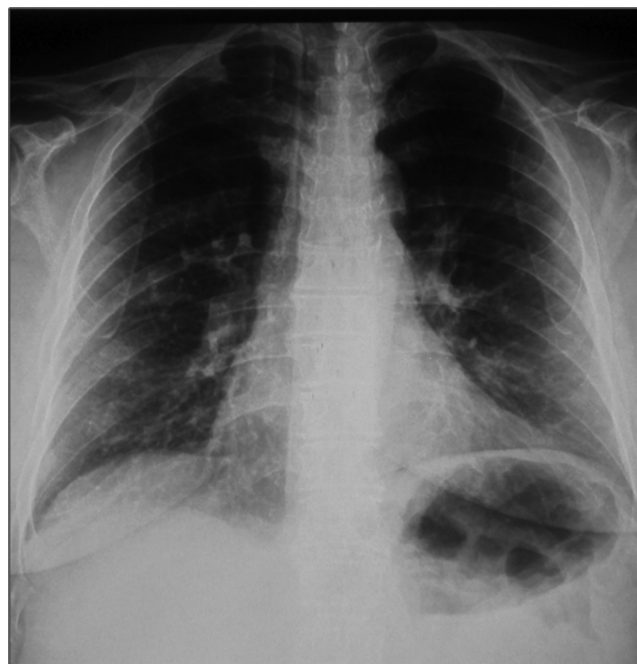

Figure 1 Initial chest x-ray within normal parameters.

[☆] Please cite this article as: Rodríguez-Jacobo S, Jacobo-Karam JS, Valencia-Pérez G. Dilatación gástrica aguda posterior a traumatismo. Revista de Gastroenterología de México. 2016;81:48-50.

* Corresponding author. Citlaltépetl, 109 Fraccionamiento Madrazo, CP 34075 Durango, Durango, México. Phone: +8117906752; fax: +618 8 11 25 61.

E-mail address: sofiarj13@hotmail.com (S. Rodríguez-Jacobo).

showed sudden gastric dilation with thin walls, no fluid and no air (figs. 2 and 3). An NG tube was placed and 6 h later the pain and distension were reduced. Another PAX showed a normal-sized gastric chamber (fig. 4).

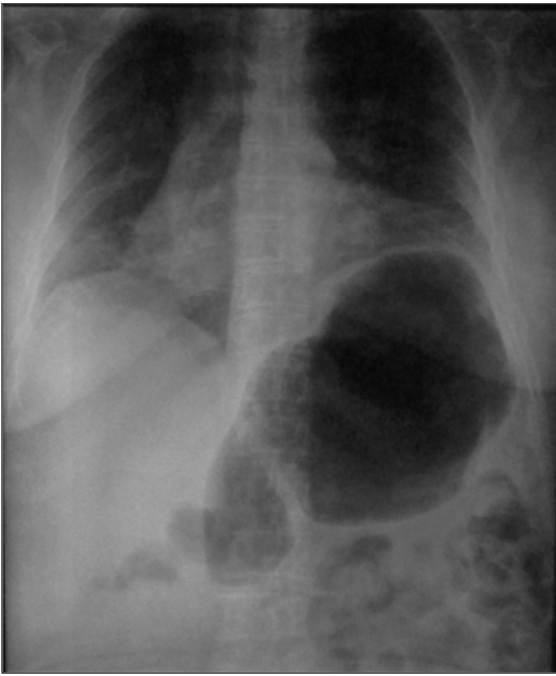


Figure 2 Follow-up chest x-ray showing elevation of the left hemidiaphragm due to important dilation of the gastric chamber that was not apparent in the previous x-ray.

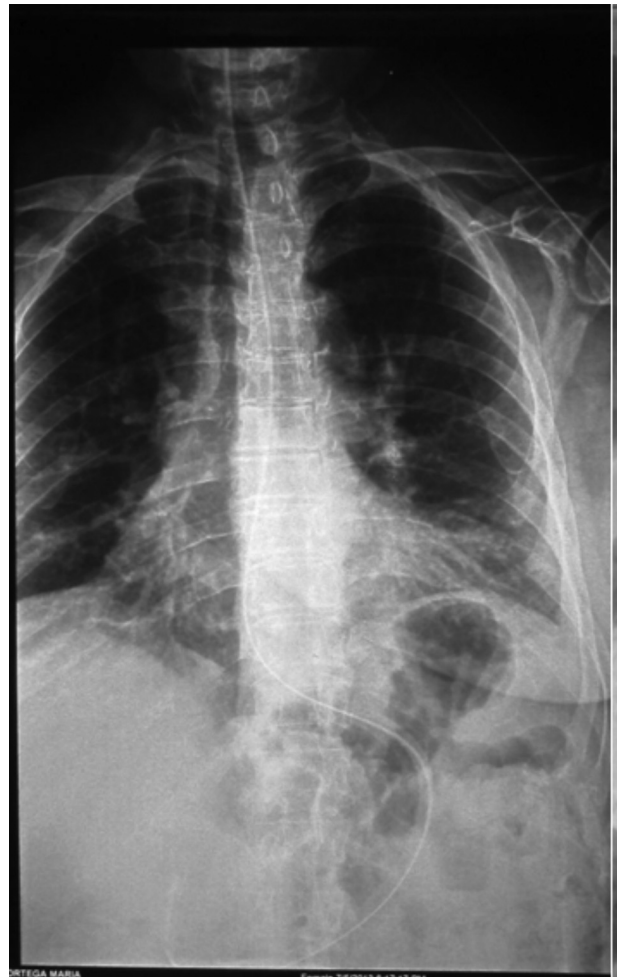


Figure 4 Radiologic study after the placement of the nasogastric tube showing normalization of the gastric dimensions.

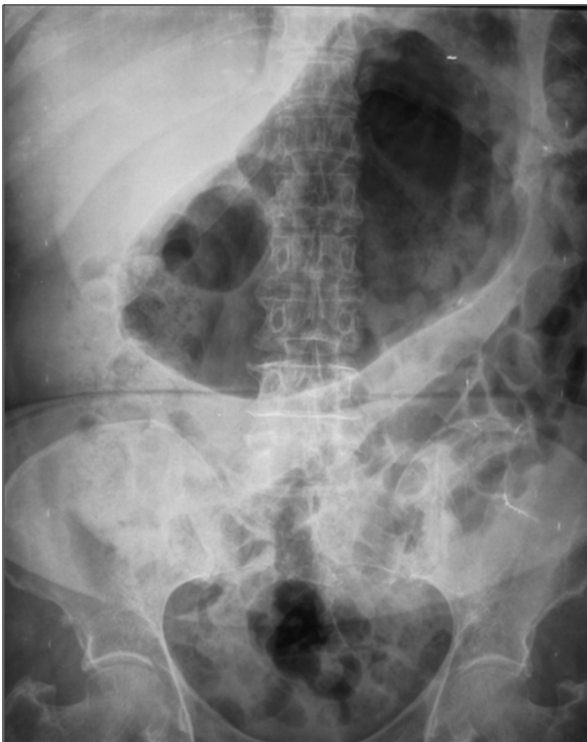

Figure 3 Complementary abdominal x-ray showing the important dilation of the gastric chamber, but the caliber of the bowel segments and the thickness of the walls are normal.

The exact causes of gastric dilation are not fully understood. This condition has been seen in cases of eating disorders, hiatal hernia volvulus, electrolyte abnormalities, superior mesenteric artery syndrome, and trauma.¹ The present case was a patient that developed gastric dilation secondary to trauma, which according to present theories, is explained by compression of the celiac ganglion causing an inhibitory vagal reflex, thus conditioning the gastric chamber dilation.²

Ethical responsibilities

Protection of persons and animals. The authors declare that no experiments were performed on humans or animals for this study.

Data confidentiality. The authors declare that they have followed the protocols of their work center in relation to the publication of patient data.

Right to privacy and informed consent. The authors have obtained the informed consent of the patients and/or subjects referred to in the article. This document is in the possession of the corresponding author.

Financial disclosure

No financial support was received in relation to this study.

Conflict of interest

The authors declare that there is no conflict of interest.

References

1. Steen S, Lamont J, Petrey L. Acute gastric dilation and ischemia secondary to small bowel obstruction. *Proc (Bayl Univ Med Cent)*. 2008;21:15–7.
2. Kasenally AT, Felice AG, Logie JR. Acute gastric dilatation after trauma. *Br Med J*. 1976;2:21.