

pericarditis, observed after abdominal surgery or blunt trauma. These causes were satisfactorily ruled out in our patient, and only liver cirrhosis was documented as the cause of chylous ascites, which is seen in 0.5-1% of cases. Due to the poor response in our patient, other measures will be carried out, such as middle-chain triglyceride or octreotide use.^{6,7} Another therapeutic option is the administration of orlistat, which has been reported to reduce the quantity of triglycerides in the ascitic fluid in patients with cirrhosis.⁸

Financial disclosure

No financial support was received in relation to this article.

Conflict of interest

The authors declare that there is no conflict of interest.

References

1. Lazarus DL, Al-Busafi SA, Hilzenrat N. Chylous ascitis secondary to giant liver hemangioma. *Case Rep Gastroenterol.* 2012;6:478–83.
2. Almakdisi T, Massoud S, Makdisi G. Lymphomas and chylous ascitis: Review of the literature. *Oncologist.* 2005;10:632–5.
3. Yilmaz M, Akbulut S, Isik B, et al. Chylous ascitis after liver transplantation: Incidence and risk factors. *Liver Transpl.* 2012;18:1046–52.
4. Steinemenn DC, Dindo D, Clavien PA, et al. Atraumatic chylous ascitis: Systematic review on symptoms and causes. *J Am Coll Surg.* 2011;212:899–905.
5. Rector WG. Spontaneous chylous ascites of cirrhosis. *J Clin Gastroenterol.* 1984;6:369–72.
6. Huang Q, Jiang ZW, Jiang J, et al. Chylous ascites: Treated with total parenteral nutrition and somatostatin. *World J Gastroenterol.* 2004;10:2588–91.
7. Leong RW, House AK, Jeffrey GP. Chylous ascites caused by portal vein thrombosis treated with octreotide. *J Gastroenterol Hepatol.* 2003;18:1211–3.
8. Chen J, Lin RK, Hassanein T. Use of orlistat (xenical) to treat chylous ascites. *J Clin Gastroenterol.* 2005;39:831.

J.P. Piña-Pedraza^a, L. Álvarez-Avalos^{a,b,*},
J.M. Vargas-Espinosa^a, A. Salcedo-Gómez^a,
J. Carranza-Madriral^a

^a *Internal Medicine Service, Hospital General "Dr. Miguel Silva" Secretaría de Salud, Morelia, Michoacán, Mexico*

^b *Universidad Michoacana de San Nicolás de Hidalgo, Morelia, Michoacán, Mexico*

* Corresponding author. Diego José Abad 193 – 3 Colonia Centro, C.P. 58000 Morelia, Michoacán, México.
Tel.: +443 313 33 35.

E-mail address: drlaa@prodigy.net.mx (L. Álvarez-Avalos).

Multiple scalp metastases as a first manifestation of pancreatic adenocarcinoma[☆]



Metástasis múltiples en cuero cabelludo como primera manifestación de adenocarcinoma de páncreas

An 81-year-old woman had a past history of well-controlled high blood pressure and essential tremor treated with propranolol. She consulted her family physician after noticing the appearance of 8-10 painful lesions on her scalp over the last 3 weeks. The lesions (fig. 1) consisted of firm nodules, adhered to deep layers, between 1 and 2 cm in size, and the majority had an ulcerated surface covered with small blood clots. She was referred to the dermatology service for consultation. Two weeks later, before said consultation, she presented with marked mucocutaneous jaundice, choloria, and acholia, for which she came to the emergency department of our center and was admitted to complete her evaluation. A cutaneous biopsy was ordered from the dermatology service. Blood test results were bilirubin 10.2 mg/dl, AST 111 IU/ml, ALT 227 IU/ml, GGT 3300 IU/ml,

and CA-19-9 436 IU/ml (normal limit < 37 IU/ml). An abdominal CT scan showed a mass located in the uncinate process of the pancreas that conditioned dilation of the common bile duct and duct of Wirsung. Peritoneal, pulmonary, and paravertebral muscle lesions suggestive of metastasis were also observed. Due to these findings, endoscopic ultrasound fine needle aspiration of the pancreatic mass was performed. The scalp biopsy (fig. 2) revealed the presence of cutaneous metastases with morphologic and immunohistochemical characteristics consistent with a pancreatic origin (positive for cytokeratins 7 and 19 and negative for

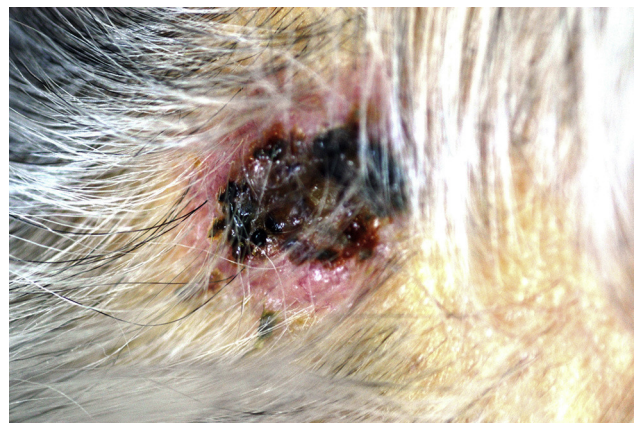

Figure 1 Scalp nodule.

[☆] Please cite this article as: Tavío-Hernández E, Cañete-Ruiz Á, Moreno C, Urech M, Cano-Ruiz A. Metástasis múltiples en cuero cabelludo como primera manifestación de adenocarcinoma de páncreas. *Revista de Gastroenterología de México.* 2015;80:287–289.

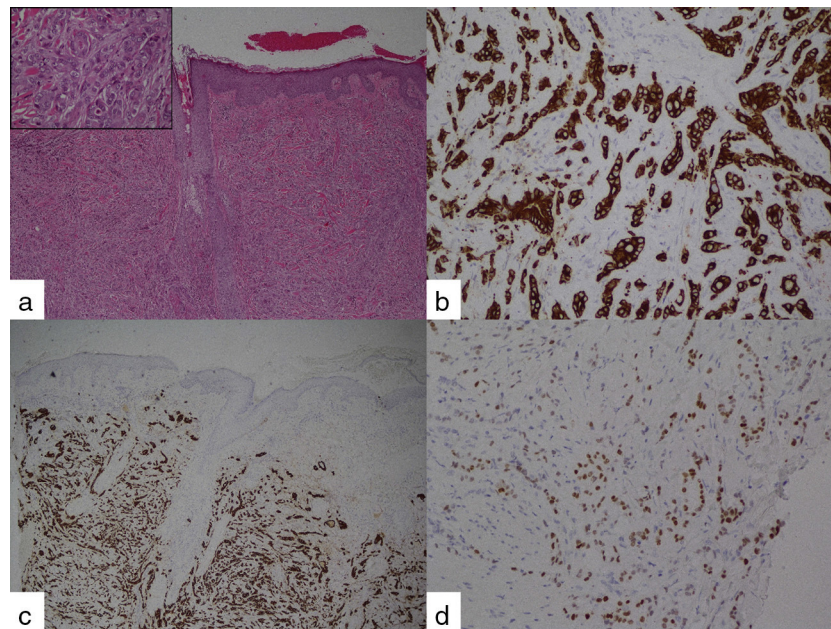


Figure 2 Excisional biopsy of the scalp lesion showing metastatic adenocarcinoma: a) hematoxylin-eosin stain x4, detail: hematoxylin-eosin, x40; b) immunohistochemical stain for CK7; c) immunohistochemical stain for CK19, and d) immunohistochemical stain for CDX2.

cytokeratin 20). The sample of the pancreatic mass confirmed the presence of an adenocarcinoma at that level. The patient was informed of her diagnosis and prognosis and refused any active treatment for her disease. Thus, the biliary obstruction was treated with the endoscopic placement of a biliary stent and she was released with at-home palliative care.

Cutaneous metastases occur in 0.6%–10.4% of all patients with cancer,¹ and is the first disease manifestation in 7.8% of the cases.² When a lesion suspected of being cutaneous metastasis is found, in addition to the pertinent imaging studies, a biopsy of the lesion with immunohistochemical stain can provide orientation as to primary tumor diagnosis. CK 7 and CK 19 are present in the majority of pancreatic adenocarcinomas and CK 20 is negative in 38–80%. Stains positive for CA-19-9 and CEA are also frequent.^{3–6} In our case, immunohistochemical stain was suggestive of a pancreatic origin.

Adenocarcinoma of the pancreas is the fourth cause of cancer-related death and prognosis at its first appearance is normally poor, given that many cases are in advanced stages.⁷ The survival rate of pancreatic adenocarcinoma is especially devastating, with a median survival of approximately 5–6 months. The appearance of cutaneous metastases in this context has a similar impact on survival with respect to other more frequent locations,^{6,8} and it is customary to find other concurrent secondary implants. Therefore, treatment does not vary with this presentation.

Cutaneous metastases are rare and when they occur, they are usually located in the periumbilical zone, producing the lesion known as the “Sister Mary Joseph Nodule”.^{9,10} Outside of this location, metastases are uncommon, and are more frequent in men and in advanced-age patients.⁶

Financial disclosure

No financial support was received in relation to this study/article.

Conflict of interest

The authors declare that there is no conflict of interest.

References

1. Lookingbill DP, Spangler N, Helm KF. Cutaneous metastases in patients with metastatic carcinoma: A retrospective study of 4020 patients. *J Am Acad Dermatol.* 1993;29:228–36.
2. Saeed S, Keehn CA, Morgan MB. Cutaneous metastasis: A clinical, pathological, and immunohistochemical appraisal. *J Cutan Pathol.* 2004;31:419–30.
3. Chu P, Wu E, Weiss LM. Cytokeratin 7 and cytokeratin 20 expression in epithelial neoplasms: a survey of 435 cases. *Mod Pathol.* 2000;13:962–72.
4. Jain R, Fischer S, Serra S, et al. The use of Cytokeratin 19 (CK19) immunohistochemistry in lesions of the pancreas, gastrointestinal tract, and liver. *Appl Immunohistochem Mol Morphol.* 2010;18:9–15.
5. Moll R, Franke WW, Schiller DL, et al. The catalog of human cytokeratins: Patterns of expression in normal epithelia, tumors and cultured cells. *Cell.* 1982;31:11–24.
6. Zhou HY, Wang XB, Gao F, et al. Cutaneous metastasis from pancreatic cancer: A case report and systematic review of the literature. *Oncol Lett.* 2014;8:2654–60.
7. Jemal A, Siegel R, Xu J, et al. Cancer statistics, 2010. *CA Cancer J Clin.* 2010;60:277–300.
8. Horino K, Takamori H, Ikuta Y, et al. Cutaneous metastases secondary to pancreatic cancer. *World J Gastrointest Oncol.* 2012;4:176–80.

9. Gabriele R, Conte M, Egidi F, et al. Umbilical metastases: Current viewpoint. *World J Surg Oncol.* 2005;3:13.
10. Miyahara M, Hamanaka Y, Kawabata A, et al. Cutaneous metastases from pancreatic cancer. *Int J Pancreatol.* 1996;20:127–30.

E. Tavío-Hernández^{a,*}, Á. Cañete-Ruiz^a, C. Moreno^b,
M. Urech^c, A. Cano-Ruiz^a

^a *Departments of Gastroenterology, Hospital Ramón y Cajal, Madrid, Spain*

^b *Pathologic Anatomy, Hospital Ramón y Cajal, Madrid, Spain*

^c *Dermatology, Hospital Ramón y Cajal, Madrid, Spain*

*Corresponding author.

E-mail address: etavio@gmail.com (E. Tavío-Hernández).