

the gastrointestinal tract, enabling endoscopic management with no complications.

References

- Ahmed A, Hassab M, Al-Hussdini A, et al. Magnetic toy ingestion leading to jejunocecal fistula in a child. Case reports. *Saudi Med J*. 2010;31:442–4.
- Gün F, Günendi T, Kilic B, et al. Multiple magnet ingestion resulting in small bowel perforation: A case report. *Ulus Travma Acil Cerrahi Derg*. 2013;19:177–9.
- Bornstein A, Spyker D, Cantinela L, et al. 2011 annual report of the American Association of Poison Control Centers National Poison Data System (NPDS): 29th annual report. *Clin Toxicol*. 2012;50:911–1164.
- Hussain S, Bousvaros A, Gilger M, et al. Management of ingested magnets in children. *J Pediatr Gastroenterol Nutr*. 2012;55:239–42.
- Chevallier M, Barbier C, Jacquier C, et al. Un aimant vaut mieux que deux. *Arch Pediatr*. 2012;19:811–4.
- De Roo AM, Thompson T, Chounthirath H, et al. Rare-earth magnet ingestion-related injuries among children, 2000–2012. *Clin Pediatr (Phila)*. 2013;52:1006–13.
- George A, Motiwale S. Magnets, children and the bowel: A dangerous attraction? *WJG*. 2012;18:5324–8.
- Deveny IA. Hazards of ingested magnets. *JLGH*. 2009;4:90–3.
- Dutta S, Barzin A. Multiple Magnet Ingestion as a source of severe gastrointestinal complications requiring surgical intervention. *Arch Pediatr Adolesc Med*. 2008;162:123–5.
- Tsai J, Shaul D, Sydorak R, et al. Ingestion of magnetic toys: report of serious complications requiring surgical intervention and a proposed management algorithm. *Perm J*. 2013;17:11–20.

J.F. Cadena-León*, M. Cázares-Méndez,
C. Arguello-Bermeo, R. Cervantes Bustamante,
J.A. Ramírez-Mayans

*Departamento de Gastroenterología y Nutrición
Pediátrica, Instituto Nacional de Pediatría, Mexico City,
Mexico*

*Corresponding author: Departamento de Gastroenterología y Nutrición Pediátrica, Servicio de Endoscopia. Instituto Nacional de Pediatría. Insurgentes Sur 3700-C, col. Cuicuilco-Coyoacán, CP 04530, Mexico City. Tel.: +(52)10840900, ext 1288. E-mail address: pcaden60@hotmail.com (J.F. Cadena-León).

Simultaneous volvulus of the ileum and sigmoid colon[☆]



Vólvulo simultáneo de íleon y sigmoides

A 33-year-old woman was admitted to the emergency department due to abdominal pain and distension and a 2-day absence of bowel movement. An abdominal CAT scan was taken, showing the whirl sign, and sigmoid colon volvulus was diagnosed (fig. 1). It was resolved through rectosigmoidoscopy and the patient was released. She returned 3 weeks later due to sudden abdominal pain, distension, fecaloid vomiting, and dehydration of 2-day progression. Physical examination revealed absence of peristalsis, abdominal pain and generalized tympanism, and a positive Blumberg's sign. Her CBC reported leukocytosis of 17,300 and 16% band forms. She did not have any radiography studies. An abdominal ultrasound was given, identifying generalized distension of bowel segments and the presence of free fluid. An exploratory laparotomy was performed, considering a diagnosis of recurrent sigmoid colon volvulus, given her past history. Unexpectedly, simultaneous small bowel and sigmoid colon volvulus was found (fig. 2). The ileum was the affected portion of the small bowel, at approximately 2.7 m, just 5 cm from the ileocecal valve. The latter presented with necrosis due to clock-wise torsion of its mesentery, together with the clock-wise volvulus of the sigmoid colon. The decision was made to perform ileal resection with primary anastomosis and sigmoid colon resection with the Hartmann procedure.

The patient had adequate progression and upon improvement was released from the hospital. Colostomy closure has now been carried out and the patient continues to have adequate progression and is being seen in outpatient follow-up.

This case corresponds to a simultaneous volvulus of the ileum and sigmoid colon, also known as double or compound volvulus.

First described by Parker in 1845,³ it is a rare entity that has been reported in the Middle East, Asia, and Africa more often than in the western medical literature.^{1,2}

Three factors have been related to double volvulus: a long and mobile small bowel mesentery, a redundant sigmoid colon with a short pedicle, and a diet simultaneously high in volume and abundant liquid intake.⁴

In relation to its pathogeny, it is suggested that when the abovementioned diet is ingested, it progresses through segments of the jejunum, making them heavier, and causing their collapse toward the left inferior quadrant, while the empty segments of the ileum and distal jejunum twist clockwise around the narrow base of the sigmoid colon.⁴

Double volvulus is a condition that rapidly progresses to gangrene of both twisted segments and the most common complications are peritonitis, sepsis, and dehydration. The main symptoms include abdominal pain (100%), abdominal distension (94-100%), nausea and vomiting (87-100%), and rebound tenderness (69%).⁴

Preoperative diagnosis of this condition is very difficult and is calculated to exist in only 20% of the cases.⁵ However, there are 3 orienting characteristics: symptoms of small bowel occlusion, an x-ray predominantly showing large bowel obstruction, and the impossibility of inserting a sigmoidoscope.⁴

In addition, the so-called whirl sign can be identified through CAT scan. This sign was described by Fisher as an image produced in the mid-gut when intestinal segments

[☆] Please cite this article as: Rivera-Nava JC. Vólvulo simultáneo de íleon y sigmoides. *Revista de Gastroenterología de México*. 2015;80:115–116.

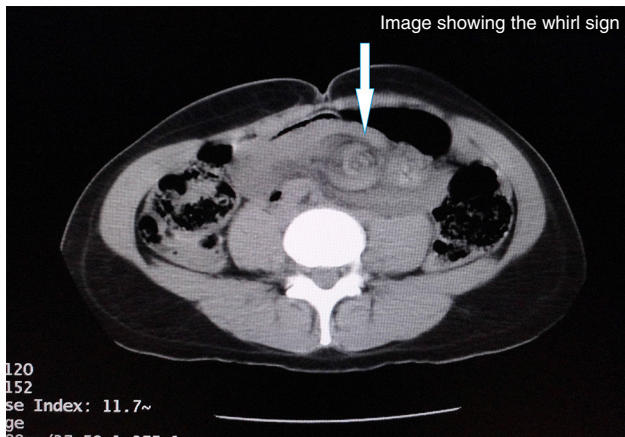


Figure 1 Image showing the whirl sign.

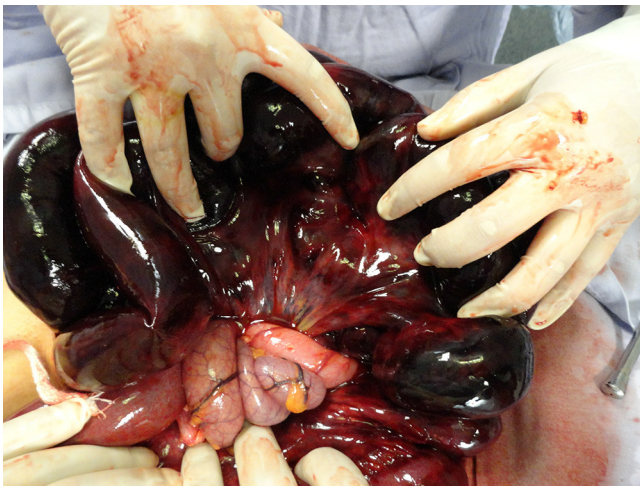

Figure 2 Photograph showing the torsion site of the ileal volvulus.

and their vessels twist around an obstruction point, creating a “swirling” of soft tissue strands within mesenteric fat attenuation.^{6,7} This sign and the medial deviation of the cecum and descending colon are useful in diagnosing double volvulus.⁸

The Alver classification:⁹

Type I (the most common), the ileum (active component) is wrapped around the sigmoid colon (passive component).

Type II, the sigmoid colon (active component) is wrapped around the ileum (passive component).

Type III, the ileocecal segment (active component) is wrapped around the sigmoid colon (passive component).

Types I and II are divided into A and B, depending on whether the active component rotates in a clockwise or counter-clockwise direction.

Intestinal gangrene has been found in 73.5-79.4% of the anatomic and pathologic findings.⁸ Numerous procedures combine the resection of one or both segments with

anastomosis or ileostomy and anastomosis or the Hartmann procedure for the sigmoid colon. The most frequent procedure is ileal resection with primary anastomosis and sigmoid colon resection with the Hartmann procedure. However, ileal anastomosis is not recommended if it is at less than 10 cm from the ileocecal valve.⁸

Double volvulus is a rare entity. Its diagnosis is not simple, requiring a high degree of suspicion, but several guiding aspects have been described. The findings from imaging studies are useful for early diagnosis.

A 15-73% mortality rate has been reported, and septic shock is the main cause. Its reduction is related to the presence of a non-gangrenous colon,¹ and therefore it is imperative that the patient be treated with aggressive fluid resuscitation, antibiotics, and effective surgery that is individualized and directed according to operative findings and the condition of the patient.

Financial disclosure

No financial support was received in relation to this study/article.

Conflict of interest

The authors declare that there is no conflict of interest.

References

- Gingold D, Murrell Z. Management of colonic volvulus. *Clin Colon Rectal Surg.* 2012;25:236-44.
- Roggo A, Ottinger LW. Acute small bowel volvulus in adults. A sporadic form of strangulating intestinal obstruction. *Ann Surg.* 1992;216:135-41.
- Parker E. Case of intestinal obstruction: Sigmoid flexure strangulated by the ileum. *Edinb Med Surg J.* 1845;64:306-8.
- Machado NO. Ileosigmoid knot: A case report and literature review of 280 cases. *Ann Saudi Med.* 2009;29:402-6.
- Chakma SM, Singh RL, Parmekar MV, et al. Ileosigmoid knot—A surgeon's nightmare. *J Clin Diagn Res.* 2013;7:2986-7.
- Khurana B. The whirl sign. *Radiology.* 2003;226:69-77.
- Fisher JK. Computed tomographic diagnosis of volvulus in intestinal malrotation. *Radiology.* 1981;140:145-6.
- Mandal A1, Chandel V, Baig S. Ileosigmoid knot. *Indian J Surg.* 2012;74:136-42.
- Alver O, Oren D, Tireli M, et al. Ileosigmoid knotting in Turkey. Review of 68 cases. *Dis Colon Rectum.* 1993;36:1139-47.

J.C. Rivera-Nava*

Cirugía General, Secretaría de Salud, Hospital General Felipe G. Dobarganes, San Miguel de Allende, Guanajuato, Mexico

* Av. 1.º de mayo N.º 7, Fraccionamiento Ignacio Ramírez, Municipio de San Miguel de Allende, Guanajuato, c.p. 37748. Phone: 415 114 65 61.

E-mail address: riversidercg@hotmail.com