



REVISTA DE
GASTROENTEROLOGÍA
DE MÉXICO

www.elsevier.es/rgmx



CLINICAL IMAGE IN GASTROENTEROLOGY

Pill-induced esophagitis[☆]

Esofagitis por píldoras

R. Soto-Solís*



Servicio de Gastroenterología, Hospital Ángeles Pedregal, Mexico City, Mexico

A 20-year-old woman sprained her ankle and took naproxen and paracetamol for the pain. The following day she presented with dysphagia, thoracic pain, and melena. Panendoscopy identified "mirror-image ulcers" in the distal esophagus (figs. 1 and 2).

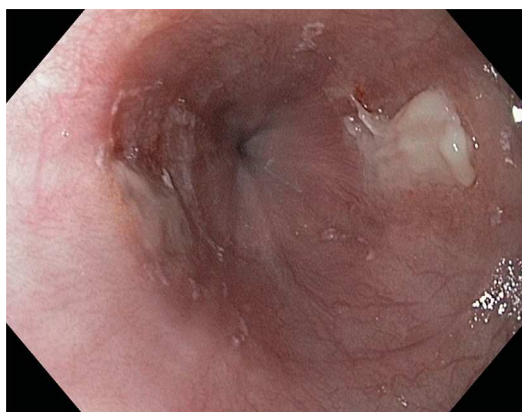


Figure 1 High-definition white-light esophagoscopy showing 2 ulcers in the distal third of the esophagus, one in front of the other in a "mirror image".

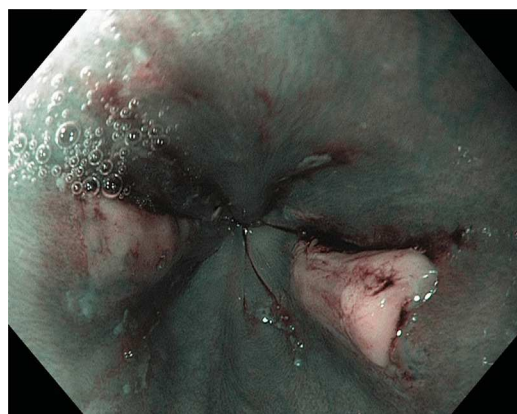

Figure 2 Mirror-image ulcers in the distal third of the esophagus seen through narrow band imaging (NBI), highlighting the vascular patterns and areas of bleeding.

Financial disclosure

No financial support was received in relation to this article.

Conflict of interest

The author declares that there is no conflict of interest.

[☆] Please cite this article as: Soto-Solís R. Esofagitis por píldoras. Revista de Gastroenterología de México. 2015;80:160.

* Corresponding author: Camino a Santa Teresa 1055-650, Col. Héroes de Padierna, Del. Magdalena Contreras, CP 10700, México D.F. Phone: +51355982.

E-mail address: rodrigosotomd@hotmail.com

URL: <http://www.hospitalvirtualmx.com>.