



## SCIENTIFIC LETTERS

### Endoscopic gastric submucosal dissection in low-grade intraepithelial neoplasia<sup>☆</sup>



### Disección endoscópica de la submucosa gástrica en neoplasia intraepitelial de bajo grado

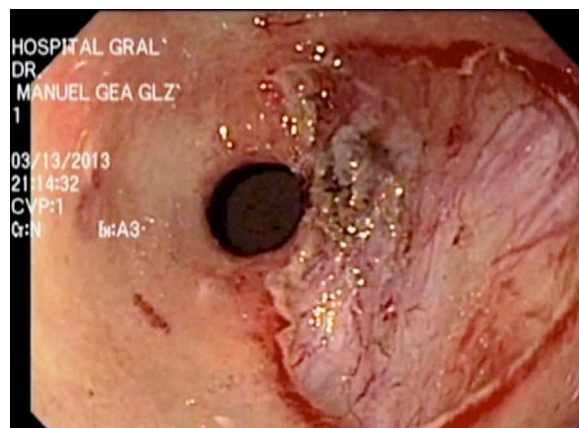
Endoscopic mucosal resection (EMR) was developed for the purpose of preserving complete gastrointestinal function after the resection of a lesion limited to the mucosa of the digestive tract, as well as for obtaining larger specimens that would enable a precise histopathologic diagnosis.<sup>1</sup>

In Japan, different techniques were developed for EMR that were divided into three modalities: EMR with a double-channel endoscope, aspiration EMR, and endoscopic submucosal dissection (ESD).<sup>2</sup>

EMR is typically used for removing lesions smaller than 2 cm or removal by sections in large lesions. ESD was developed for *en bloc* resection (EBR), regardless of the size of the lesion.<sup>3</sup>

There are important ethical considerations in the formation process of this new technique. Up to the present, the results have been promising. Nevertheless, the lack of training centers, together with potential complications (perforation, bleeding), has limited the expansion of its use in Mexico.

The basic requirements suggested for surgeons and gastroenterologists that wish to perform this technique are: a) certification in gastrointestinal endoscopy, b) training in the use of the devices, techniques, and technologies for identifying and treating premalignant conditions and incipient cancer in the esophagus, stomach, small bowel, and colon, c) experience in hemostasis, and d) training in ESD. A proposed training model encompasses: a first phase in which the procedure performed by qualified specialists is observed; a second phase of practice using inanimate and animate models; a third phase of training in humans under the



**Figure 1** Endoscopic submucosal dissection. Complete lesion resection.

supervision of qualified specialists; and finally, performing the procedure in humans.<sup>4</sup>

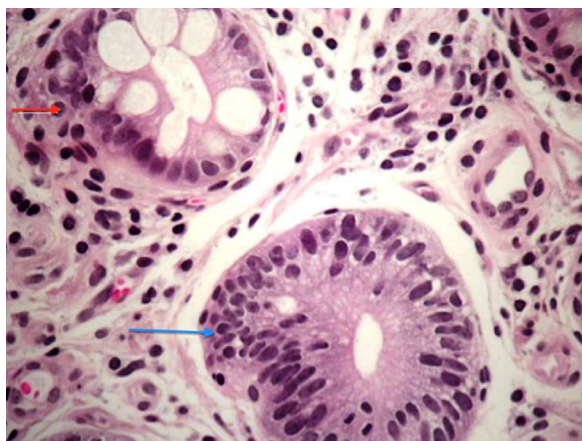The aim of this letter was to present the case of a patient with a histologic diagnosis of low-grade intraepithelial gastric neoplasia (low-grade dysplasia) and to provide a literature-based analysis of the role of endoscopic resection in this premalignant condition.

An 81-year-old woman sought medical attention complaining of weight loss of 10 kg in 3 months. As part of her evaluation protocol an abdominal computerized axial tomography scan with double contrast was taken that reported probable thickening of the esophageal mucosa (0.8 mm). Upper gastrointestinal endoscopy was performed, identifying erosive gastropathy in the fundus and a slightly elevated non-polypoid superficial prepyloric lesion (Paris Classification 0-IIa) that measured 2 cm in diameter. Digital chromoendoscopy showed follicular changes in the mucosa with no vascular irregularities.

The histopathologic report of the biopsies described low-grade intraepithelial neoplasia / dysplasia (World Health Organization Classification) in the antral mucosa (Fig. 1) and mild focal atrophy that was negative for *Helicobacter pylori*. Preoperative laboratory study results were within normal parameters.

For the purpose of obtaining a precise histologic diagnosis of a well-defined lesion, 2 endoscopists skilled in the ESD technique (MR and JH) performed the procedure after receiving the informed consent of the patient.

<sup>☆</sup> Please cite this article as: Quiroz-Guadarrama CD, Herrera-Esquível JJ, Rojano-Rodríguez M, Del Río-Suárez I, Morales-Vargas JM, Mucio M. Disección endoscópica de la submucosa gástrica en neoplasia intraepitelial de bajo grado. Revista de Gastroenterología de México. 2014;79:149–151.



**Figure 2** Blue arrow: Low-grade gastric mucosal dysplasia. Loss of polarity of the basal nuclei showing a pseudostratified pattern with nuclear pleomorphism and hyperchromasia (hematoxylin and eosin stain) Red arrow: Gastric gland. Intestinal metaplasia.

An Olympus GIF-180 gastroscope was employed. Indigo carmine at 5% was applied to define the margins of the lesion by contrast. An endoscopic Flex Knife® was used to mark the circumference of the lesion with monopolar energy (cut 70/coagulation 30); the submucosa was infiltrated with 3 cc of saline solution at 0.9% and 1.5 cc of hyaluronic acid using an injector (Olympus NM-200U0423). The circumferential cut of the lesion was made with the endoscopic Flex Knife and the submucosa was dissected with the IT Knife2®, until the lesion was completely resected (Fig. 2).

Hemostasis was verified and the operative field was irrigated with saline solution after resection. Surgery duration was 65 minutes and there were no complications. The previous diagnosis was confirmed by histopathology.

Intraepithelial neoplasia of the gastric mucosa is the penultimate stage of carcinogenesis. It is defined as a non-invasive gastric neoplasia, characterized by cellular atypia and by abnormal differentiation and disorganization of the glandular architecture.<sup>5</sup>

The correct diagnosis and grade classification of intraepithelial neoplasia is crucial because it predicts the risk for malignant transformation. You et al. conducted a prospective study on 546 patients with dysplasia during the 5-year follow-up and found that gastric cancer progression was 0.6% per year for low-grade dysplasia and 1.4% for high-grade dysplasia.<sup>6</sup>

De Vries et al. included 7,616 patients with low-grade dysplasia and 562 with high-grade dysplasia during a 5-year follow-up. The annual incidence of gastric cancer was 0.6% for low-grade dysplasia and 6% for high-grade dysplasia.<sup>7</sup>

The European Society of Gastrointestinal Endoscopy (ESGE) recommends endoscopic resection for the purpose of obtaining a precise histologic diagnosis in patients presenting with low-grade dysplasia in whom a well defined lesion has been identified during the endoscopy.<sup>8</sup> Kim et al. evaluated the discrepancy in the diagnosis of low-grade dysplastic lesions obtained with biopsy forceps or EMR in 273 patients and found histologic concordance in 73%; 19% of the

cases presented with higher-grade dysplastic lesions, and even adenocarcinoma, after resection.<sup>9</sup>

In a case series of 41 patients, Hull et al. found discordance in 39% of the cases regarding diagnoses obtained with biopsy forceps and EMR. The authors concluded that EMR was superior in diagnosing superficial lesions, particularly those that are larger than 10 mm.<sup>10</sup>

Further studies are needed that evaluate the risk / benefit of endoscopic resection of the gastric mucosa in patients diagnosed with low-grade intraepithelial neoplasia.

## Financial disclosure

No financial support was received in relation to this article.

## Conflict of interest

The authors declare that there is no conflict of interest.

## References

1. Gotoda T. Endoscopic resection of early gastric cancer. *Gastric Cancer*. 2007;10:1–11.
2. Jee YS, Hwang SH, Rao J. Safety of extended endoscopic mucosal resection and endoscopic submucosal dissection following the Japanese Gastric Cancer Association treatment guidelines. *Br J Surg*. 2009;96:1157–61.
3. Tanaka M, Ono H, Hasuike N, Takizawa K. Endoscopic submucosal dissection of early gastric cancer. *Digestion*. 2008;77:23–8.
4. Yamamoto S, Uedo N, Ishihara R, Kajimoto N, Ogiyama H, Fukushima Y, et al. Endoscopic submucosal dissection for early gastric cancer performed by supervised residents: assessment of feasibility and learning curve. *Endoscopy*. 2009;41:923–8.
5. Nokada K, Kita H. Endoscopic submucosal dissection for early gastric cancer. *Journal of Cancer Therapy*. 2013;4:26–32.
6. You WC, Li JY, Blot WJ. Evolution of precancerous lesions in a rural Chinese population at high risk of gastric cancer. *Int J Cancer*. 1999;83:615–9.
7. de Vries AC, VanGrieken NC, Looman C. Gastric cancer risk in patients with premalignant gastric lesions: a nationwide cohort study in the Netherlands. *Gastroenterology*. 2008;134:945–52.
8. Dinis-Ribeiro M, Areia M, de Vries AC, Marcos-Pinto R, Monteiro-Soares M, O'Connor A, et al. Management of precancerous conditions and lesions in the stomach. *Endoscopy*. 2012;44:74–94.
9. Kim YJ, Park JC, Kim JH. Histologic diagnosis based on forceps biopsy is not adequate for determining endoscopic treatment of gastric adenomatous lesions. *Endoscopy*. 2010;42:620–6.
10. Hull MJ, MIMO-Kenudson M, Nishioka NS, Ban S, Sepehr A, Puricelli W, et al. Endoscopic mucosal resection: an improved diagnostic procedure for early gastroesophageal epithelial neoplasms. *Am J Surg Pathol*. 2006;30:114–8.

C.D. Quiroz-Guadarrama<sup>a,\*</sup>, J.J. Herrera-Esquivel<sup>b</sup>, M. Rojano-Rodríguez<sup>c</sup>, I. Del Rio-Suarez<sup>d</sup>, J.M. Morales-Vargas<sup>e</sup>, M. Mucio<sup>f</sup>

<sup>a</sup> Médico Adscrito Cirugía Endoscópica. Hospital General Dr. Manuel Gea González, S.S.A. México, D.F

<sup>b</sup> Jefe de la División de Atención médica. Hospital General Dr. Manuel Gea González, S.S.A. México, D.F

<sup>c</sup> Jefe del Servicio de Endoscopia Digestiva. Hospital General Dr. Manuel Gea González, S.S.A. México, D.F

<sup>d</sup> Residente Motilidad Gastrointestinal. Hospital General Dr. Manuel Gea González, S.S.A. México, D.F

<sup>e</sup> Residente Endoscopia Digestiva. Hospital General Dr. Manuel Gea González, S.S.A. México, D.F

<sup>f</sup> Director General. Hospital General Dr. Manuel Gea González

\* Corresponding author.

E-mail addresses: [radheyadqg@hotmail.com](mailto:radheyadqg@hotmail.com), [radheyadqg@gmail.com](mailto:radheyadqg@gmail.com) (C.D. Quiroz-Guadarrama).

## An infrequent cause of iron-deficiency anemia: Blue rubber bleb nevus syndrome<sup>☆</sup>



### Una causa infrecuente de anemia ferropénica: blue rubber bleb nevus syndrome

Iron-deficiency anemia can be caused by occult bleeding of the digestive tract secondary to diverse lesions of different prevalence and severity.<sup>1</sup> Among them are those of vascular origin, such as blue rubber bleb nevus syndrome (BRBNS), also known as Bean syndrome, initially described by Gascoyen in 1860. In 1958 Bean associated the lesions of the skin with those of the gastrointestinal tract, and since then the syndrome bears his name.<sup>2</sup>

A 45-year-old woman was referred to our hospital center to study her iron-deficiency anemia. Her personal and family medical histories were unremarkable. Hematocrit was 27%, hemoglobin 9.0 g/dl, white blood cell count 7,500/mm<sup>3</sup>, serum iron 60 µg/dl, coagulogram was normal, and serology for celiac disease was negative. The medical history was taken and the patient did not complain of symptoms or findings that could be linked to anemia or gastrointestinal bleeding. The physical examination revealed the presence of vascular lesions on the feet and abdomen (Fig. 1).

The lesions were round, bluish, rubbery, and nonpainful and had a diameter that varied from 1 to 3 cm. One of the lesions deformed a foot. Upper and lower gastrointestinal video endoscopy was performed, displaying a lesion on the anterior surface of the pyloric antrum that measured 2 cm in diameter; it was bluish and rounded and had a soft consistency (Fig. 2A).

Three similar lesions were observed on the colon (Fig. 2B). There were no signs of bleeding and the abdominal ultrasound was normal. Given the cutaneous and gastrointestinal lesions, BRBNS was diagnosed and it was assumed to be responsible for the anemia, once urologic and gynecologic bleeding was ruled out. The patient agreed with the recommendation not to evaluate the small bowel, given that she did not present with symptoms. Oral iron replacement was begun and her anemia was corrected. The patient is presently in stable condition.

<sup>☆</sup> Please cite this article as: Wonaga A, Fernández JL, Barsanti A, Viola LA. Una causa infrecuente de anemia ferropénica: blue rubber bleb nevus syndrome. *Revista de Gastroenterología de México*. 2014;79:151–152.

BRBNS is a rare syndrome that combines the presence of cutaneous and visceral venous malformations that are typically small, circumscribed, and multifocal. Even though the disease appears sporadically in the majority of reported cases, some have a dominant autosomal component related to a mutation of chromosome 9p.<sup>3</sup> The epidemiology and natural history of BRBNS is not well known. Due to its rareness, emphasized by all authors, there are no figures related to prevalence, the incidence of bleeding, or mortality. There are thought to be about 150 communicated cases worldwide.<sup>4</sup> The digestive tract is frequently compromised by multiple papilliform bluish lesions. The small bowel is the most common location, followed by the colon, but there can also be lesions at the mouth of the anus.<sup>3</sup> In general, they are present from birth and their appearance in adulthood is less likely.<sup>2,3</sup> The majority of the cases manifest as occult bleeding. In the largest case series to date, Fishman et al. conducted their study on 32 patients from a referral center; 22 of them presented with minimal bleeding and 10 had severe bleeding.<sup>2</sup> Rare complications such as intussusception, volvulus, infarct, and obstruction have been reported.<sup>5</sup> The cutaneous lesions are generally small, measuring less than 2 cm; their color ranges from blue to purple and they rarely bleed spontaneously. Other uncommon locations are: the brain, eyes, oral cavity, thyroid, lungs, pericardium, pleura, spleen, liver, kidneys, bladder, and muscle and skeletal system.<sup>4,6</sup> The extradigestive and extracutaneous lesions can produce epistaxis, hemoptysis,

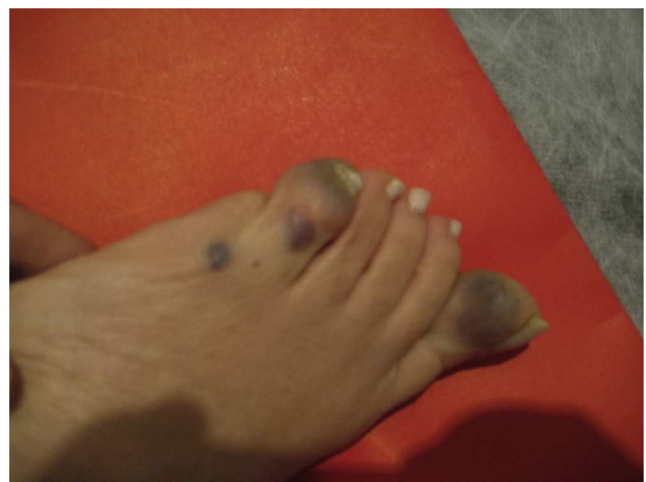


Figure 1 Rounded bluish lesions deforming a foot.